

# Isolated Congenital Incus Anomaly: Report of a Case

Fuh-Cherng Jeng, Cheng-Feng Yao, Ming-Hsui Tsai

Department of Otolaryngology, China Medical College Hospital, Taichung, Taiwan, R.O.C.

Congenital ossicular anomalies are often encountered in patients with congenital aural atresia and less frequently in patients with normal external ears. The most common site of isolated congenital ossicular anomalies is the stapes. Isolated congenital incus anomalies are rare. In June 2000, a thirteen-year-old girl visited our department complaining of hearing loss in the right ear since childhood. The external ears were normal. The pure tone audiometry showed 42 dB hearing loss with a 33 dB air-bone gap in the right ear. As the tympanic membrane was elevated during exploratory tympanotomy, the incus was found to be anomalous and resembled a small bar with one end attached to the head of the stapes while the other end was free. Both the malleus and the stapes were normal and mobile. We placed a piece of partial ossicular replacement prosthesis (Xomed 11-56362) onto the head of the stapes. We also inserted a piece of tragal cartilage between the eardrum and the prosthesis in order to prevent early protrusion of the prosthesis. The postoperative hearing gain was 15 dB, and there has been no evidence of hearing deterioration over the last 12 months of follow-up. (*Mid Taiwan J Med* 2001;6:244-8)

## Key words

conductive hearing loss, congenital ossicular anomaly, exploratory tympanotomy, ossiculoplasty

## INTRODUCTION

The overall incidence of congenital anomalies of the ear is 1 per 15,000 [1]. The incidence rate is even less common for congenital middle ear anomalies [2]. Congenital ossicular anomalies are often encountered in patients with congenital external ear anomalies, such as congenital aural atresia [2-5]. There are several types of isolated congenital ossicular anomalies [2-3], and the stapes is the most common site [1,2,6,7]. Isolated congenital incus anomalies in patients with normal malleus, stapes, middle ears, tympanic membranes and external ears are rare.

In this report, we present the clinical appearance, operative findings and surgical results of a rare case of isolated congenital

incus anomaly. We also reviewed the related literature and discussed associated anomalies.

## CASE REPORT

In June 2000, we examined a thirteen-year-old girl complaining of hearing loss in the right ear since childhood. No vertigo or tinnitus was reported. She had no history of otorrhea, trauma or surgery. The auricle appeared normal with clear landmarks in each ear. The otoscopic examination revealed a normal external auditory canal and tympanic membrane in each ear, no evidence of otitis media, middle ear effusion, eardrum retraction or granuloma. Pure tone audiometry revealed 42 dB hearing loss with a 33 dB air-bone gap in the right ear and normal hearing in the left ear. The degree of hearing loss was based on the pure tone average at 500, 1000 and 2000 Hz. Tympanometry showed type A in each ear. There was no response to the stapedia reflex test at 500, 1000, 2000 and 4000 Hz in the

Received : July 6, 2001.

Revised : August 24, 2001.

Accepted : September 12, 2001.

Address reprint requests to : Fuh-Cherng Jeng, Department of Otolaryngology, China Medical College Hospital, No 2, Yuh-Der Road, Taichung 404, Taiwan, R.O.C.




Fig. 1 The anomalous incus bar, about 3 mm long, was examined under a microscope with a micro-ruler. The notch of the incus, which was originally connected to the head of the stapes, is identified with an arrow. The remaining area of the incus was covered with healthy mucosa with no evidence of inflammation.

right ear. The left ear responded to 95 dB at 500, 1000, 2000 Hz, but not at 4000 Hz. Mastoid plain film displayed normal landmarks of the temporal bone and adequate pneumatization in each ear.

Under the impression of ossicular anomaly in the right ear, exploratory tympanotomy was performed with general anesthesia. After elevation of the tympanic membrane, an anomalous incus which resembled a small bar was seen (Fig. 1). One end was attached to the head of the stapes and the other end was free. The incudo-stapedial joint was separated and the anomalous incus was removed from the head of the stapes. The anomalous incus bar was about 3 mm long and was covered with an intact lining of mucosa. There was no evidence of inflammation or erosion. Both the malleus and the stapes were normal and mobile. The middle ear mucosa was healthy. With the aid of a micro-mirror, no pus, granulation or cholesteatoma was found in the attic area or in the dead ends of the middle ear. The bony canal of the facial nerve was not dehiscent and did not protrude into the tympanic portion of the ear. The ossiculoplasty was accomplished by placing a piece of partial ossicular replacement prosthesis (Xomed 11-56362), 3.5 mm long, on the head of the stapes (Fig. 2). A piece of

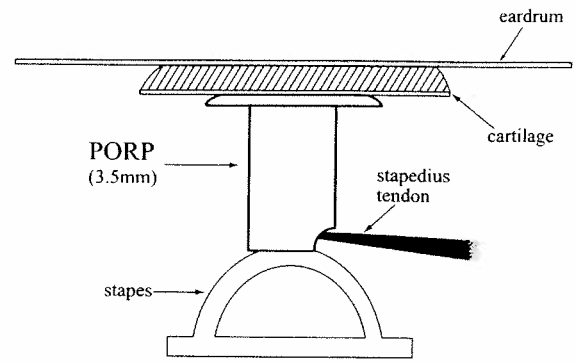


Fig. 2 The partial ossicular replacement prosthesis (Xomed 11-56362), 3.5 mm long, was placed on the head of stapes for ossiculoplasty. A notch at the bottom of the prosthesis was made in order to fit the stapedius tendon. A piece of tragal cartilage was inserted between the eardrum and the prosthesis to prevent early protrusion of the prosthesis.

tragal cartilage was inserted between the eardrum and the prosthesis in order to prevent early protrusion. No vertigo, tinnitus or facial paralysis was noted after surgery.

The patient was discharged on the fourth day. Six months after surgery, pure tone audiometry showed 22 dB hearing loss with an 18 dB air-bone gap in the right ear. The hearing gain after this operation was 15 dB, and there has been no evidence of hearing deterioration over 12 months of follow-up.

## DISCUSSION

The majority of isolated ear malformations are considered sporadic forms of the first and second brachial arch syndromes [1]. According to the literature, congenital ossicular anomalies are often encountered in patients with congenital aural atresia and less frequently in patients with normal external ears [2-5]. There are several types of isolated congenital ossicular anomalies: 1) malleus head fixation, 2) absence or hypoplasia of the incus, 3) incus fixation, 4) incus-stapes misarticulation, 5) stapes hypoplasia, 6) stapes hyperplasia, 7) columellar stapes, 8) stapes superstructure fixation, and 9) stapes footplate fixation [2-4,8]. At 16 weeks of embryological development, the ossicles are fully formed [1]. The stapes has the lengthiest embryology of the three

ossicles, and is also the most common site of lesion in isolated congenital ossicular anomalies [1,2,6]. Isolated congenital incus anomalies are rare.

Congenital ossicular anomalies may be seen as isolated entities or as part of inherited syndromes with other anomalies [2]. Although hearing loss is usually a solitary anomaly without any recognizable hereditary components, it is not unusual for conductive hearing loss to form part of a syndrome or have a hereditary origin [1,2,4,6-10].

We should consider the possibility of otosclerosis and congenital ossicular anomalies in patients who have conductive hearing loss, yet normal external ears, normal tympanic membranes, and no history of otorrhea, trauma or surgery to their ears [11].

Congenital ossicular anomalies can produce similar moderate-to-severe conductive hearing loss. They can occur unilaterally or bilaterally and in combination with one another [2]. The degree of conductive hearing loss depends on the pattern and severity of ossicular anomalies. Moderate conductive hearing loss in this case was probably due to the occasional contact of the malleus and the anomalous incus when an acoustic energy traveled through the original disconnected ossicles.

For patients who have bilateral conductive hearing loss due to ossicular abnormalities, most authors recommend waiting to perform surgery until patients are at least 5 years of age or older for several reasons. First, audiological tests are more performable and reliable. Second, patients who are 5 years or older cooperate better during preoperative examination and postoperative treatment. Finally, older children are less susceptible to infections [2,12,13].

The necessity of surgical intervention for patients with unilateral conductive hearing loss remains controversial [2]. Some authors believe that no therapy is required [14]. Others advocate that surgery should be postponed until patients can make decisions on their own [15].

Audiological tests provide information about the type of anomaly and assist in making the decision for surgery. Usually we do not advise patients with mild conductive hearing loss to have an exploratory tympanotomy. However, we advised this patient to undergo the procedure because her pure tone audiometry showed 42 dB hearing loss with a 33 dB air-bone gap in the right ear. Tympanometry may have different patterns for different middle ear conditions [16]. Although tympanometry is helpful for differentiating ossicular fixation from ossicular discontinuity [2], tympanometry type A does not necessarily exclude the possibility of ossicular anomalies [17]. In this patient, occasional contacts of the malleus and the anomalous incus may have increased the acoustic impedance resulting in type A tympanometry, rather than type Ad. A stapedial reflex test may help distinguish ossicular abnormalities from other disorders. In this patient, no response to the stapedial reflex test was compatible with isolated congenital incus anomaly.

Although history, physical examination and audiological tests may provide useful information, it remains difficult to know the exact condition of the middle ear and ossicles until an exploratory tympanotomy is performed [11]. Ossicular reconstructions are highly dependent on the type and severity of ossicular abnormalities. As a result, surgeons usually cannot decide which way to reconstruct the ossicles until the middle ear and ossicular conditions are fully examined. [4]. Regular postoperative follow-up is also recommended.

#### REFERENCES

1. Nomura Y, Nagao Y, Fukaya T. Anomalies of the middle ear. *Laryngoscope* 1988;98:390-3.
2. De la Cruz A, Doyle KJ. Ossiculoplasty in congenital hearing loss. [Review] *Otolaryngol Clin North Am* 1994;27:799-811.
3. Teunissen E, Cremers CW. Surgery for congenital anomalies of the middle ear with mobile stapes. *Eur Arch Otorhinolaryngol* 1993;250:327-31.
4. Henner R, Buckingham RA. The recognition and

- surgical treatment of congenital ossicular defects. *Laryngoscope* 1956;66:526-39.
5. Proops DW. Surgery of congenital abnormalities of the external and middle ears. In: Kerr AG, Scott-Brown's Otolaryngology. London: Butterworths Co, 1997;9/1-14.
  6. Teunissen B, Cremers CW. Surgery for congenital stapes ankylosis with an associated congenital ossicular chain anomaly. [Review] *Int J Pediatr Otorhinolaryngol* 1991;21:217-26.
  7. Teunissen EB, Cremers WR. Classification of congenital middle ear anomalies. Report of 144 ears. *Ann Otol Rhinol Laryngol* 1993;102:606-12.
  8. Jahrsdoerfer R. Congenital malformation of the ear. Analysis of 94 operations. *Ann Otol Rhinol Laryngol* 1980;89:348-52.
  9. Cousins VC, Milton CM. Congenital ossicular abnormalities: a review of 68 cases. *Am J Otol* 1988;9:76-80.
  10. House JW, Sheehy JL, Antunez JC. Stapedectomy in children. *Laryngoscope* 1980;90:1804-9.
  11. Wilmot TJ. Hereditary conductive deafness due to incus-stapes abnormalities and associated with pinna deformity. *J Laryngol Otol* 1970;84:469-79.
  12. Huang TC, Hung CM, Wang PC, et al. Congenital ossicular anomalies in patients with a normal external ear. *J Taiwan Otolaryngol Head Neck Surg* 1999;34:389-93.
  13. Lambert PR. Major congenital ear malformations: surgical management and results. *Ann Otol Rhinol Laryngol* 1988;97:641-9.
  14. Liang JF, Chen CS, Lien CF, et al. Congenital ossicular anomaly. *J Taiwan Otolaryngol Head Neck Surg* 1988;24:19-22.
  15. Chiossone E. Surgical management of major congenital malformations of the ear. *Am J Otol* 1985;6:237-42.
  16. Bellucci RJ. Congenital aural malformations: diagnosis and treatment. *Otolaryngol Clin North Am* 1981;14:95-124.
  17. Isenberg SF, Tubergen LB. An unusual congenital middle ear ossicular anomaly. *Arch Otolaryngol* 1980;106:179-81.