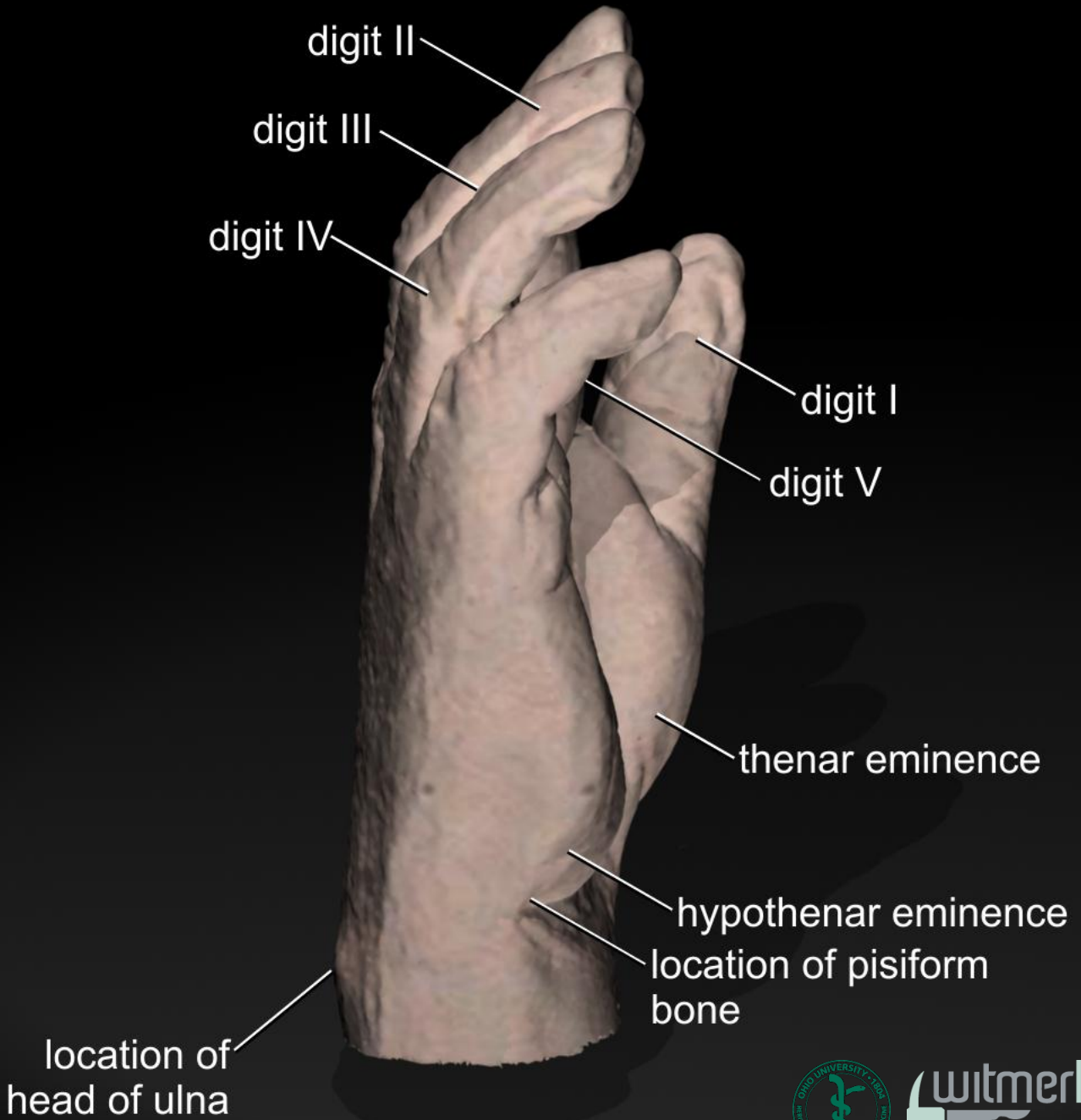
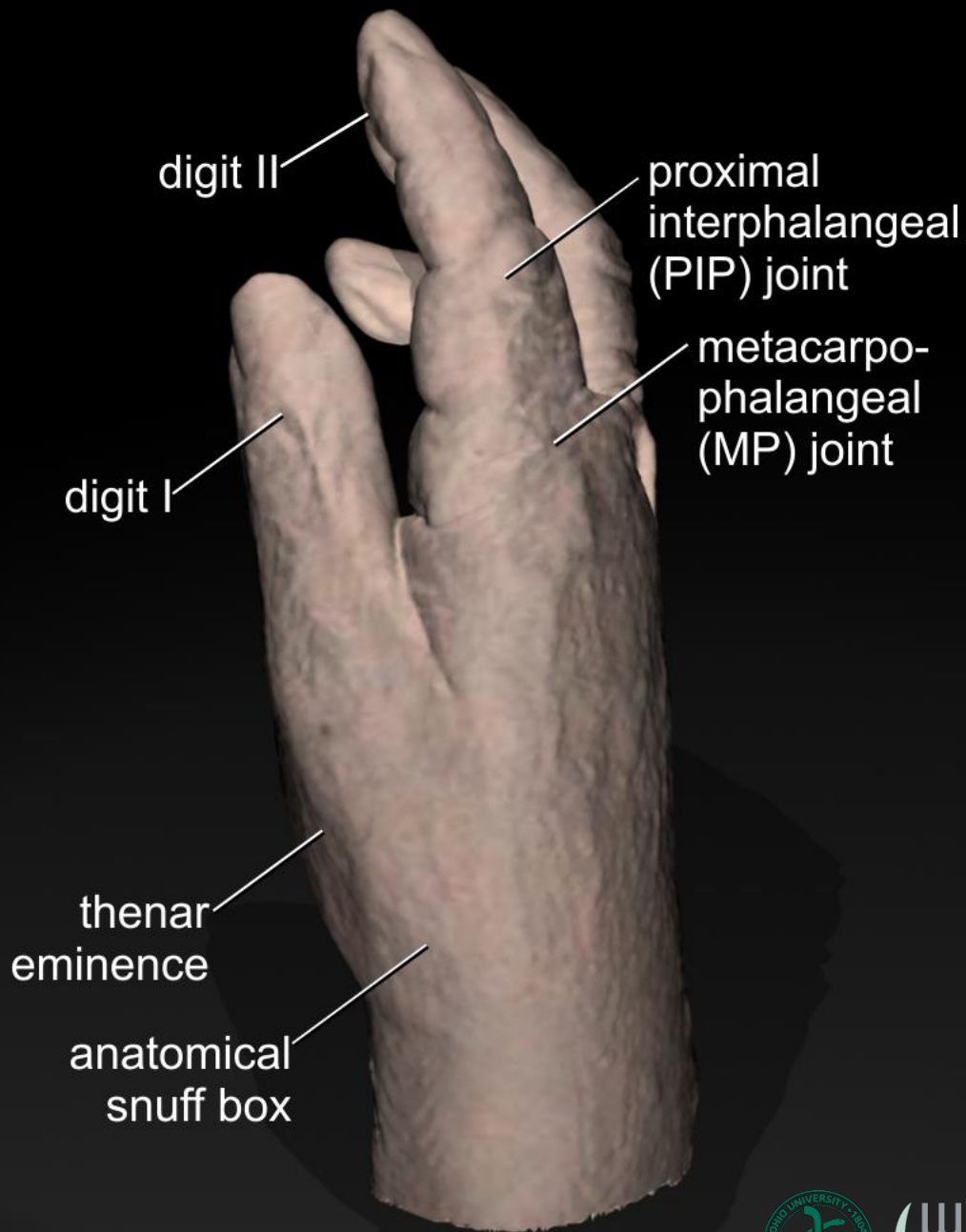
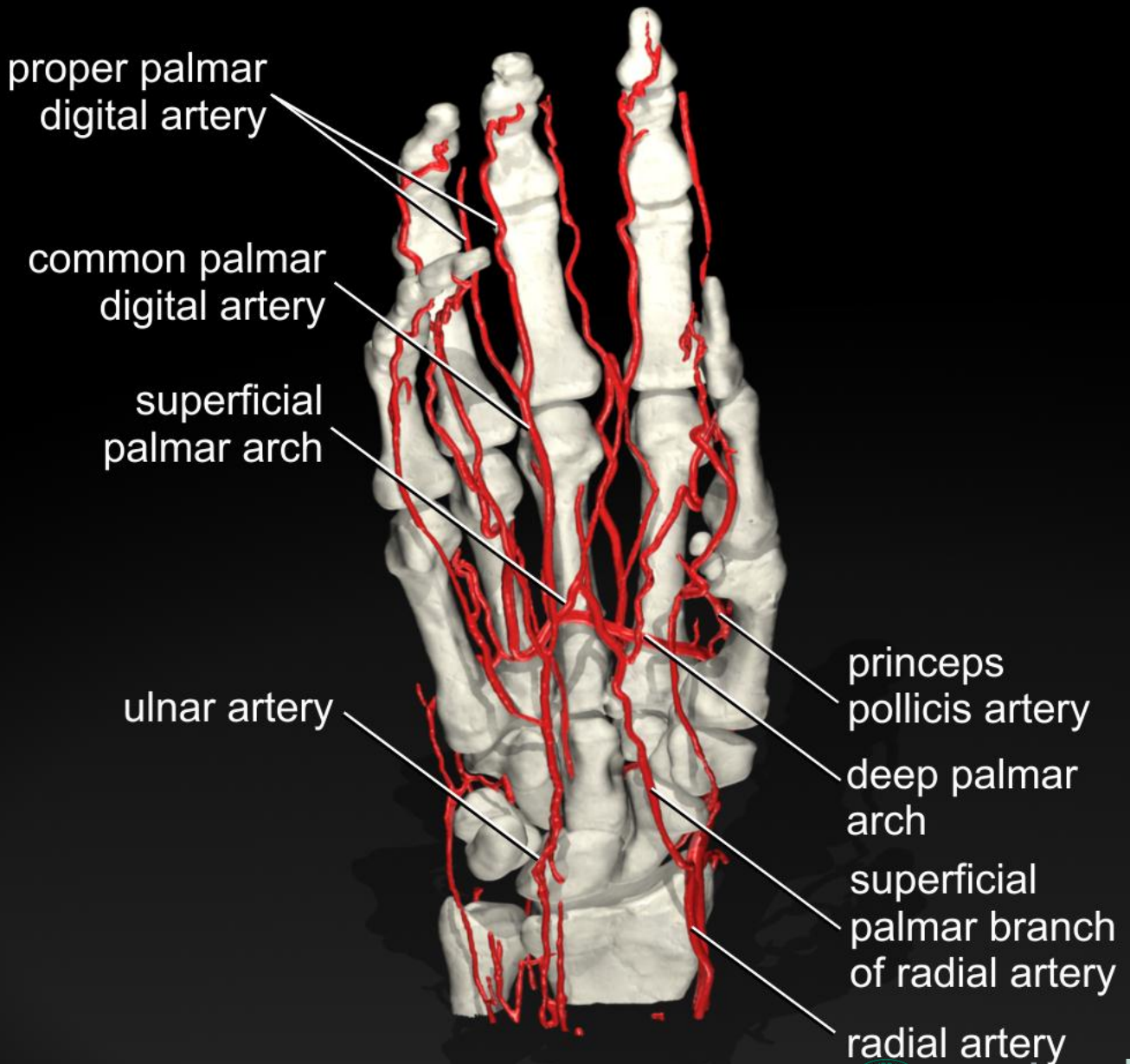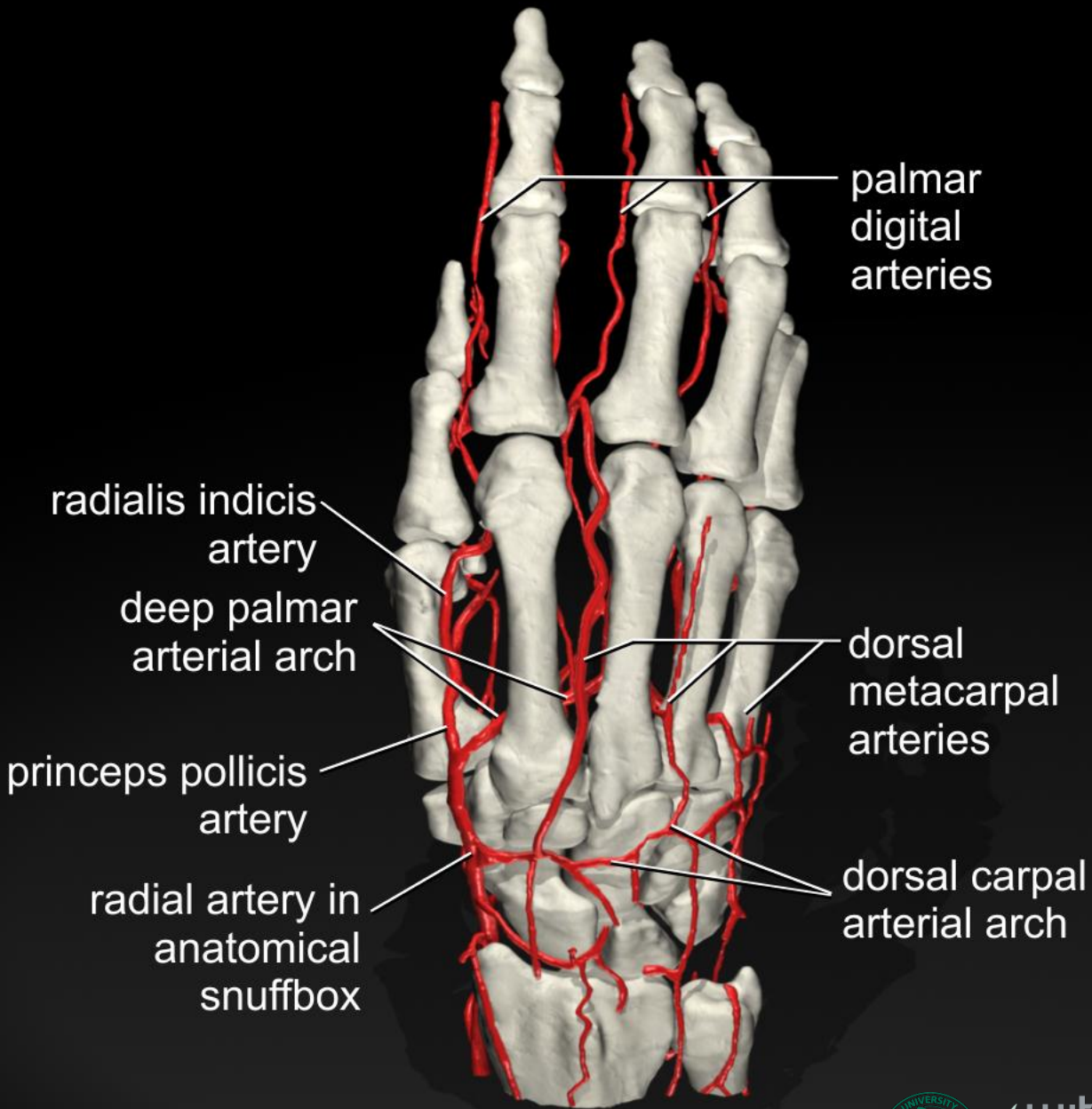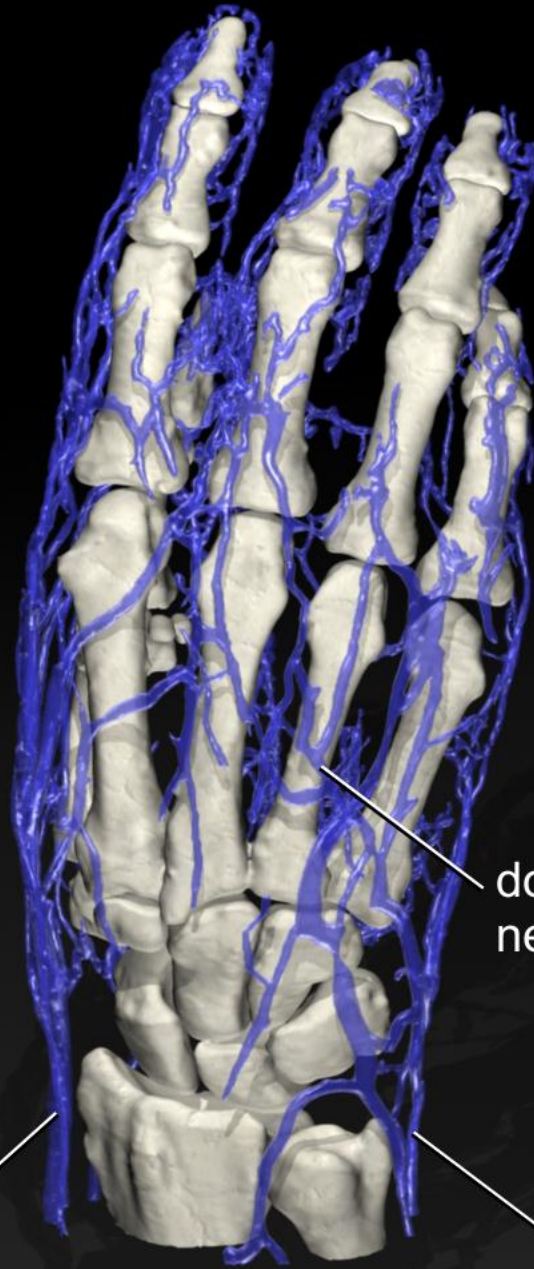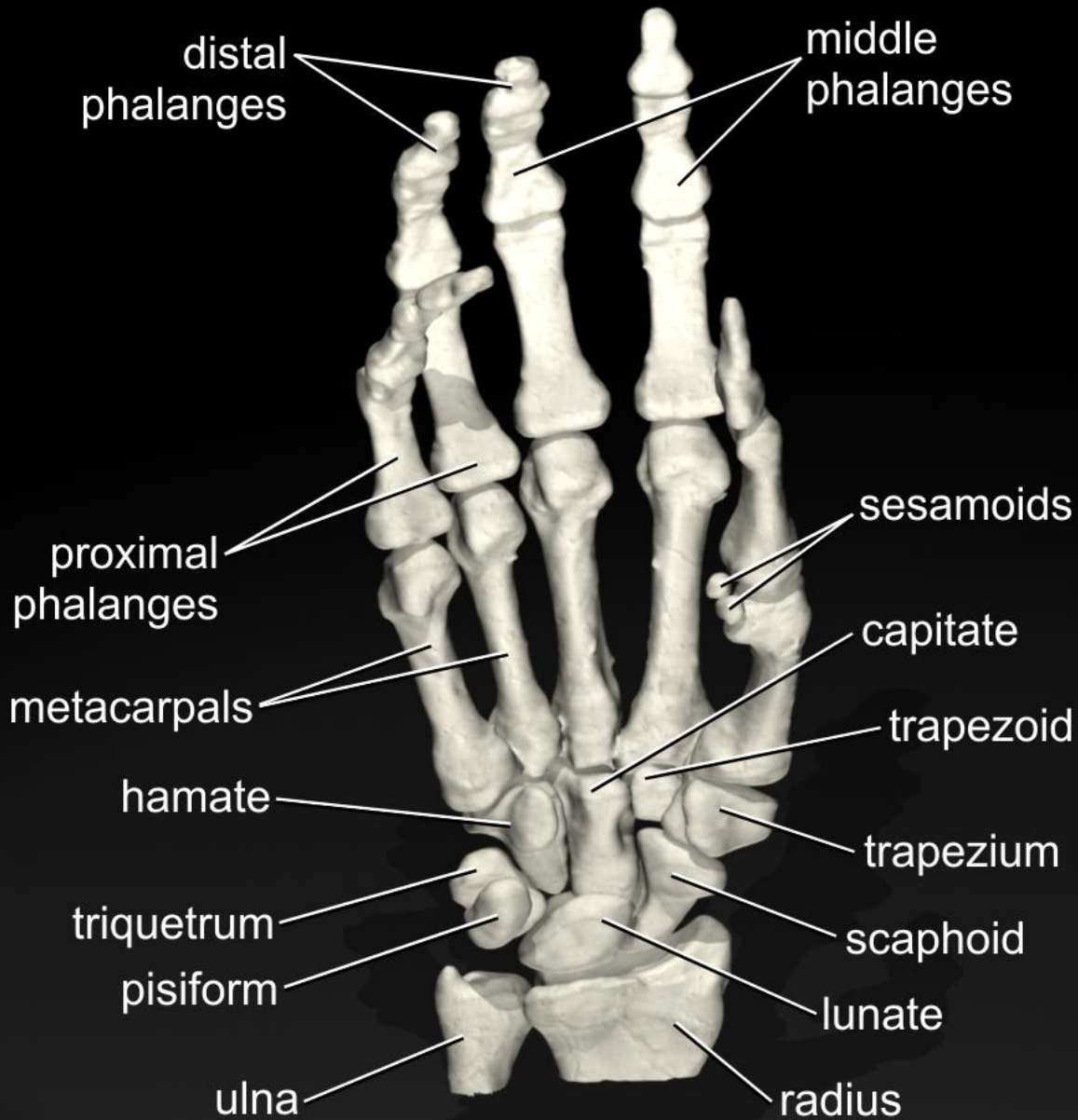
cephalic vein

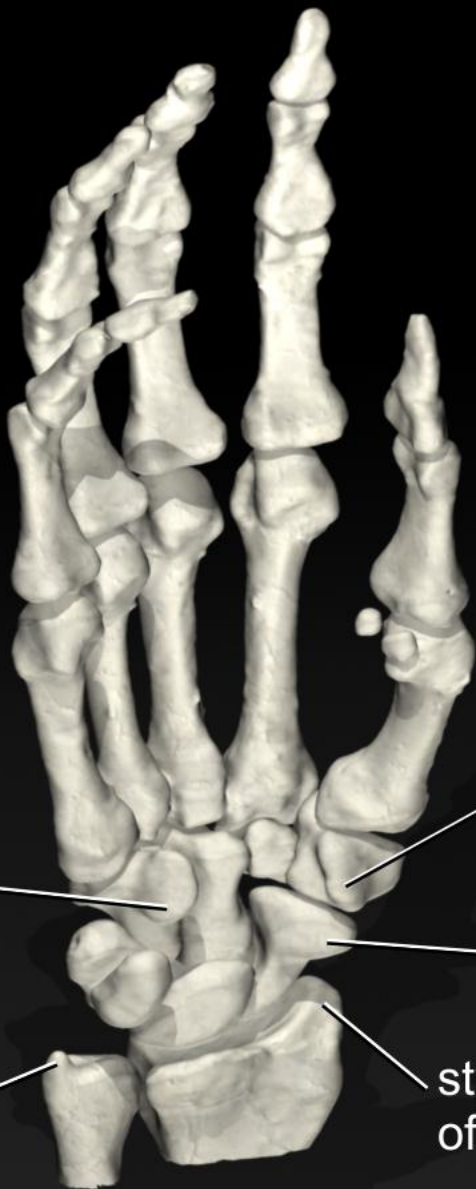dorsal venous network

basilic vein



Witmerlab





hook of hamate

tubercle of trapezium

tubercle of scaphoid

styloid process of ulna

styloid process of radius



distal
phalanges of
digits II, III, IV

middle
phalanges

proximal
phalanges

metacarpals

trapezium

hamate

trapezoid

capitate

scaphoid

triquetrum

radius

lunate

ulna



witmerlab

