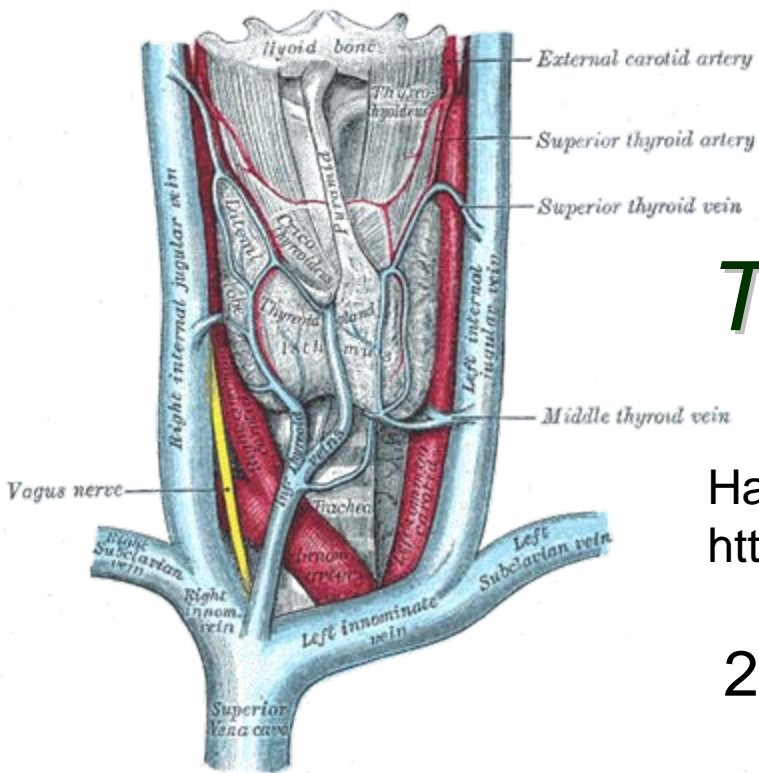

Clinical Anatomy of the Thyroid and Adrenal Glands

Handout download:

<http://www.oucom.ohiou.edu/dbms-witmer/gs-rpac.htm>

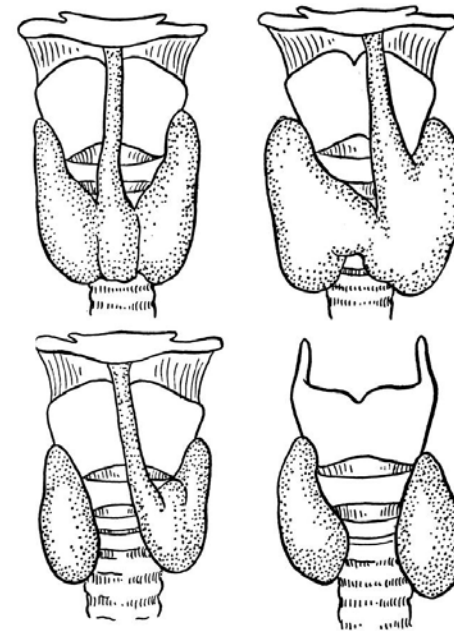
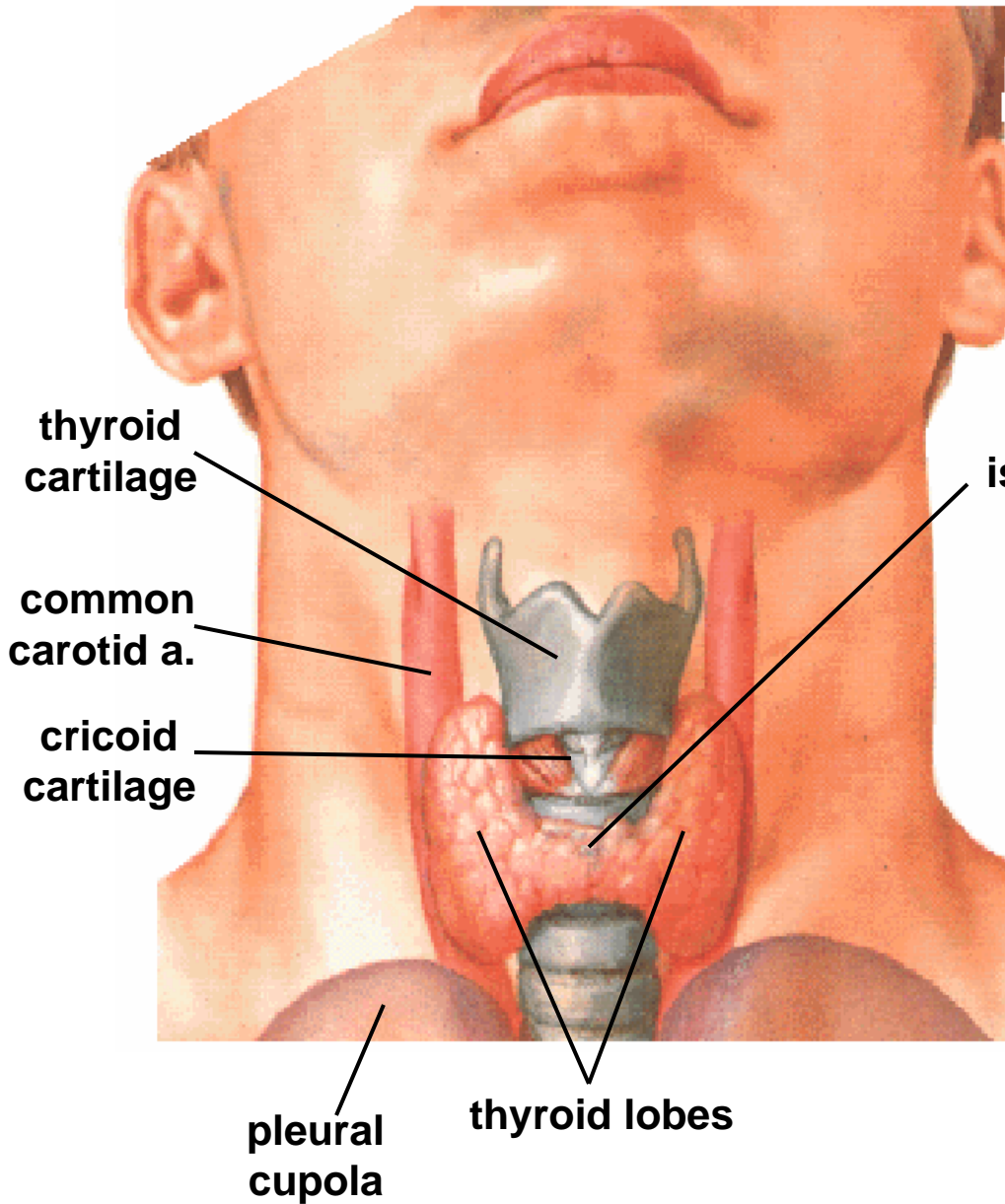
25 September 2007

Lawrence M. Witmer, PhD
Professor of Anatomy
Department of Biomedical Sciences
College of Osteopathic Medicine
Ohio University
Athens, Ohio 45701
witmerL@ohio.edu



Anatomical Overview

- Right & left lobes connected by an isthmus
- Occasional pyramidal lobe
- Levator glandulae thyroideae
- Slightly larger in women; may enlarge during menstruation & pregnancy
- Extends from oblique line on isthmus thyroid cartilage down to 4th or 5th tracheal ring
- Attaches to cricoid cartilage via suspensory ligament



Case Presentation

A 32-year-old woman presents with a swelling on the anterior part of her neck. She also reports that her breathing is sometimes affected by the swelling. On examination, a single, firm, rounded mass can be felt on the left side of the laryngotracheal region. It moves up and down with swallowing. Ultrasound reveals a solid nodule in the left lobe of her thyroid gland. A needle biopsy subsequently indicates that malignant changes have taken place in the cells.

Preliminary Diagnosis:

Tumor of the left lobe of the thyroid

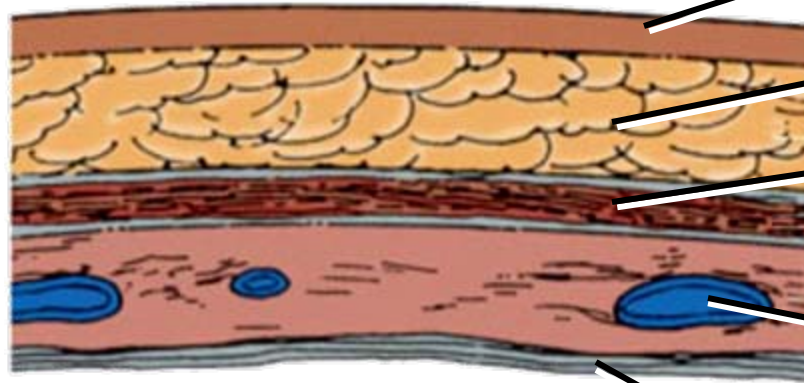
Questions

- 1. Why does the mass move up and down on swallowing?**
2. What can explain the difficulty breathing?
3. What structures would be endangered by subtotal or total thyroidectomy?
4. Why is the nature of the patient's voice of interest postoperatively?

Fascia & Spaces

**superficial
fascia**

Skandalakis' Surgical
Anatomy 2004



skin

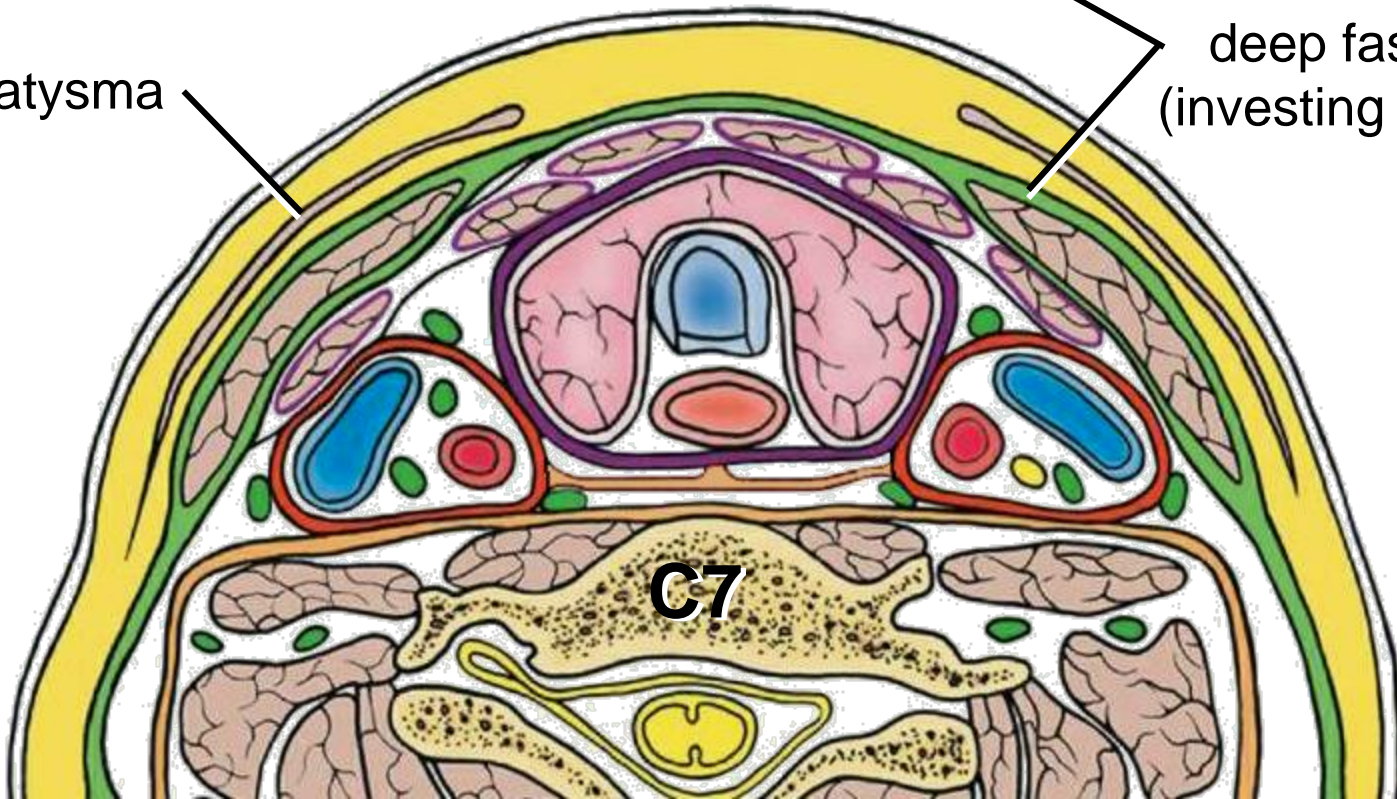
fat

platysma

veins (ant. &
ext. jug.) and
cutaneous nn.

platysma

deep fascia
(investing layer)



C7

Moore &
Dalley 2006

Fascia & Spaces

Deep Fascia

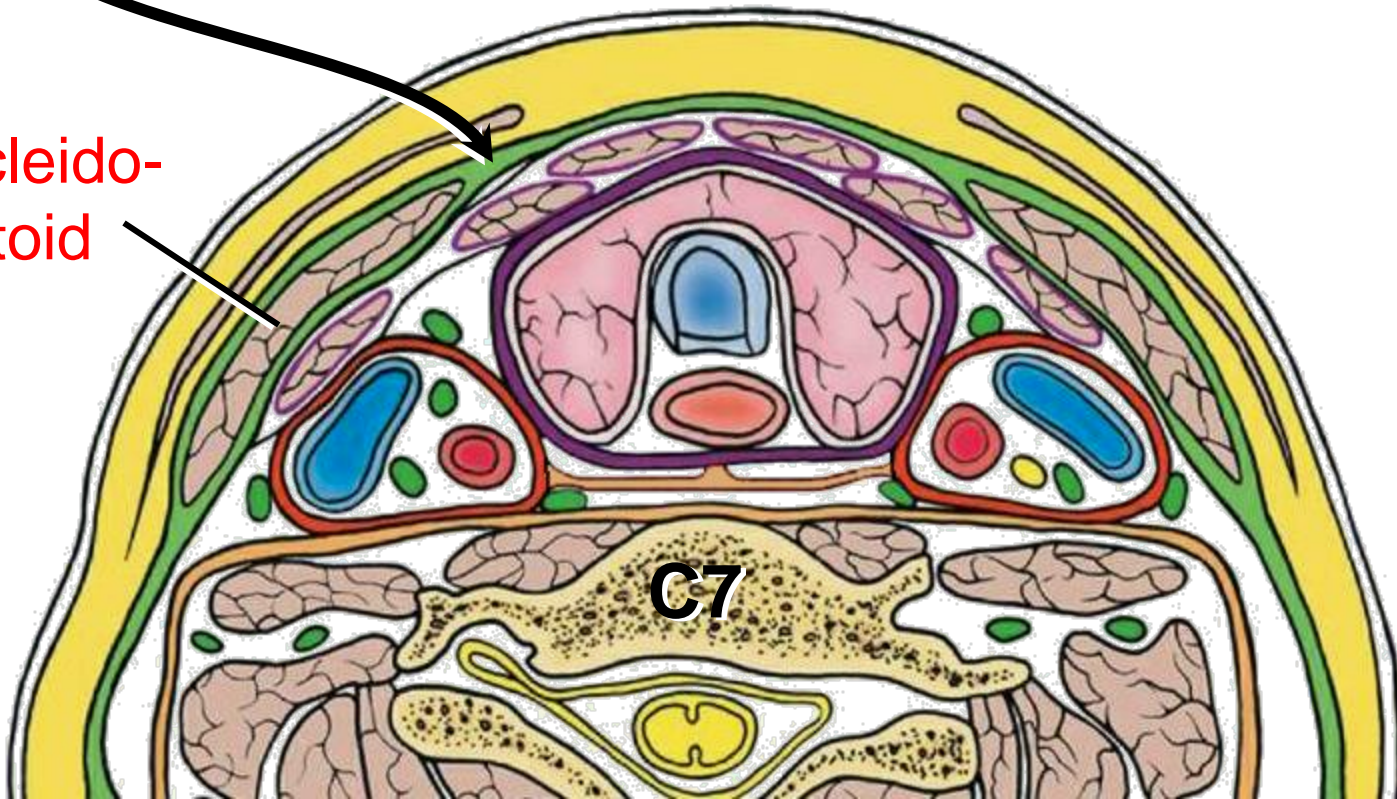
1. investing fascia

2. pretracheal fascia

3. prevertebral fascia

4. carotid sheath

sternocleido-
mastoid



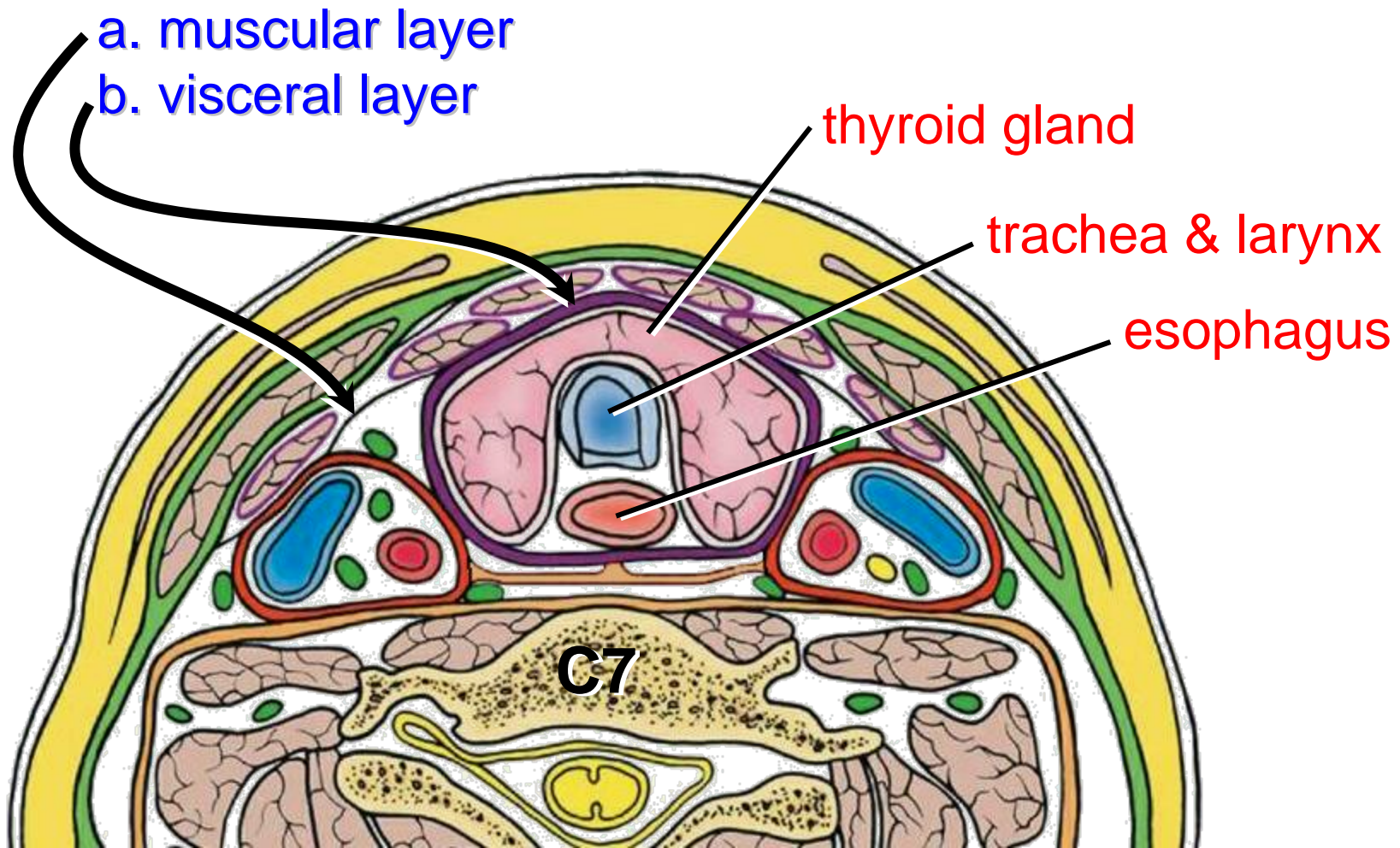
C7

Fascia & Spaces

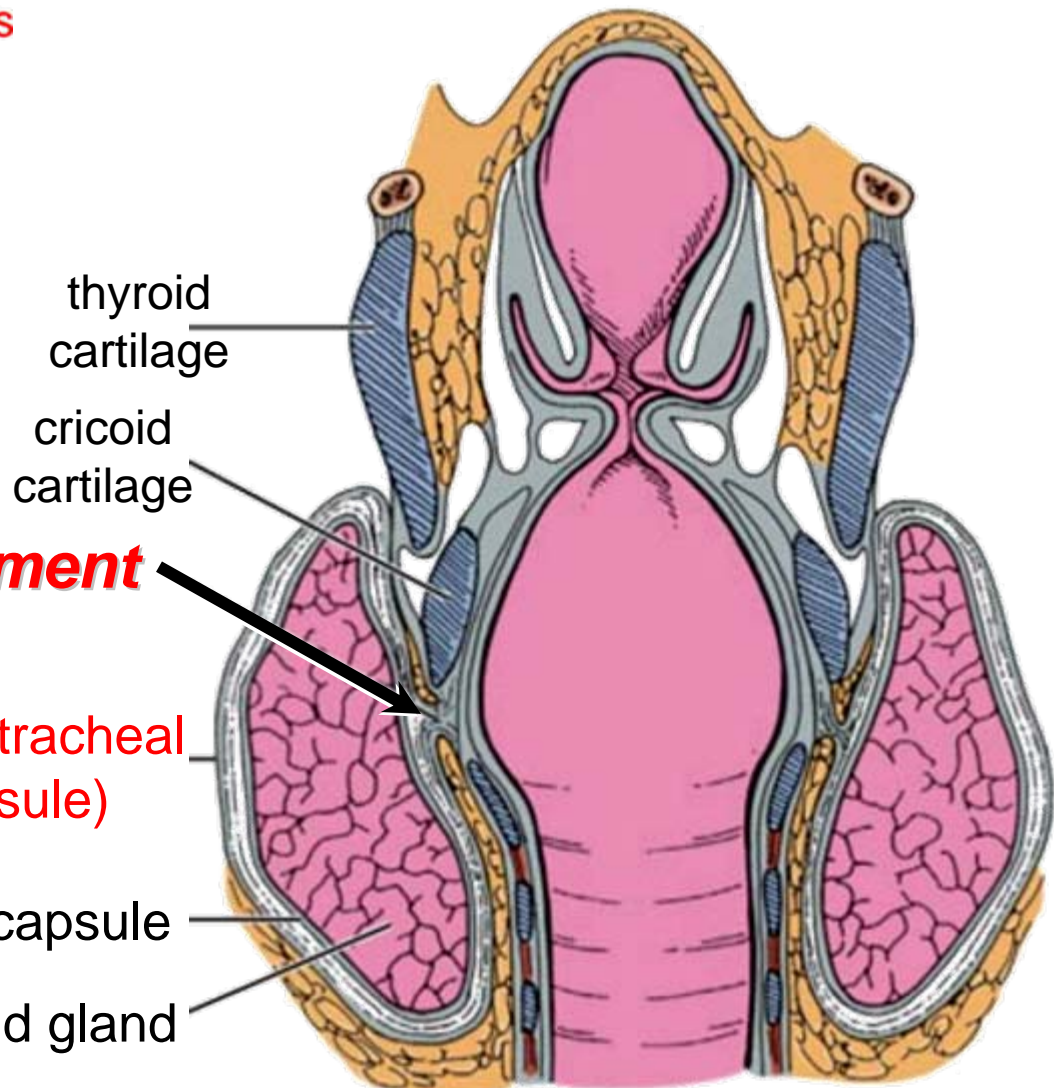
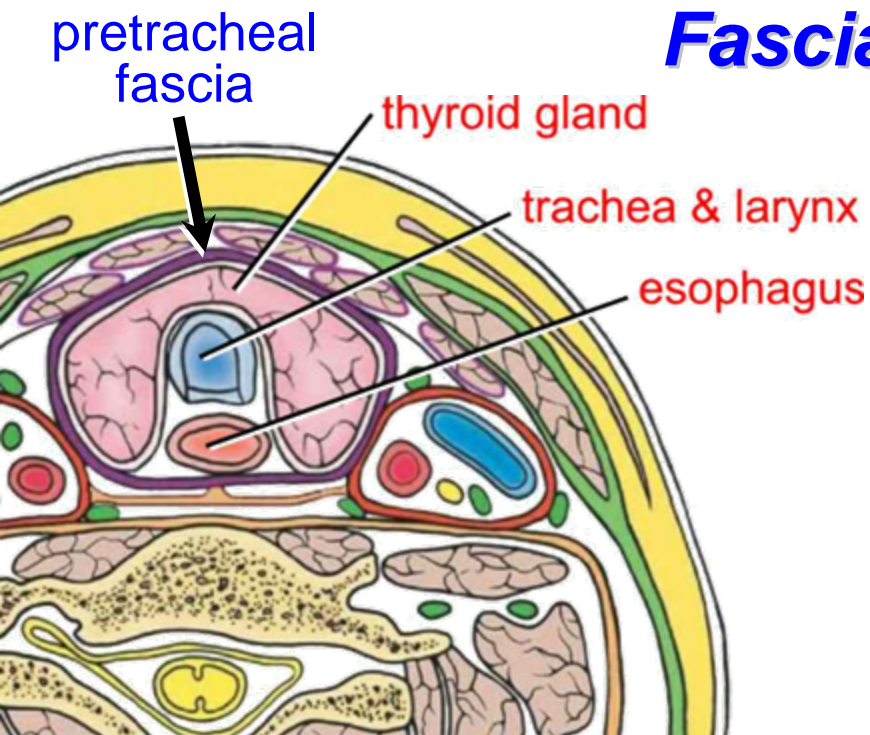
Deep Fascia

1. investing fascia
2. pretracheal fascia
 - a. muscular layer
 - b. visceral layer

3. prevertebral fascia
4. carotid sheath



Fascia & Spaces



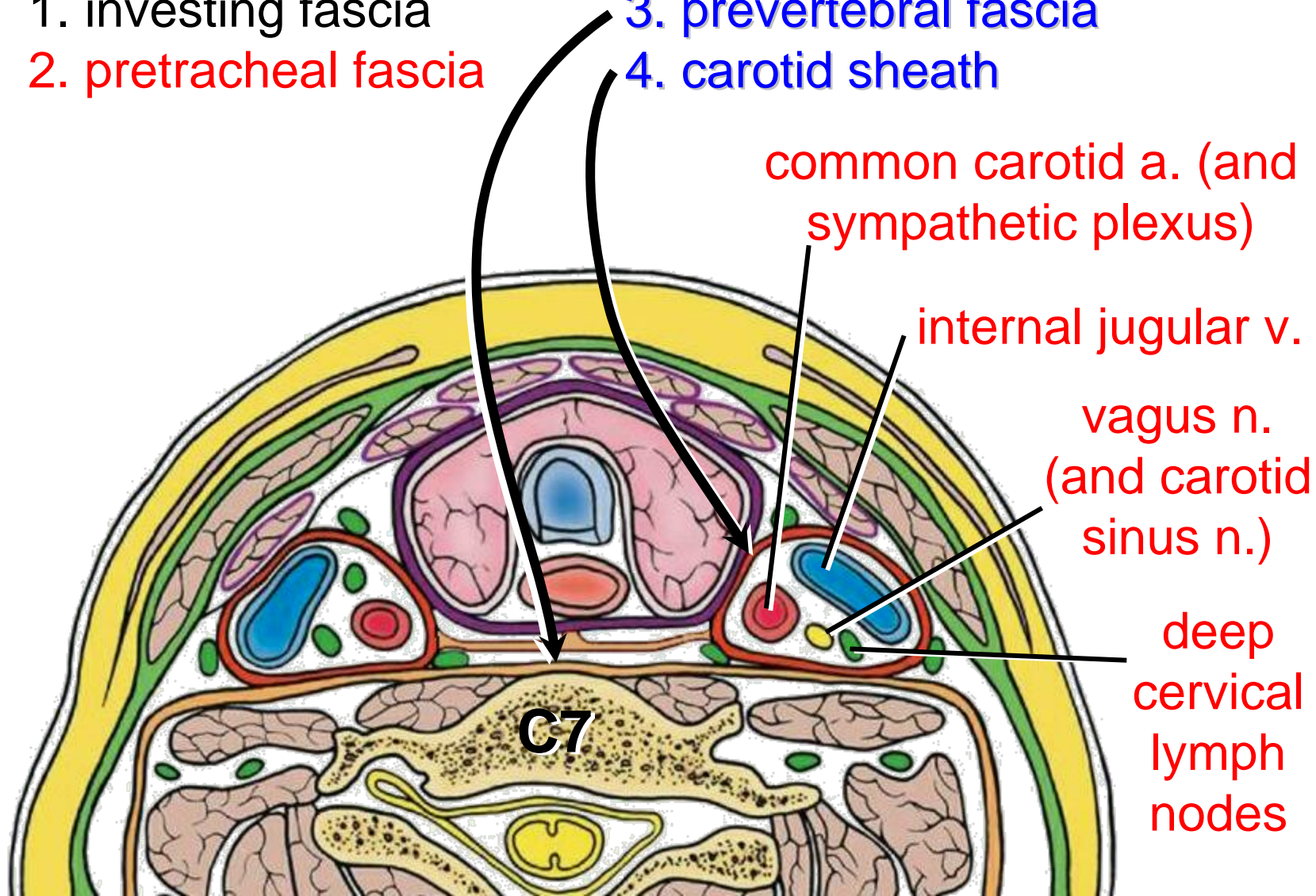
Moore & Dalley 2006

Fascia & Spaces

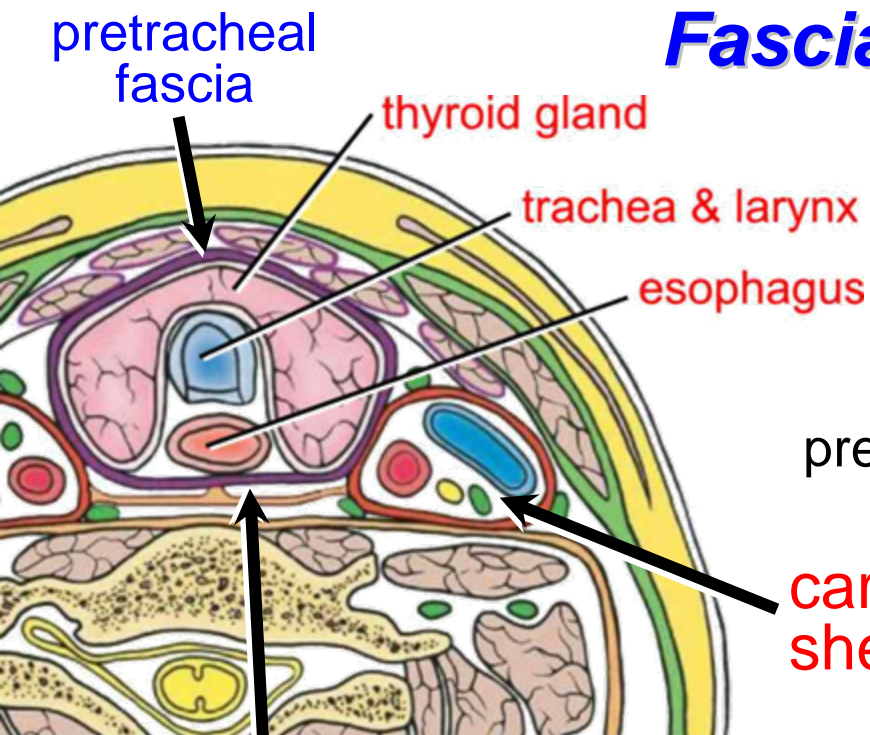
Deep Fascia

1. investing fascia
2. pretracheal fascia

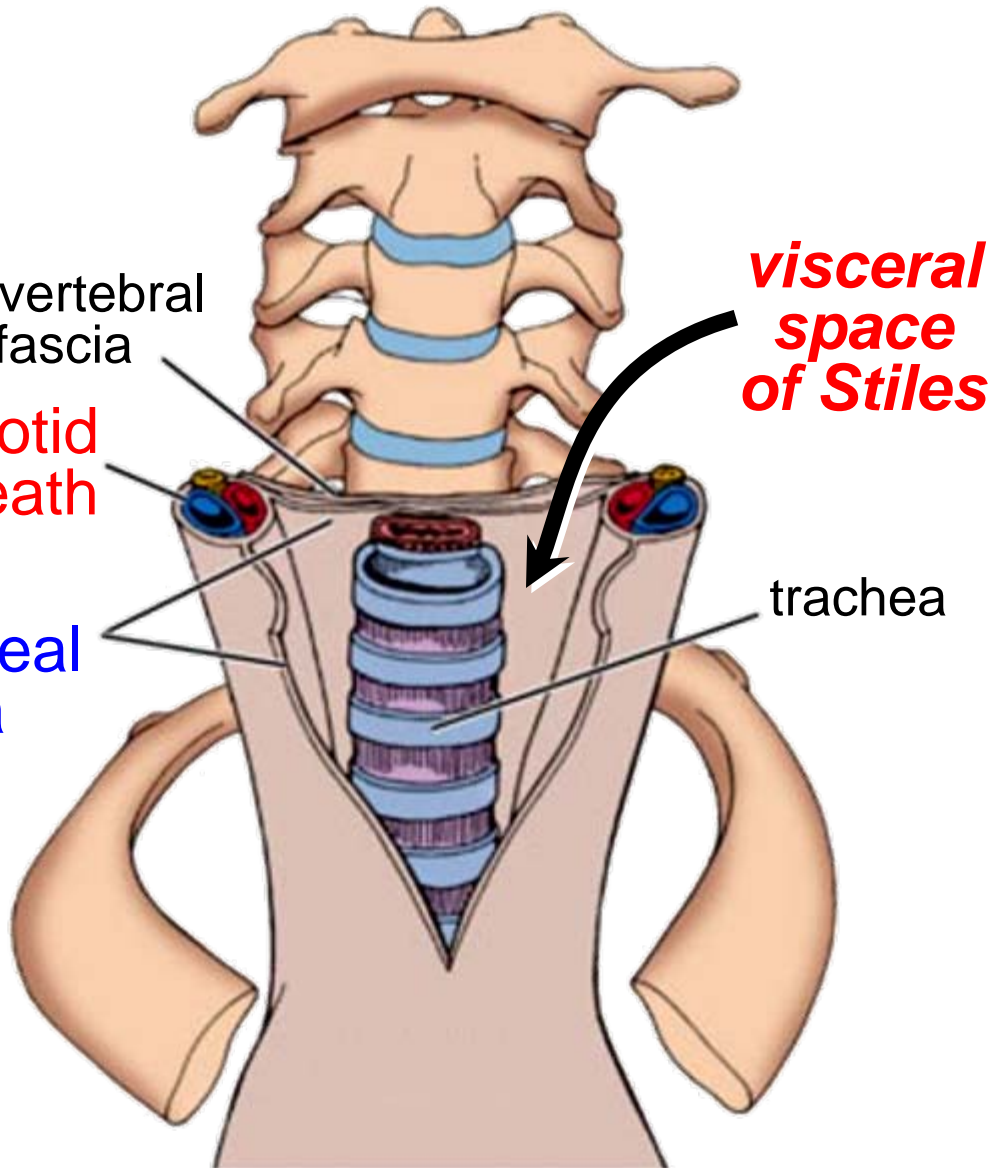
3. prevertebral fascia
4. carotid sheath



Fascia & Spaces



Moore & Dalley 2006

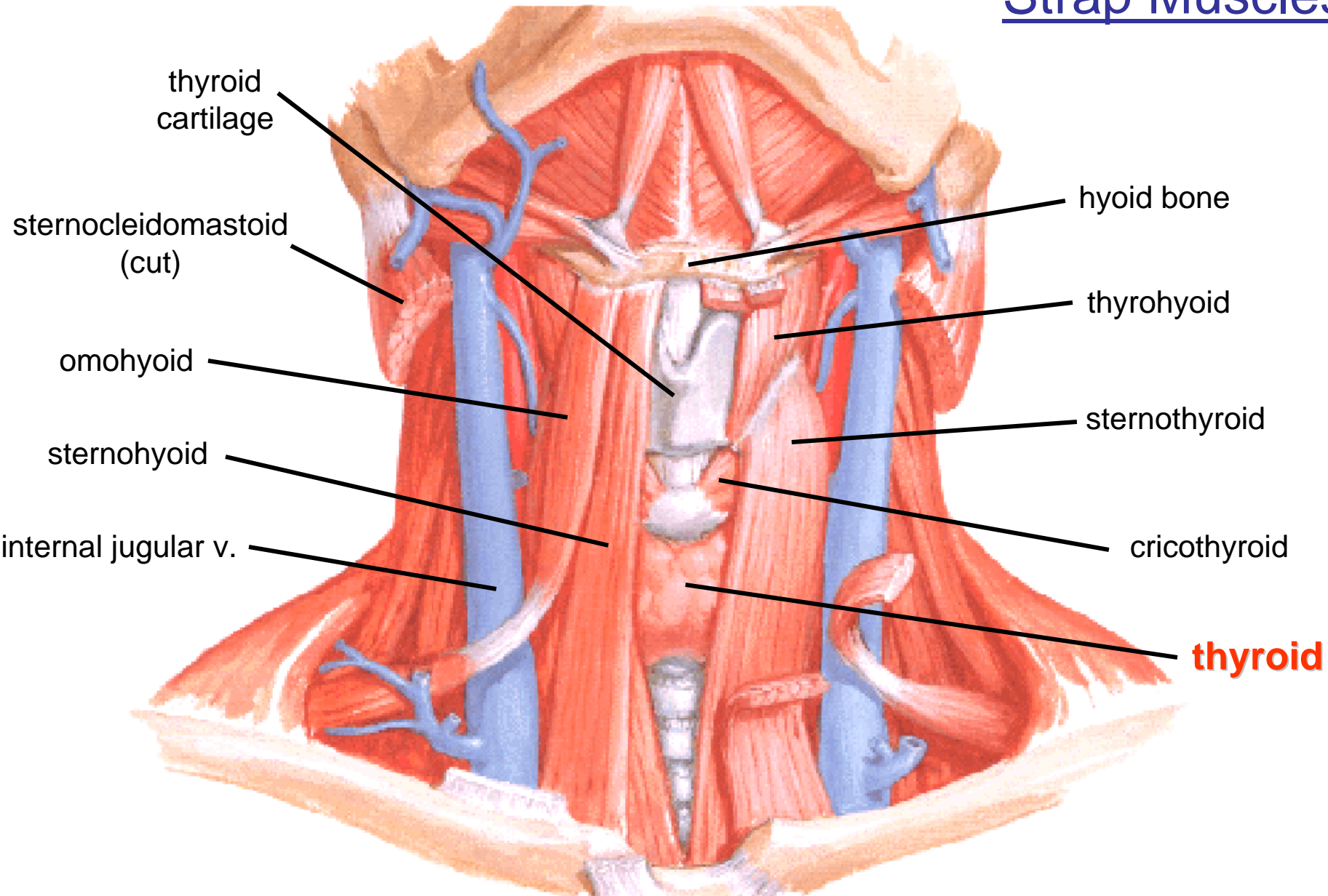


Skandalakis' Surgical Anatomy 2004

not discussed today:

- suprasternal space of Burns
- "Danger space" of Grodinsky & Holyoke

Strap Muscles

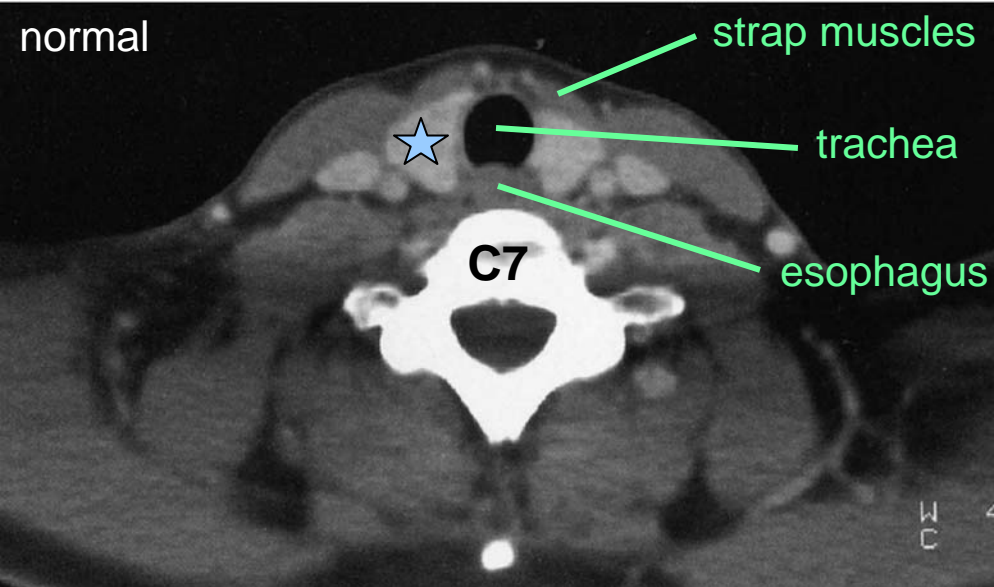


Attachment of sternothyroid to oblique line on thyroid cartilage prevents superior expansion of thyroid

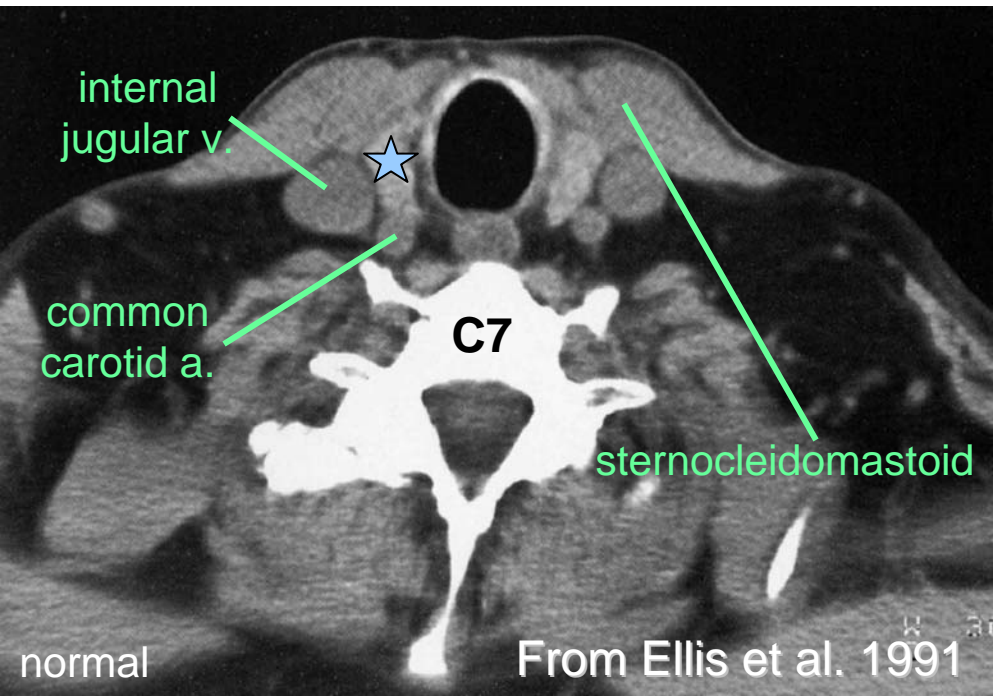
From Netter's Atlas

Questions

1. Why does the mass move up and down on swallowing?
- 2. What can explain the difficulty breathing?**
3. What structures would be endangered by subtotal or total thyroidectomy?
4. Why is the nature of the patient's voice of interest postoperatively?

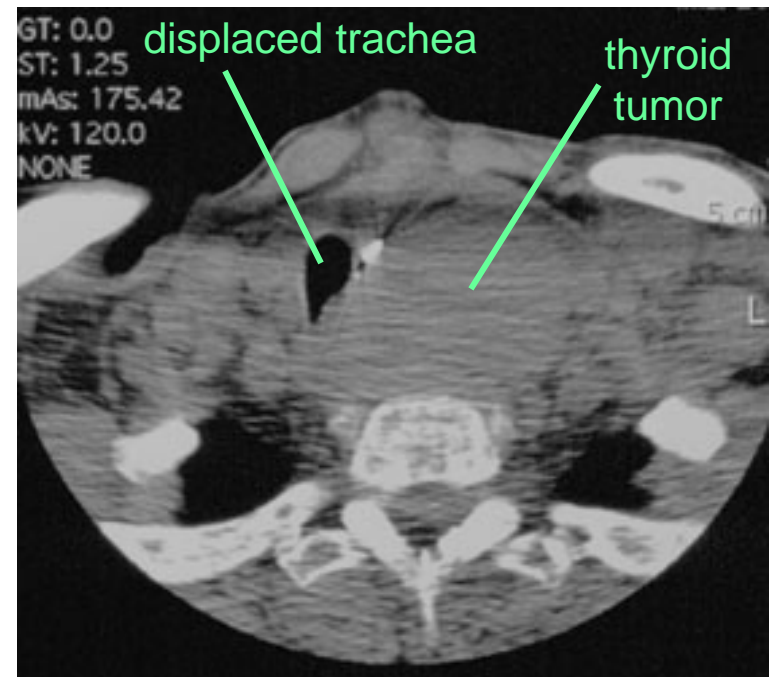


Thyroid (★)



Thyroid CT

Compression and displacement of trachea by thyroid tumor



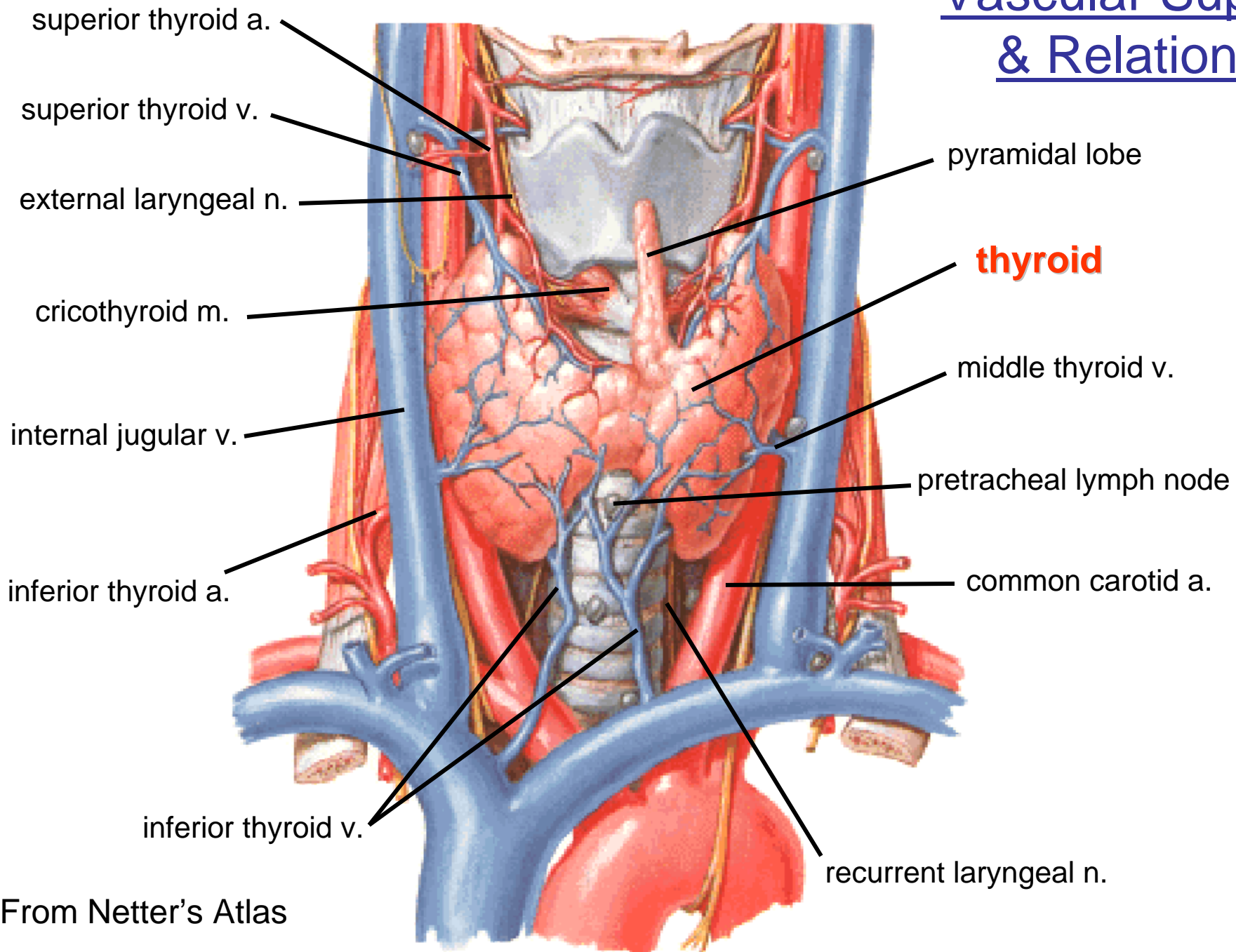
From web reference 1

Questions

1. Why does the mass move up and down on swallowing?
2. What can explain the difficulty breathing?
- 3. What structures would be endangered by subtotal or total thyroidectomy?**
4. Why is the nature of the patient's voice of interest postoperatively?

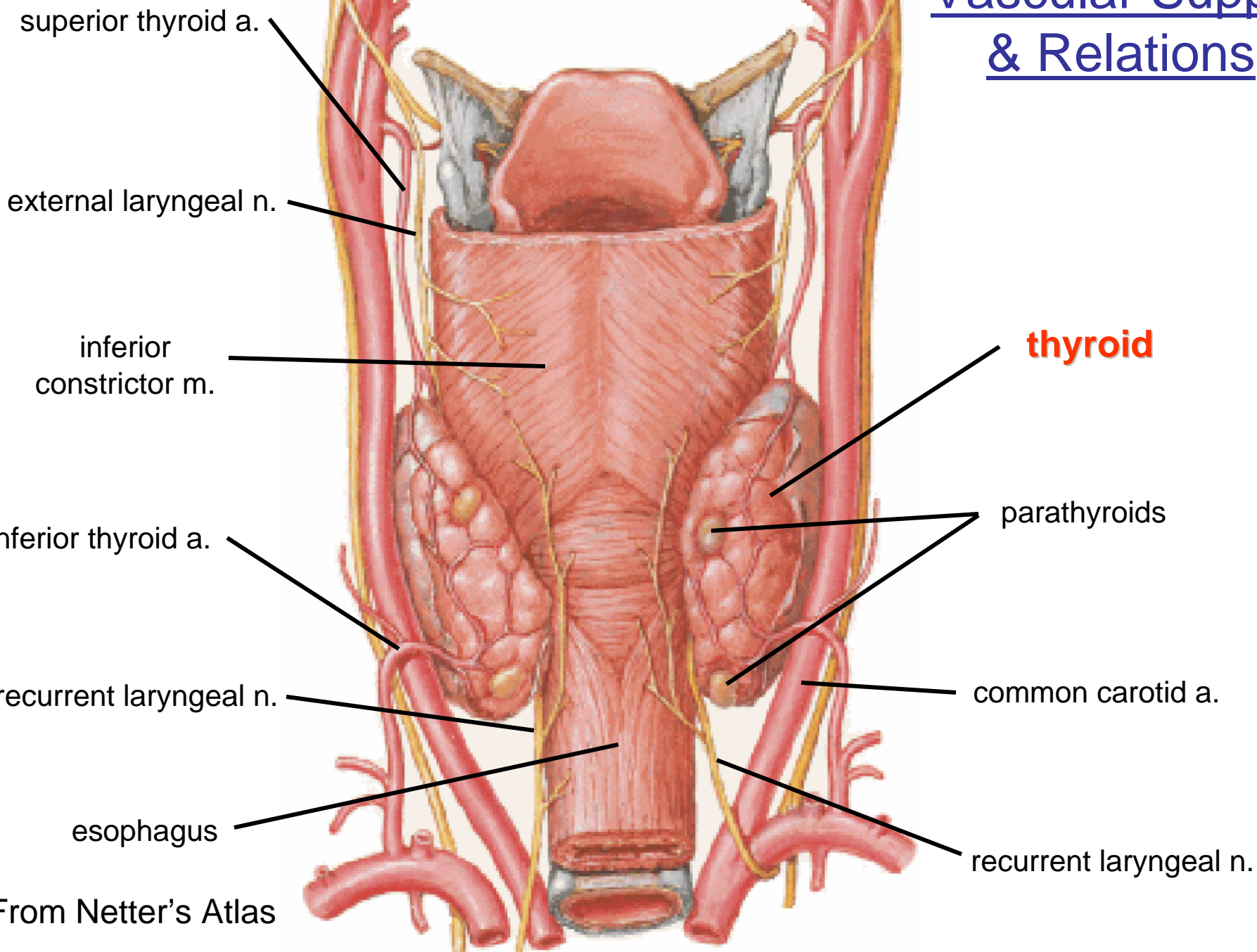
Anterior View

Vascular Supply & Relations



Posterior View

Vascular Supply & Relations

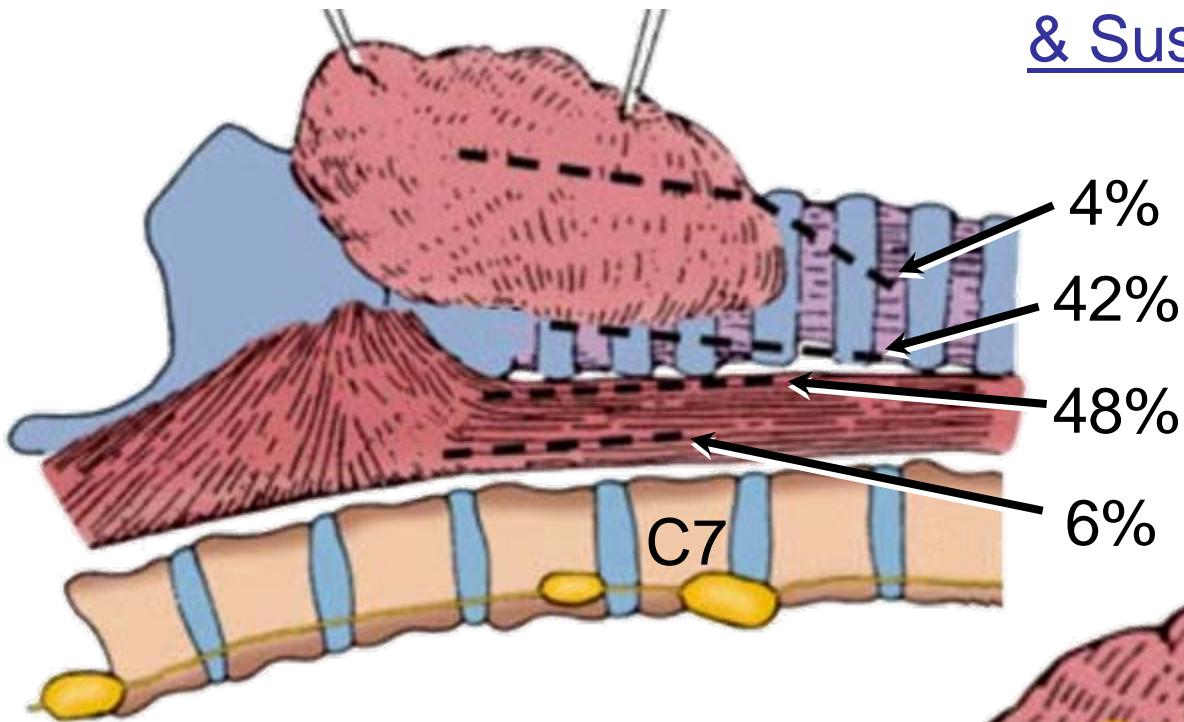


Questions

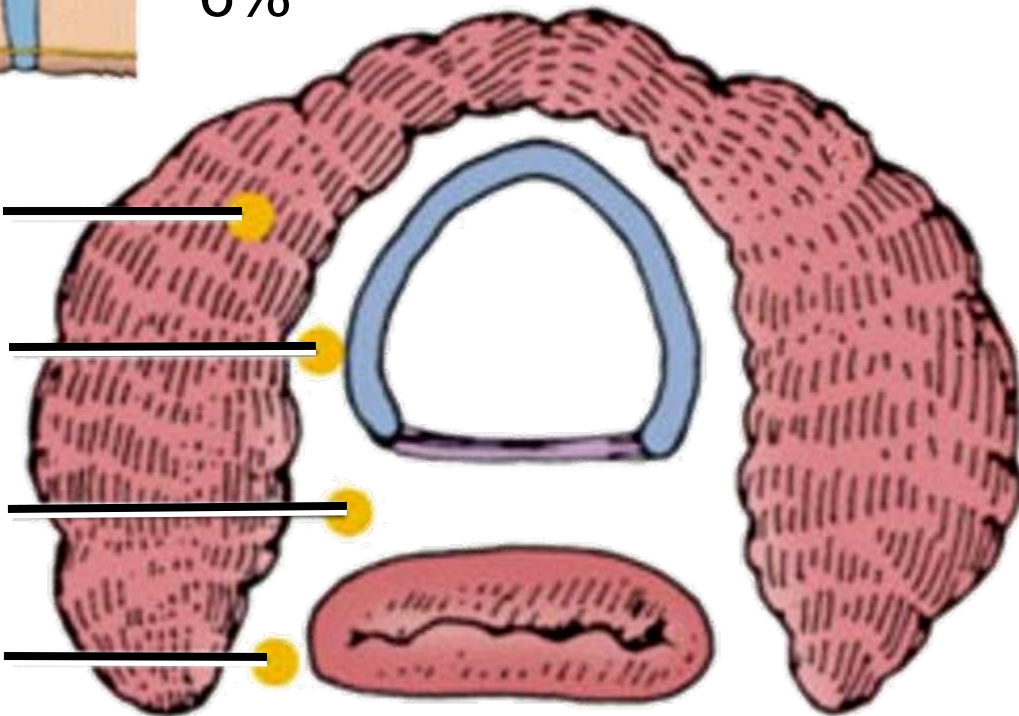
1. Why does the mass move up and down on swallowing?
2. What can explain the difficulty breathing?
3. What structures would be endangered by subtotal or total thyroidectomy?
- 4. Why is the nature of the patient's voice of interest postoperatively?**

Recurrent Laryngeal N. & Suspensory Lig. of Berry

variation in recurrent laryngeal nerve position (n = 204)

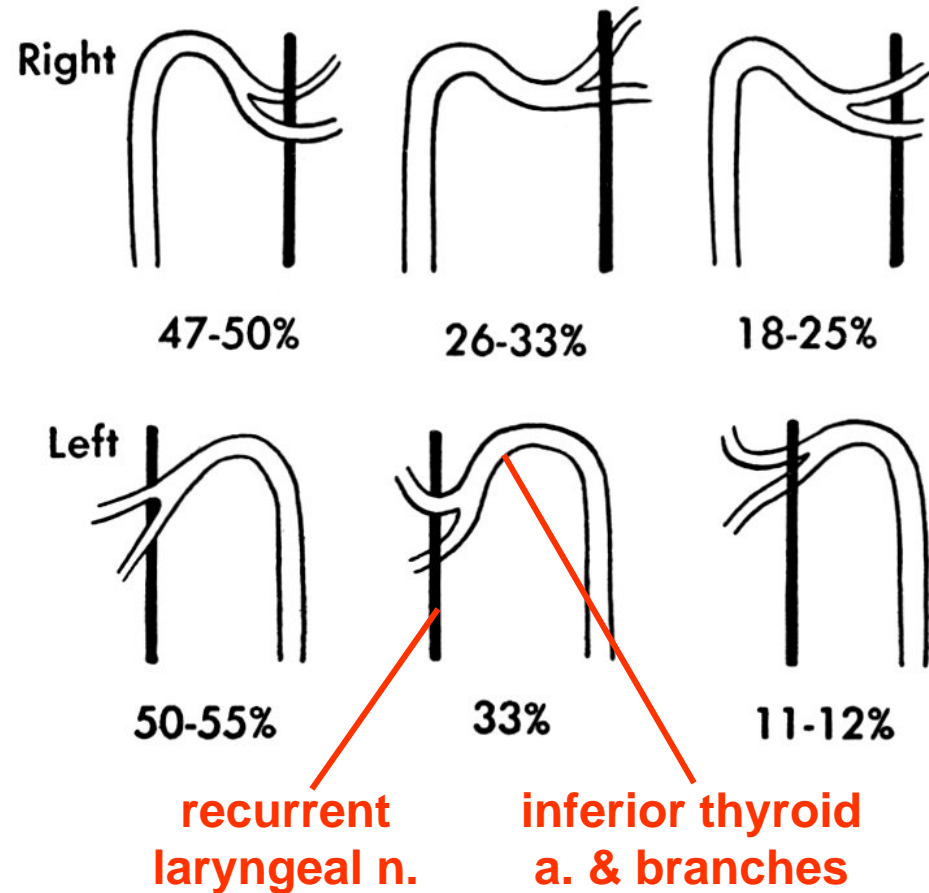
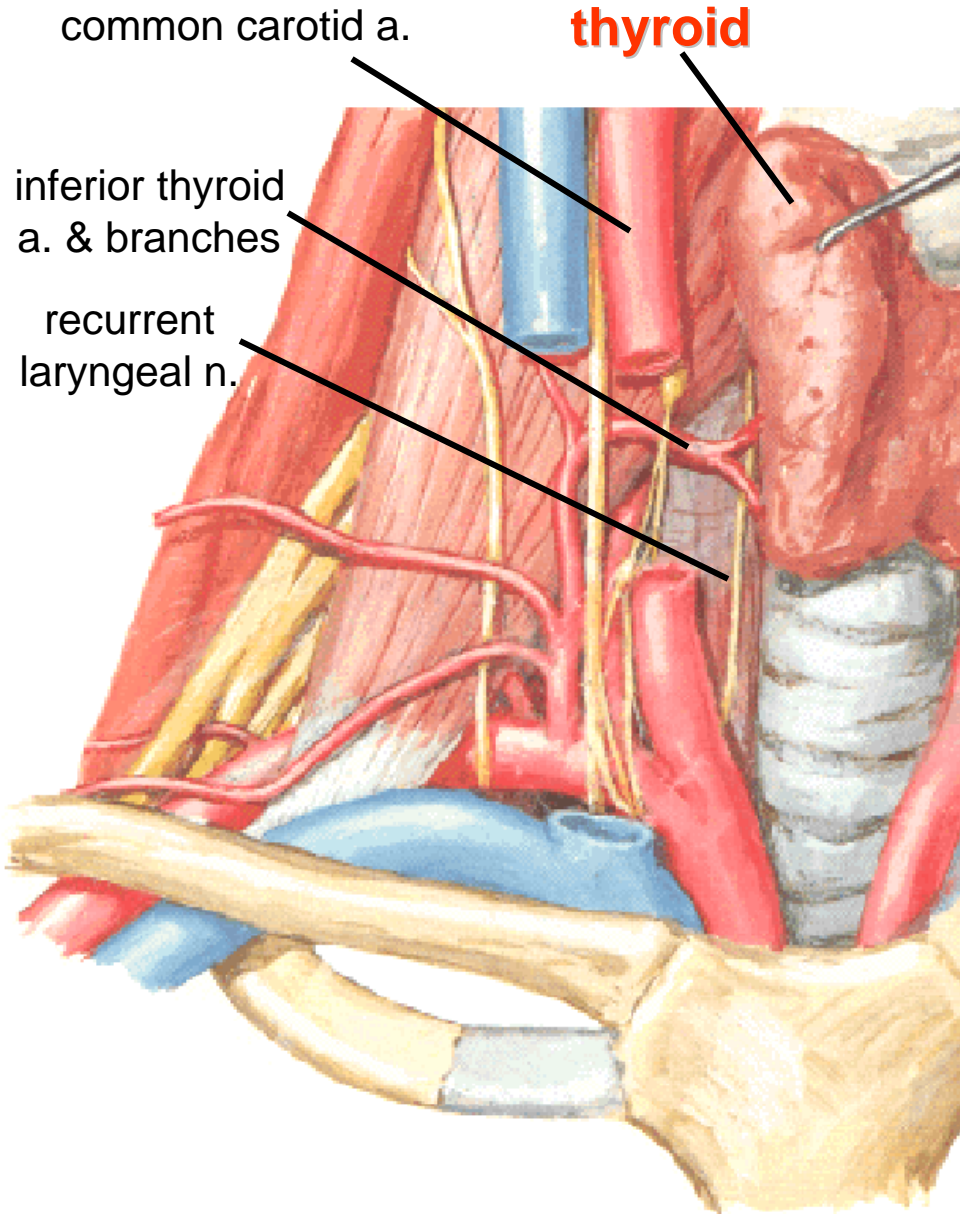


- 4% intrathyroid
- 42% paratracheal
- 48% tracheoesoph. groove
- 6% paraesophageal



Recurrent Laryngeal N. & Suspensory Lig. of Berry

Variation in relationship of recurrent laryngeal n. to inferior thyroid a.

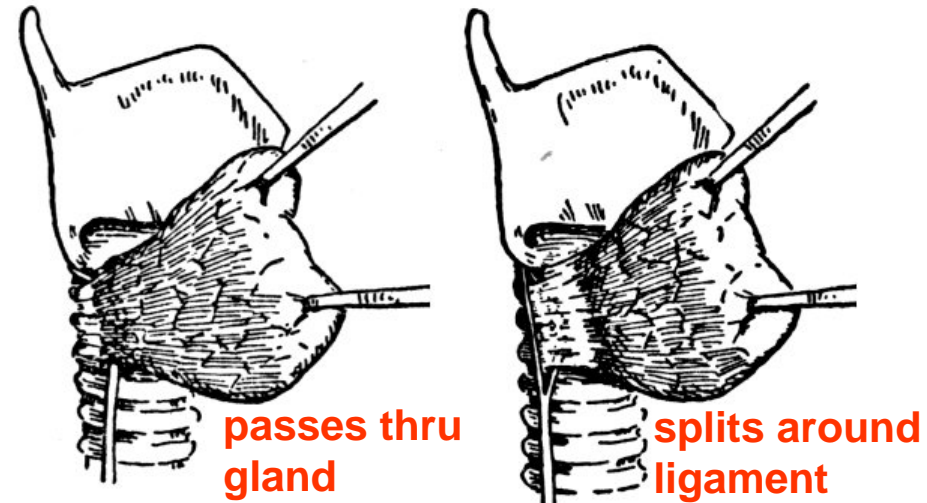
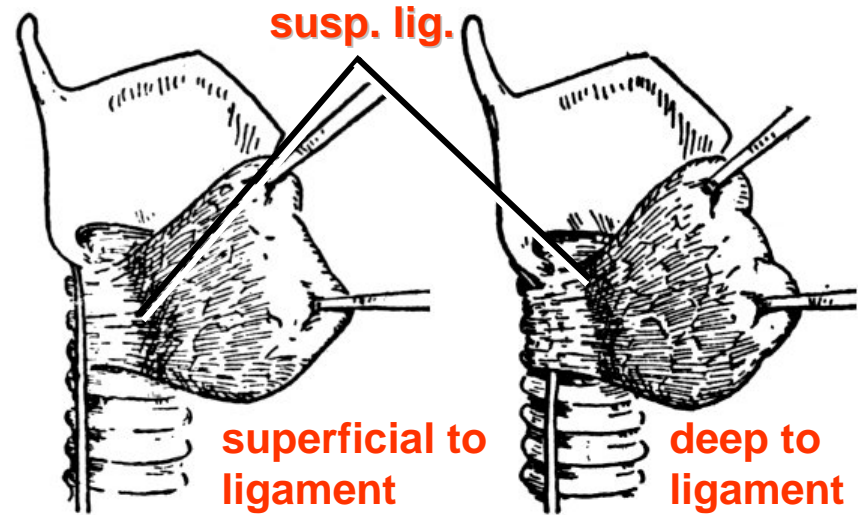
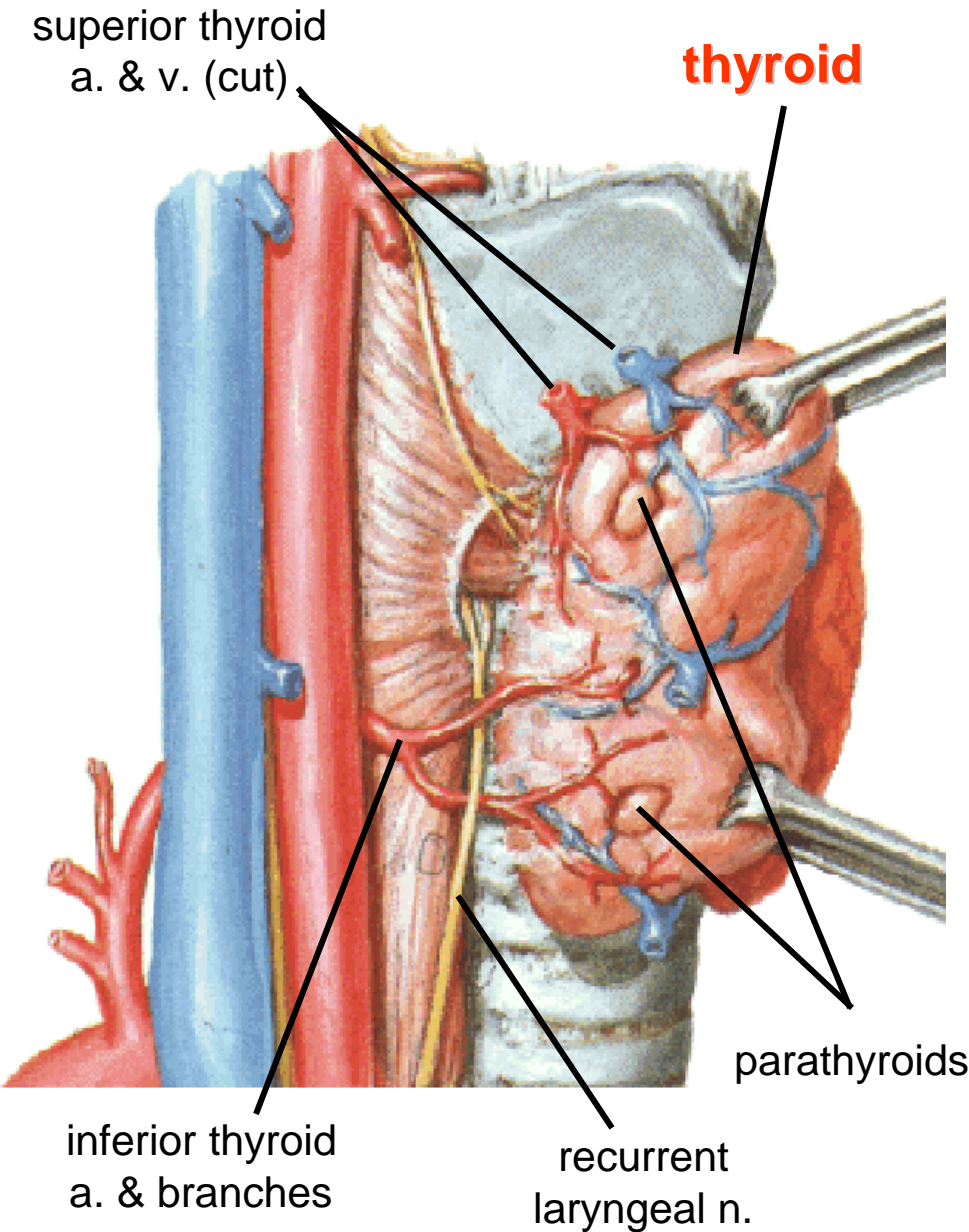


(from Hollinshead 1968)

From Netter's Atlas

Recurrent Laryngeal N. & Suspensory Lig. of Berry

Variation in relationship of recurrent laryngeal n. to suspensory lig.

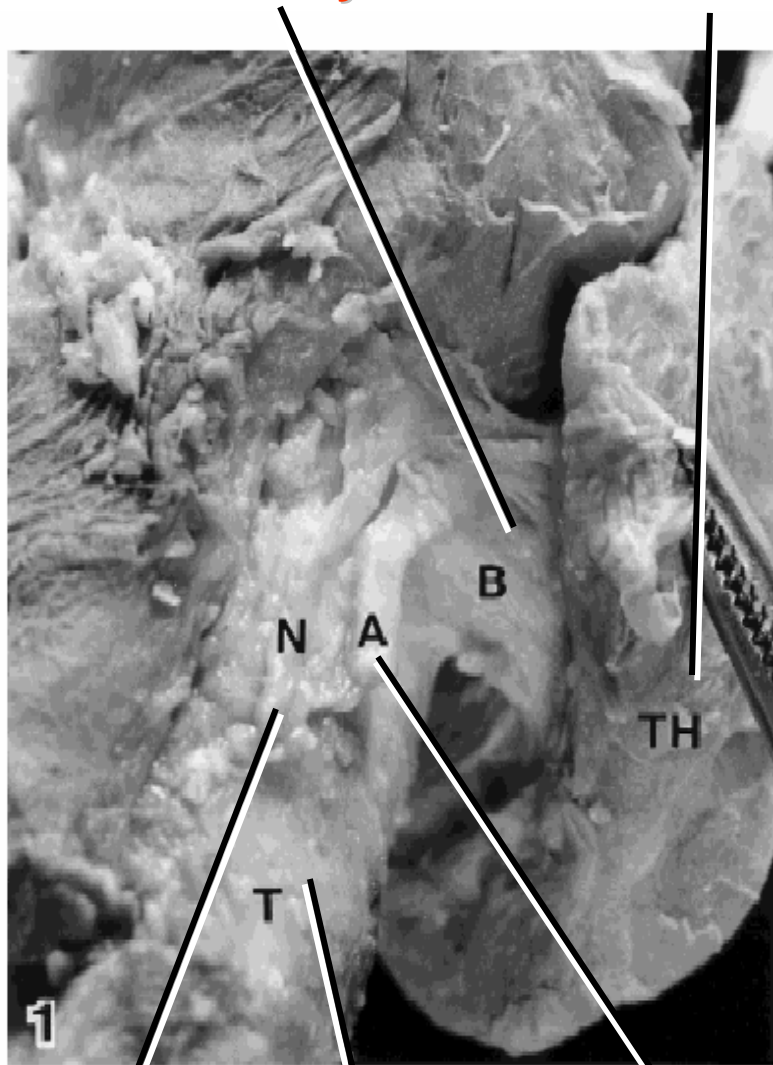


(from Hollinshead 1968)

From Netter's Atlas

suspensory ligament of Berry

thyroid



recurrent laryngeal n.

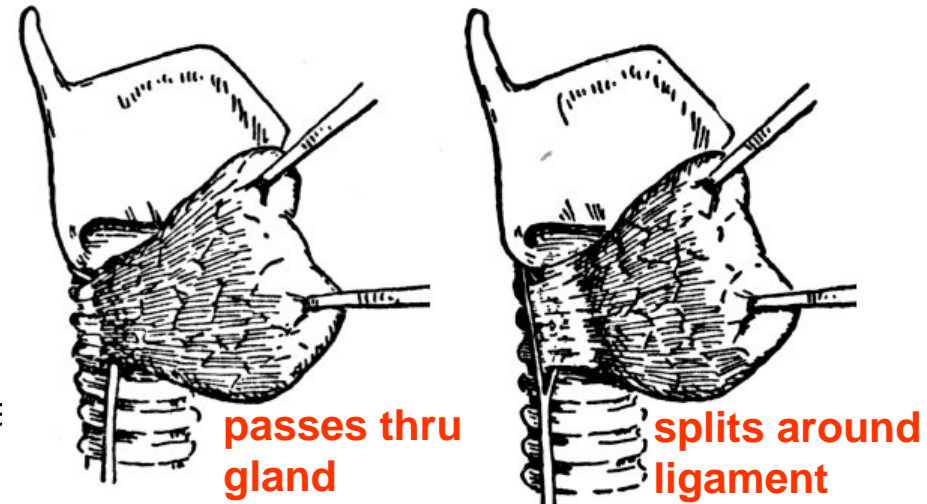
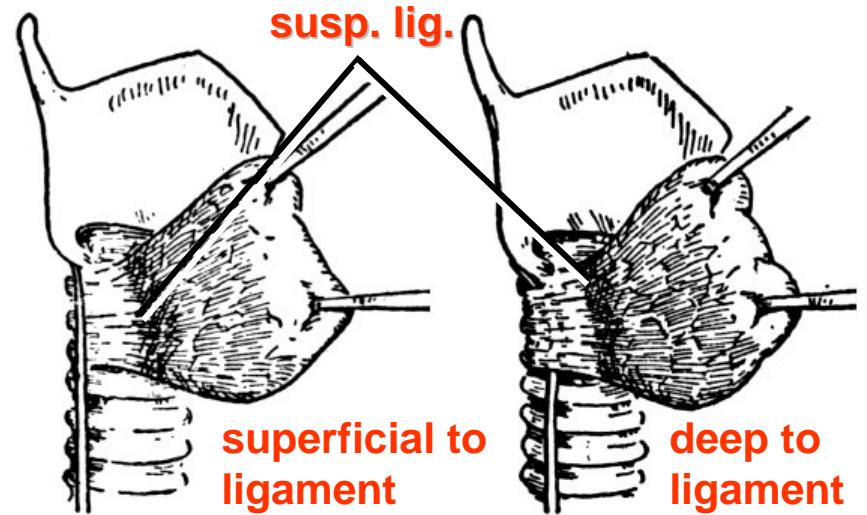
trachea

inferior thyroid a

From Sasou et al. 1998

Recurrent Laryngeal N. & Suspensory Lig. of Berry

Variation in relationship of recurrent laryngeal n. to suspensory lig.

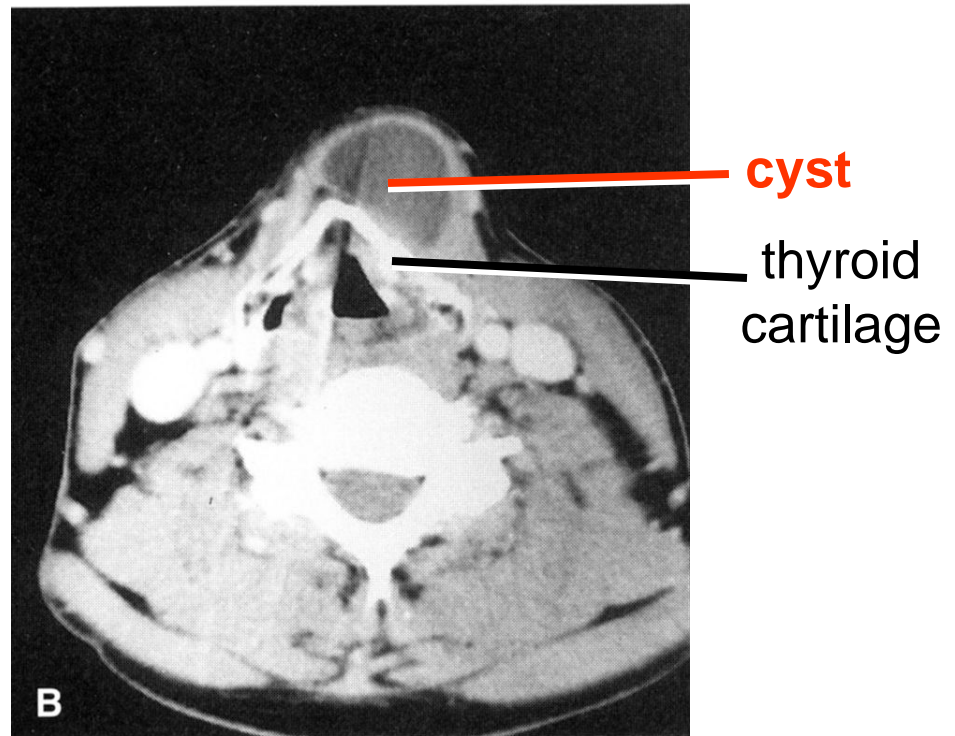


(from Hollinshead 1968)

Case Presentation

A 43-year-old male presents with a swelling in the front of his neck. He first noticed it 9 months ago and it has steadily grown. The lump lays near the midline and moves on swallowing. On palpation, it is firm and lays anterior to the thyroid cartilage. The mass is smooth, non-pulsatile, and non-fluctuant. The dorsum of the tongue was inspected but no thyroid tissue was observed. Ultrasound showed the mass to be cystic and separate from the thyroid gland.

*Preliminary
Diagnosis:*
Thyroglossal Cyst

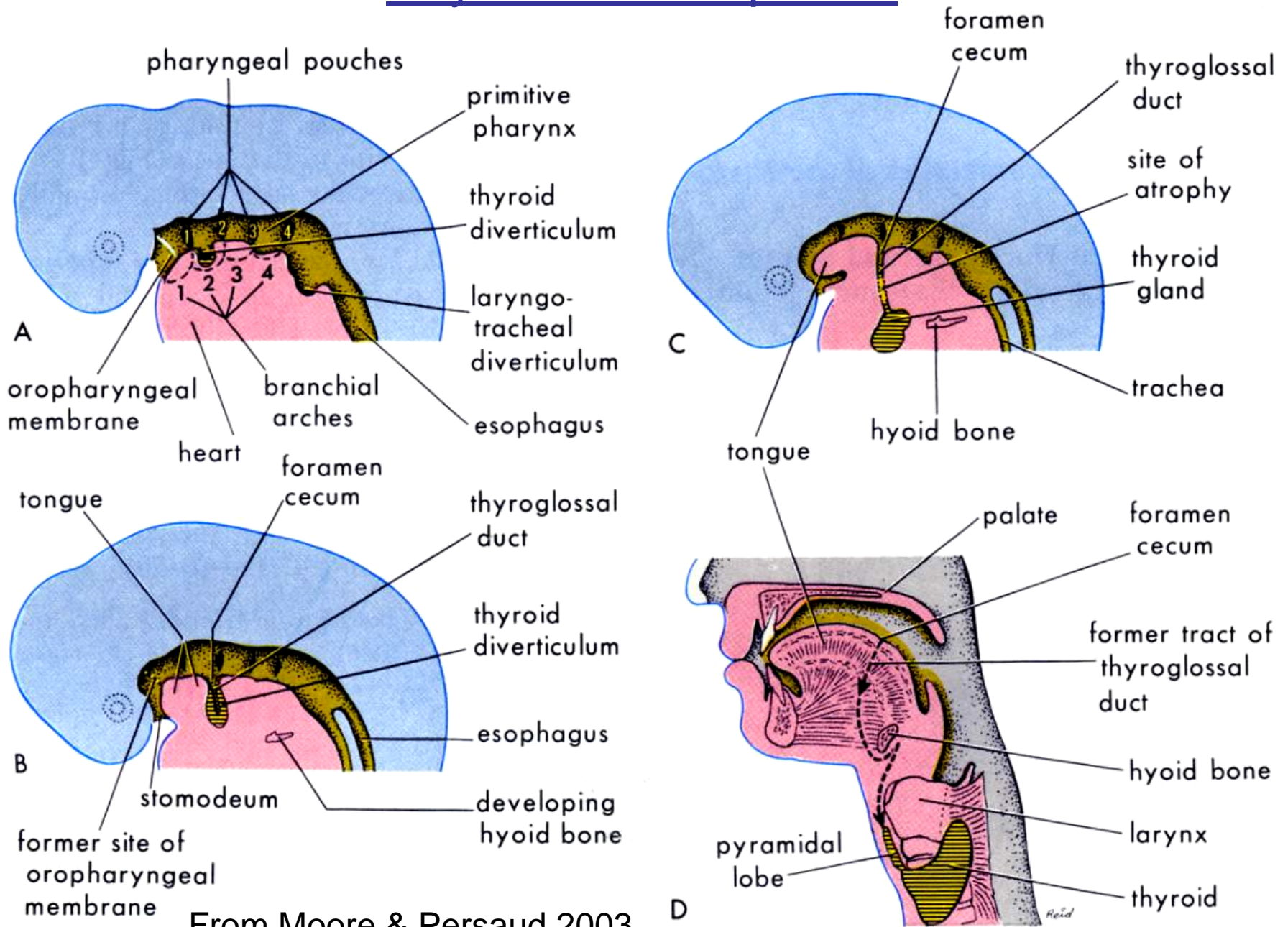


From Moore & Persaud 2003

Questions

- 1. What is the embryonic derivation of a thyroglossal cyst?**
2. Why did the mass move upwards on swallowing?
3. Why did the surgeon look for thyroid tissue on the tongue?

Thyroid Development



From Moore & Persaud 2003

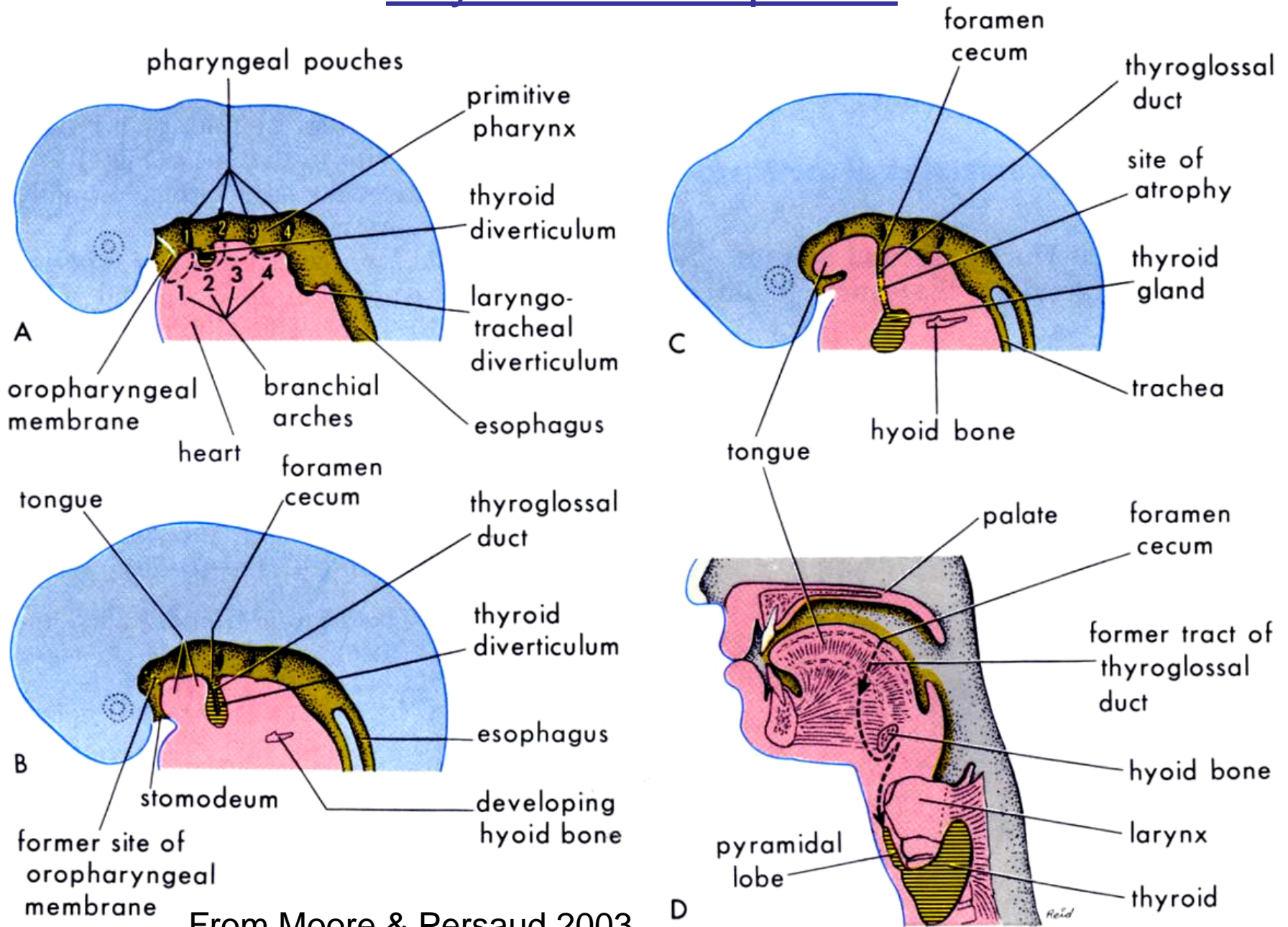
D

Reid

Questions

1. What is the embryonic derivation of a thyroglossal cyst?
- 2. Why did the mass move upwards on swallowing?**
3. Why did the surgeon look for thyroid tissue on the tongue?

Thyroid Development

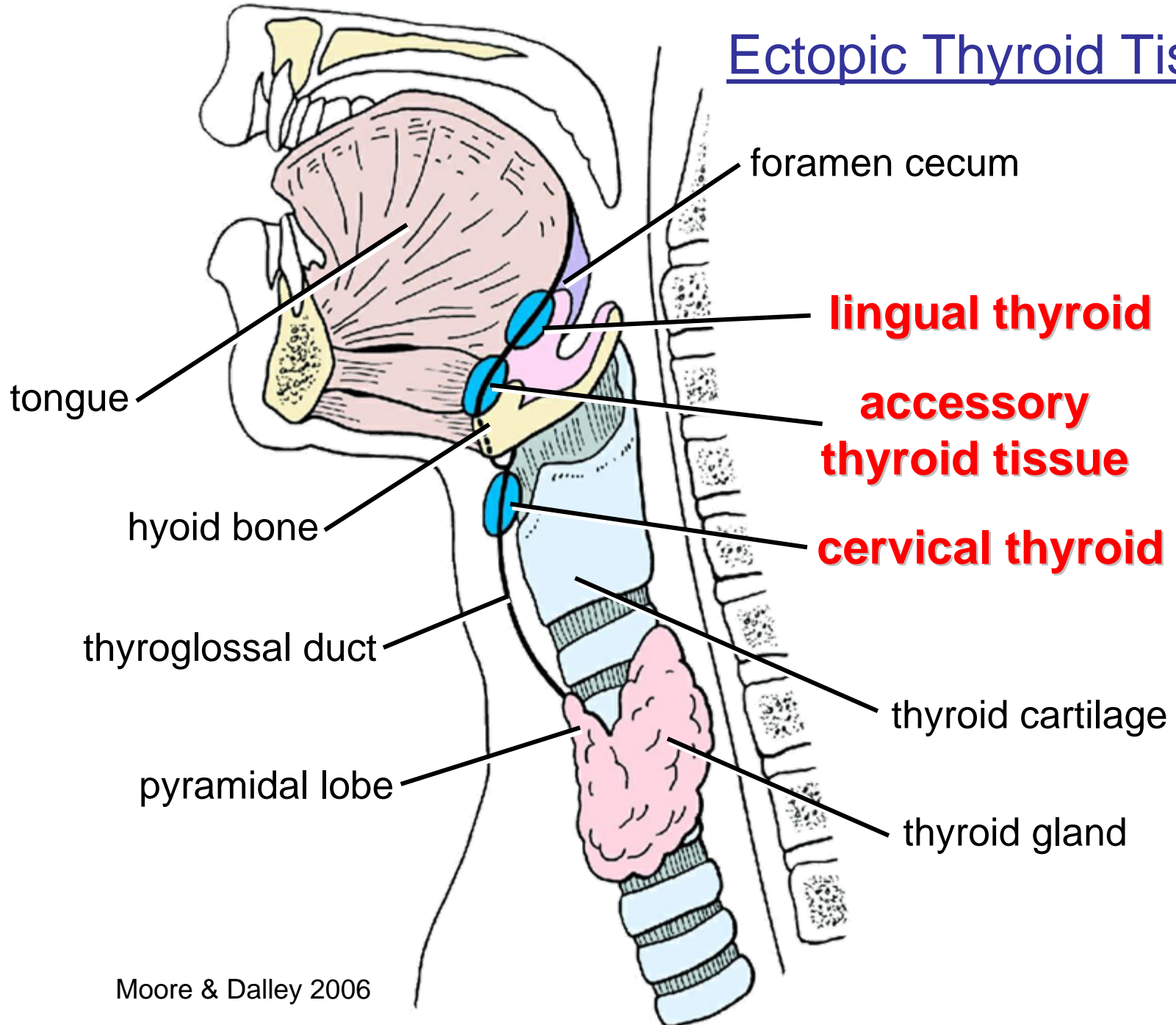


From Moore & Persaud 2003

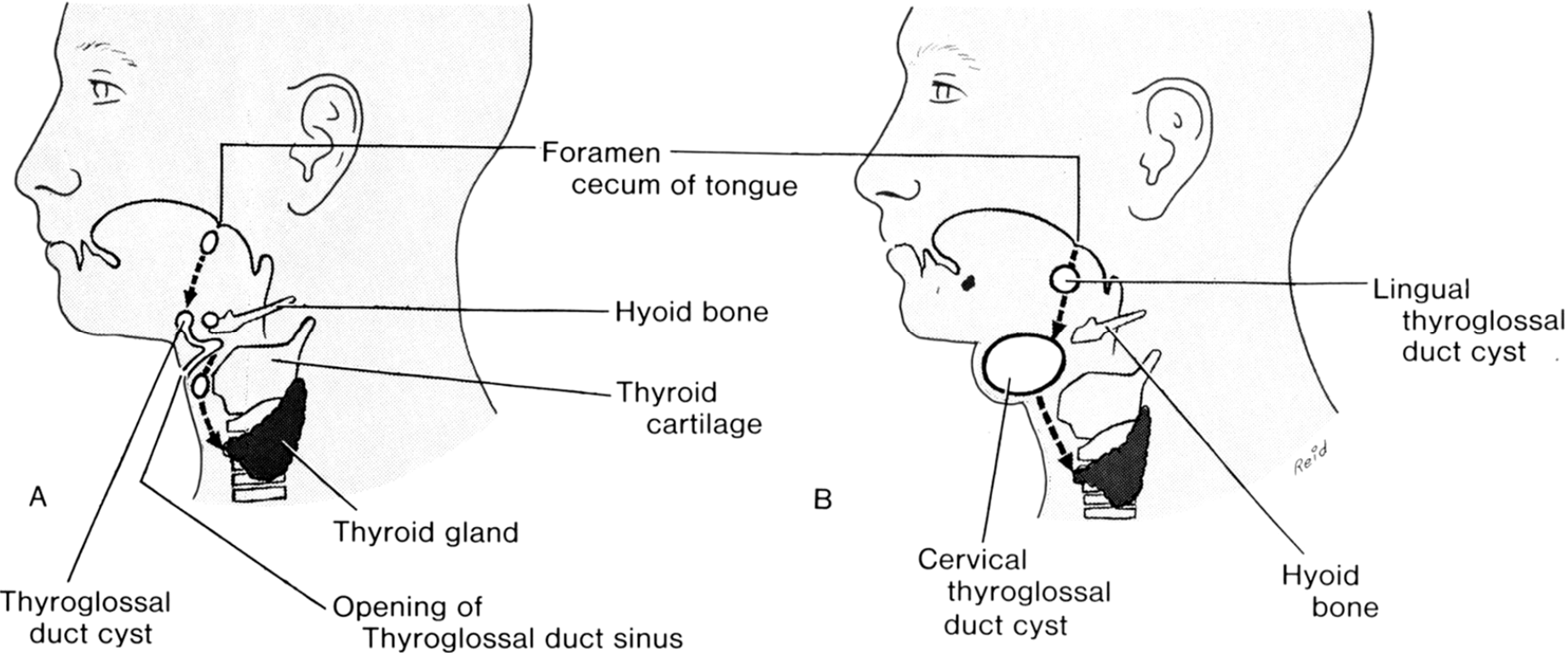
Questions

1. What is the embryonic derivation of a thyroglossal cyst?
2. Why did the mass move upwards on swallowing?
- 3. Why did the surgeon look for thyroid tissue on the tongue?**

Ectopic Thyroid Tissue

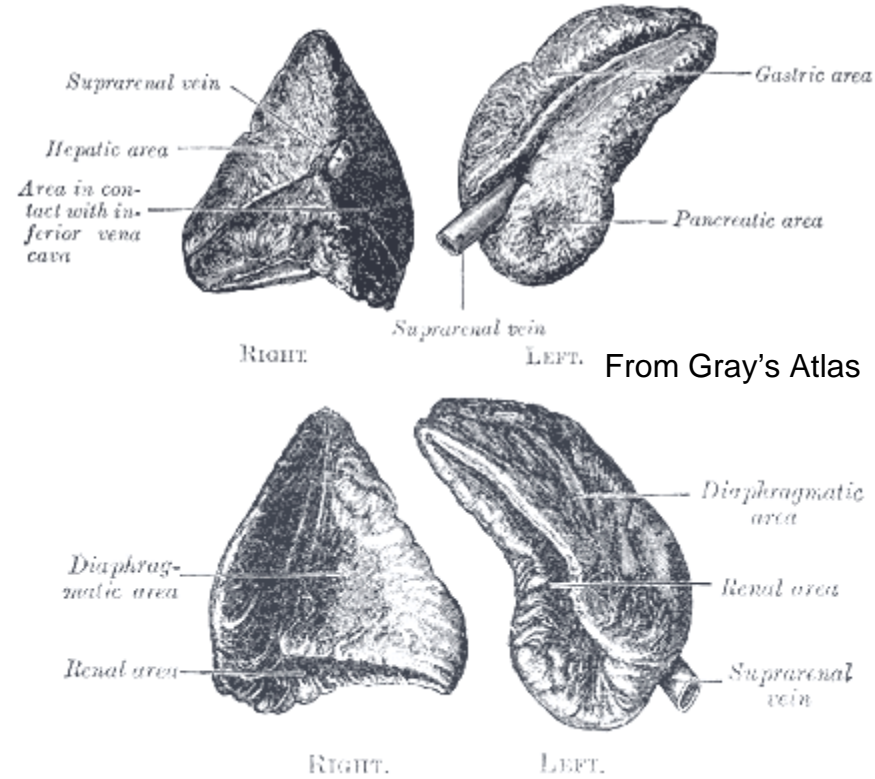
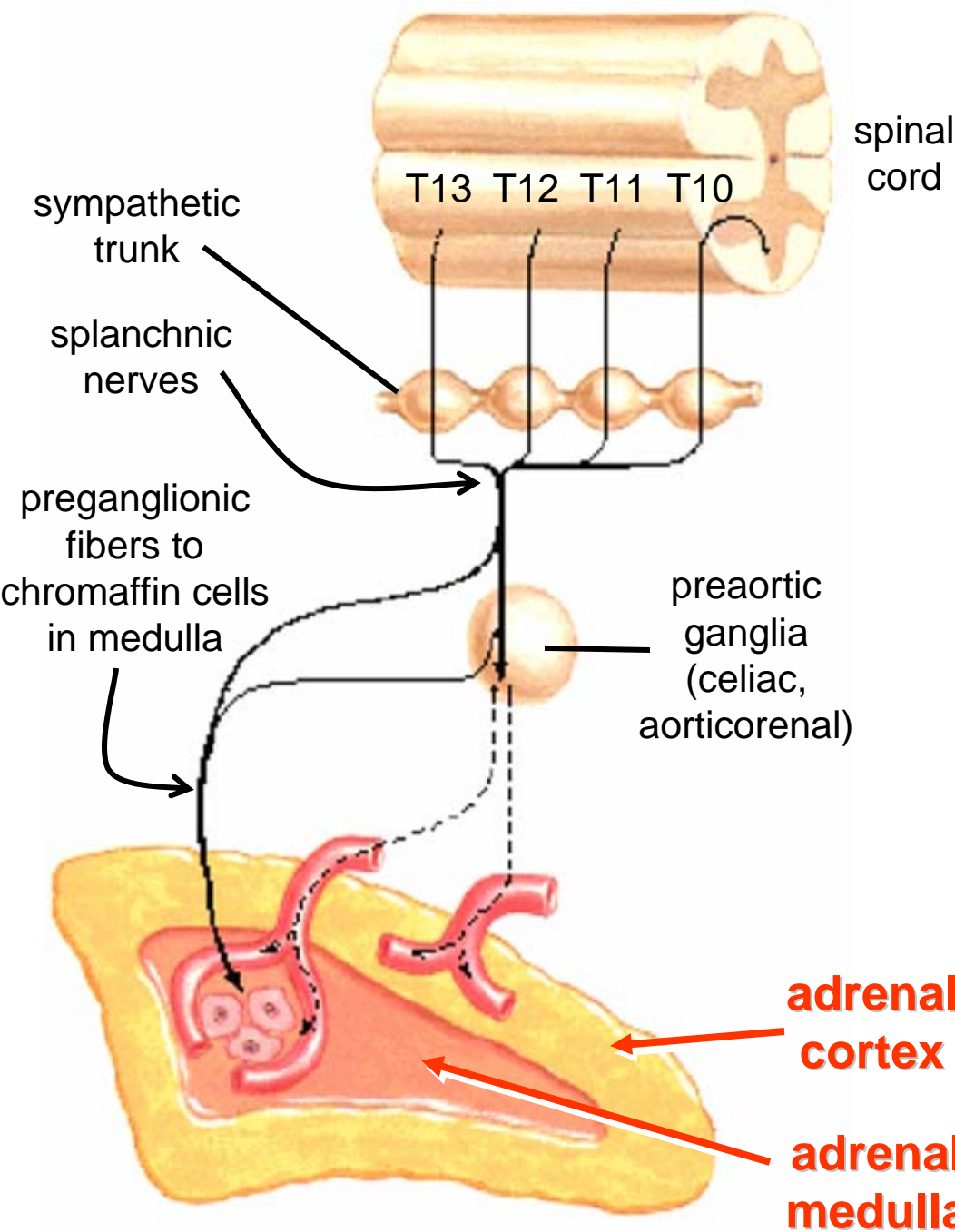


Possible Locations of Thyroglossal Duct Cysts



From Moore & Persaud 2003

Adrenal Overview



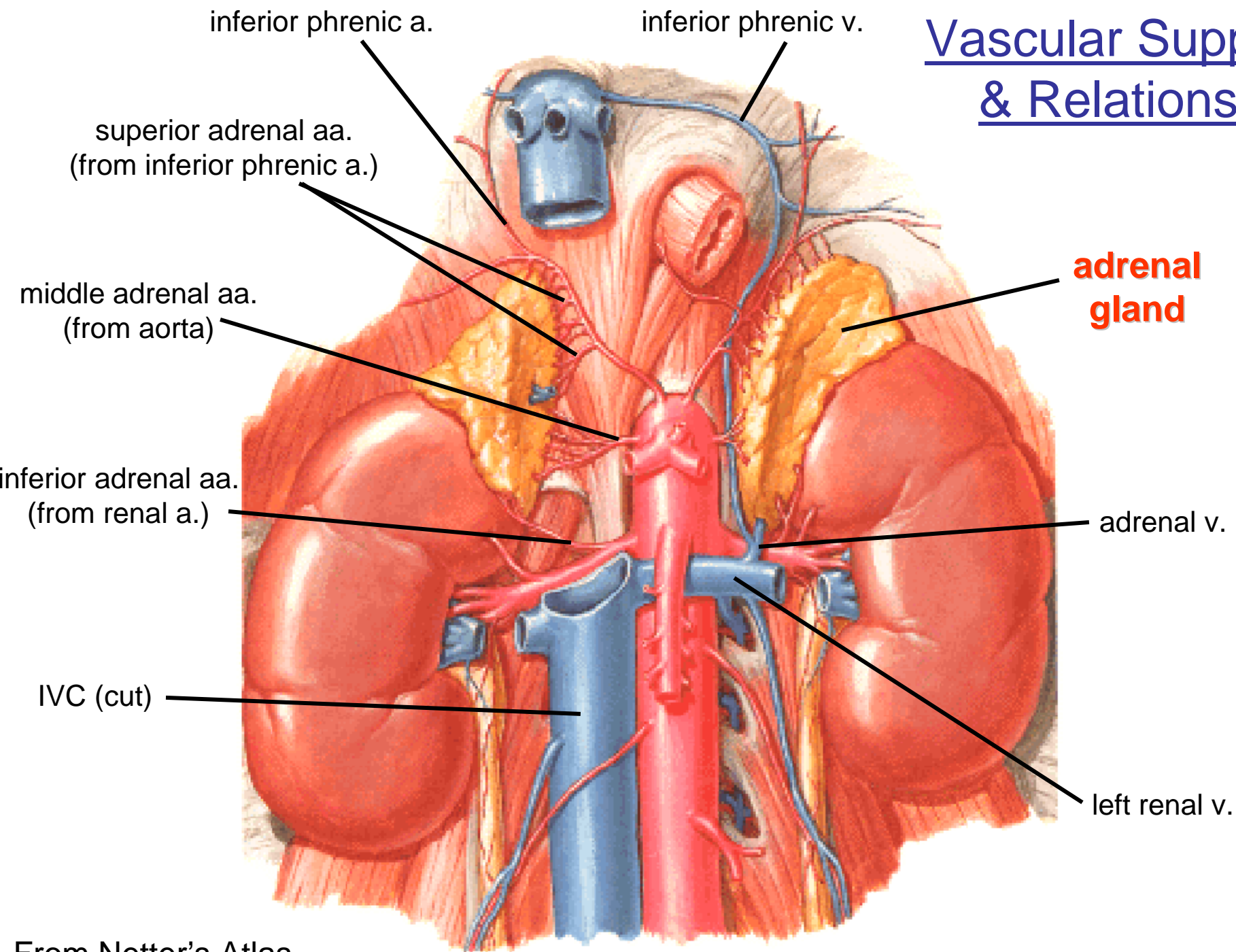
adrenal cortex

— corticosteroids, androgens

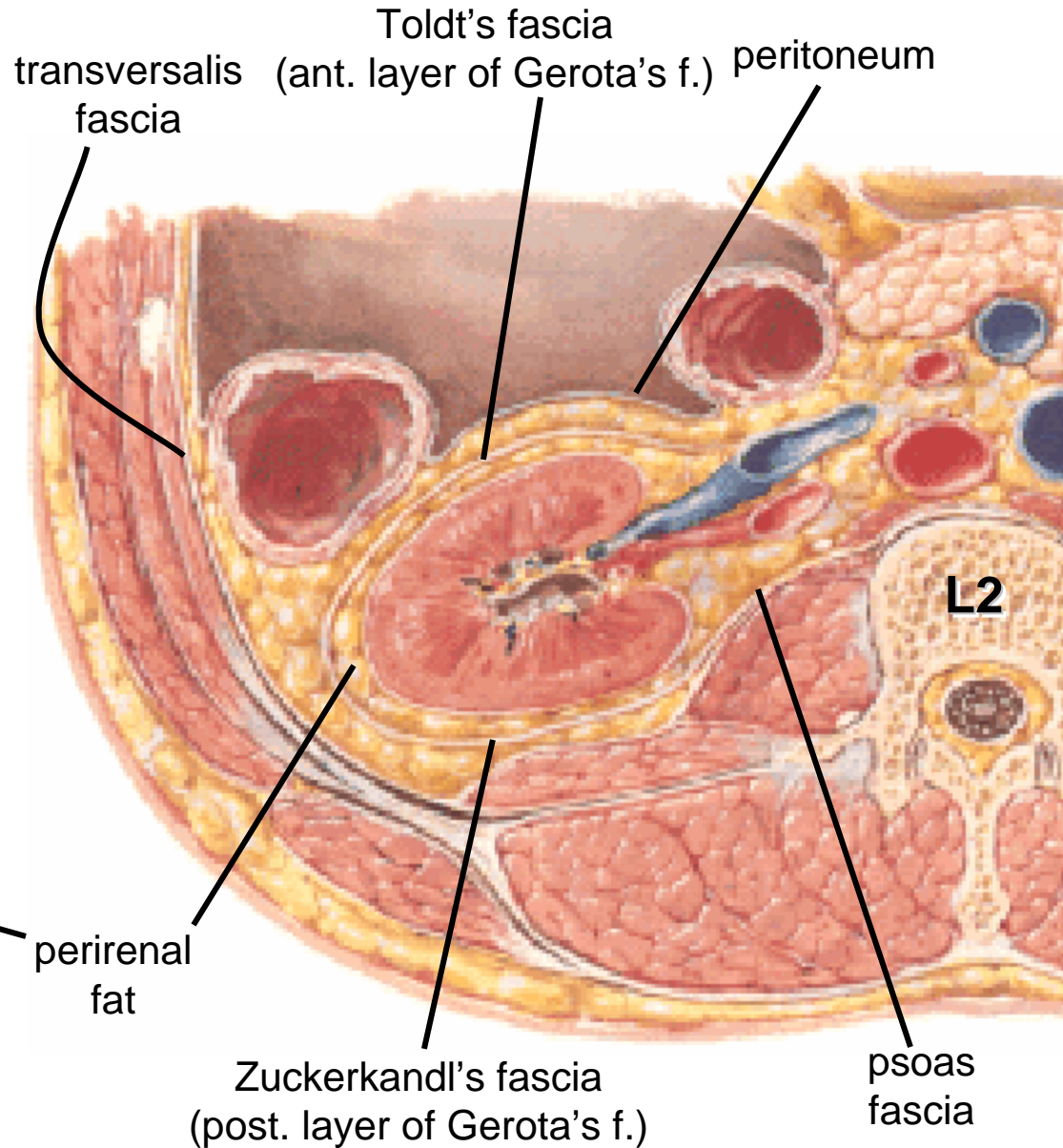
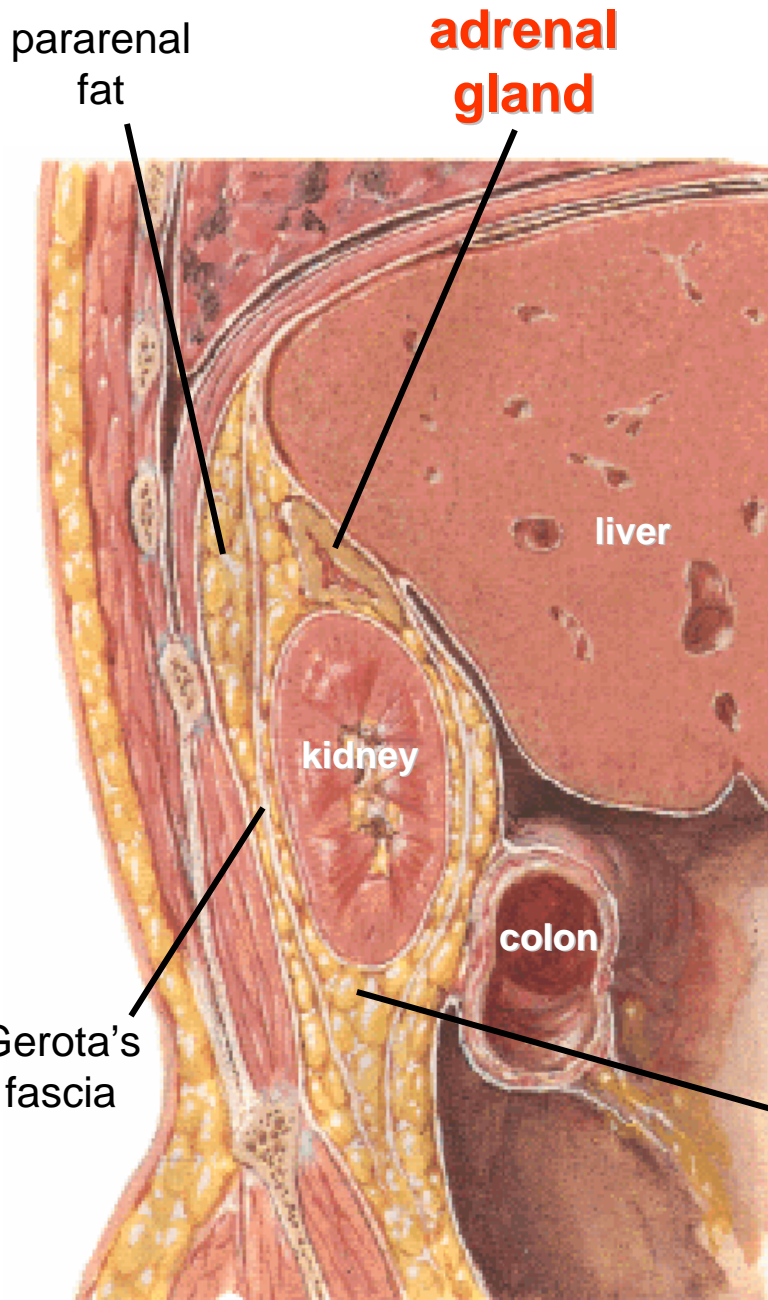
adrenal medulla

— catecholamines (esp. epinephrine)

Vascular Supply & Relations



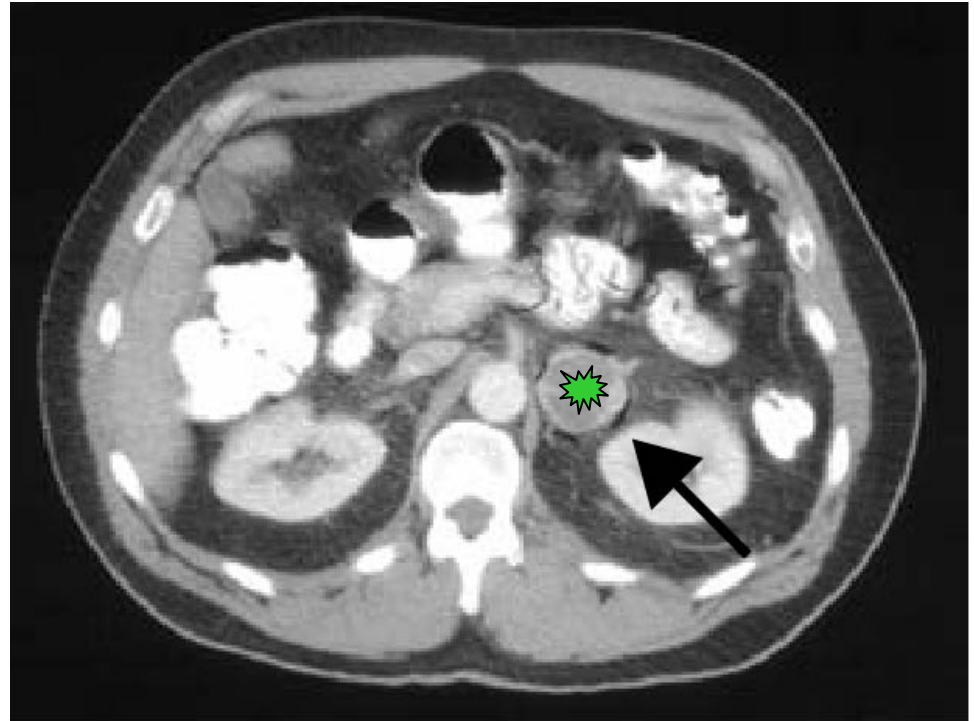
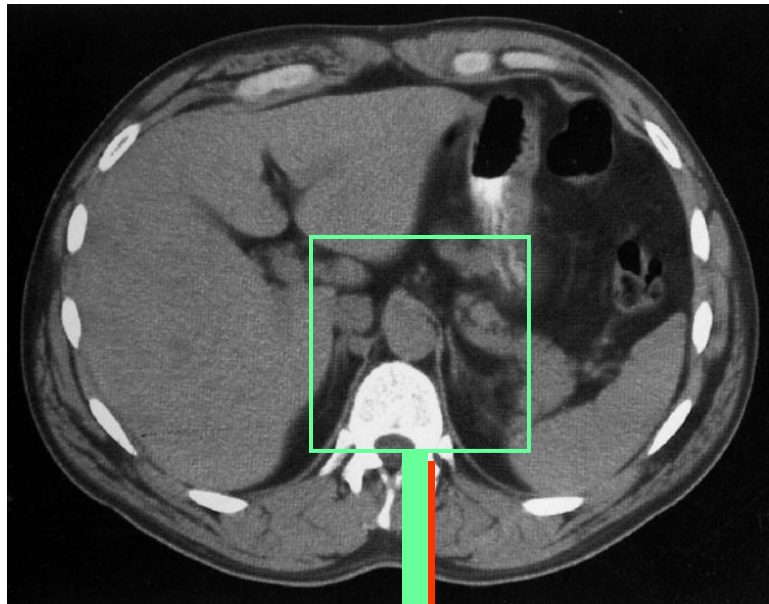
Perirenal fascia of Gerota



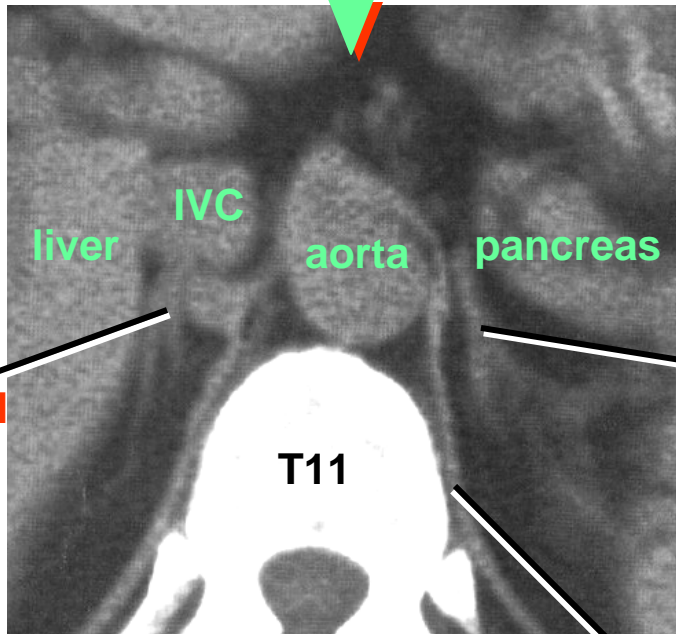
From Netter's Atlas

Imaging

Adrenal tumor



From web reference 3



right adrenal

left adrenal

T11

crus of diaphragm

From Ellis et al. 1991

References

Print

- Ellis, H., B. Logan, and A. Dixon. 1993. *Human Cross-Sectional Anatomy: Atlas of Body Sections and CT Images*. Butterworth-Heinemann, London.
- Hollinshead, W. H. 1968. *Anatomy for Surgeons: Volume 1. The Head and Neck, Second Edition*. Harper & Row, New York.
- Moore, K. L. and A. F. Dalley. 2006. *Clinically Oriented Anatomy*. Lippincott, Williams, & Wilkins, Baltimore.
- Moore, K. L. and T. V. N. Persaud. 2003. *The Developing Human: Clinically Oriented Embryology*. Saunders, Philadelphia.
- Netter, F. H. 1987. *The CIBA Collection of Medical Illustrations, Volume 8: Musculoskeletal System*. CIBA-Geigy, Summit.
- . 1997. *Atlas of Human Anatomy, 2nd. Ed.* Novartis, East Hanover.
- Sasou, S., S. Nakamura, and H. Kurihara. 1998. Suspensory ligament of Berry: its relationship to recurrent laryngeal nerve and anatomic examination of 24 autopsies. *Head & Neck* 20:695–698.
- Skandalakis, J. E., G. L. Colborn, T. A. Weidman, R. S. Foster, A. N. Kingsnorth, L. J. Skandalakis, N. P. Skandalakis, P. Mirilas (Editors). 2004. *Surgical Anatomy: The Embryologic And Anatomic Basis Of Modern Surgery*. McGraw-Hill, New York.
- Younes, N. A., and D. H. Badran. 2002. The cricothyroid space: a guide for successful thyroidectomy. *Asian Journal of Surgery* 25(3):226–231.

Web

1. Thyroid tumor: <http://www.auntminnie.com/ScottWilliamsMD2/nucmed/Tumor/Thallium/Thallium.htm>
2. Adrenal surgery: <http://www.emedicine.com/med/topic3018.htm>
3. Adrenal surgery: <http://www.surgery.wisc.edu/general/patients/endocrine.shtml>
4. Gray's *Anatomy of the Human Body*: <http://www.bartleby.com/107/>