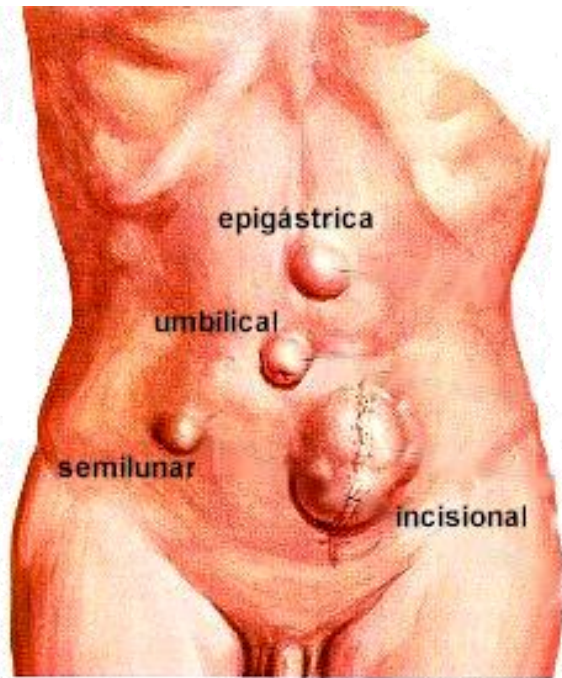


Clinical Anatomy of the Anterior Abdominal Wall in its Relation to Hernia

Handout download:

<http://www.oucom.ohiou.edu/dbms-witmer/gs-rpac.htm>



Lawrence M. Witmer, PhD

Professor of Anatomy

Department of Biomedical Sciences

College of Osteopathic Medicine

Ohio University, Athens

witmerL@ohio.edu

26 April 2011



CENTERS FOR OSTEOPATHIC RESEARCH AND EDUCATION

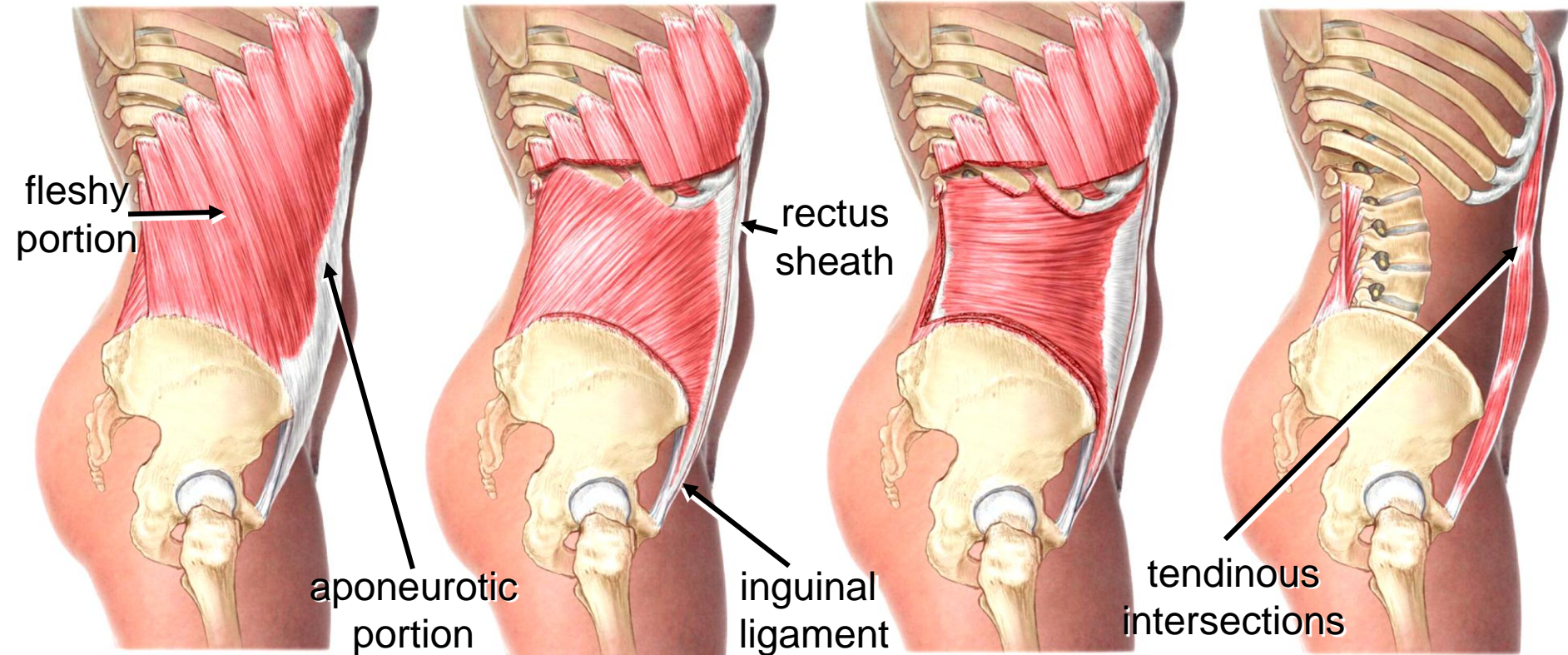
Anatomical Overview

External oblique

Internal oblique

Transversus abdominis

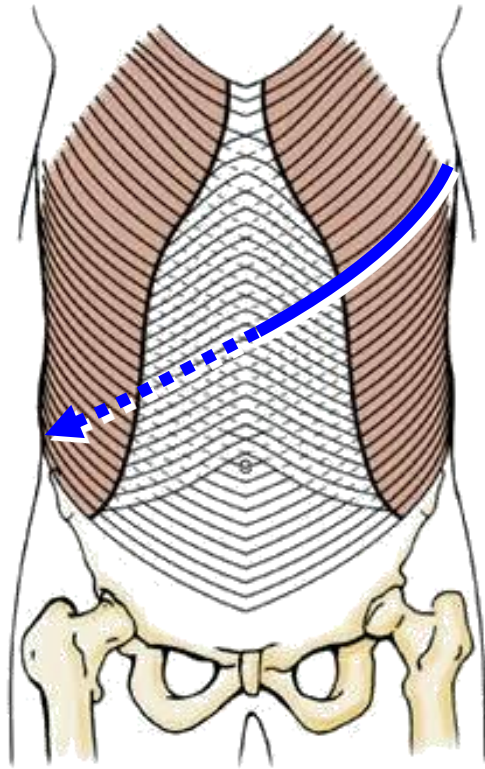
Rectus abdominis



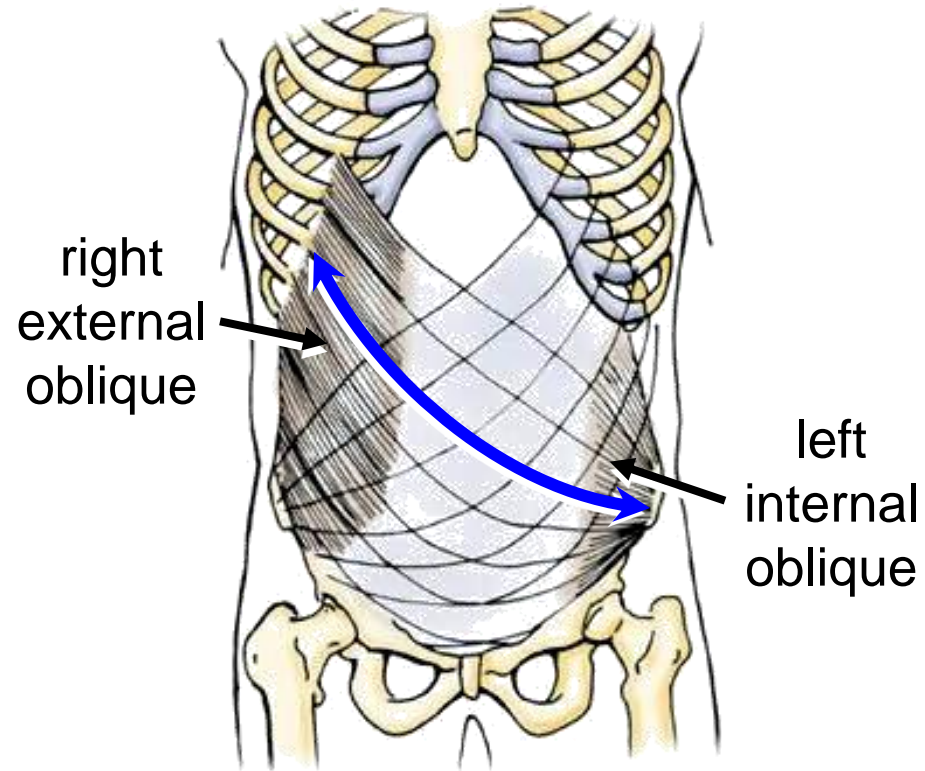
- Three flat abdominals: attach to trunk skeleton, inguinal lig., linea alba, etc.; fleshy laterally and aponeurotic medially, forming rectus sheath medially
- Two vertical abdominals: rectus abdominis and pyramidalis (not shown)

Anatomical Overview

intramuscular exchange of contralateral external oblique fibers



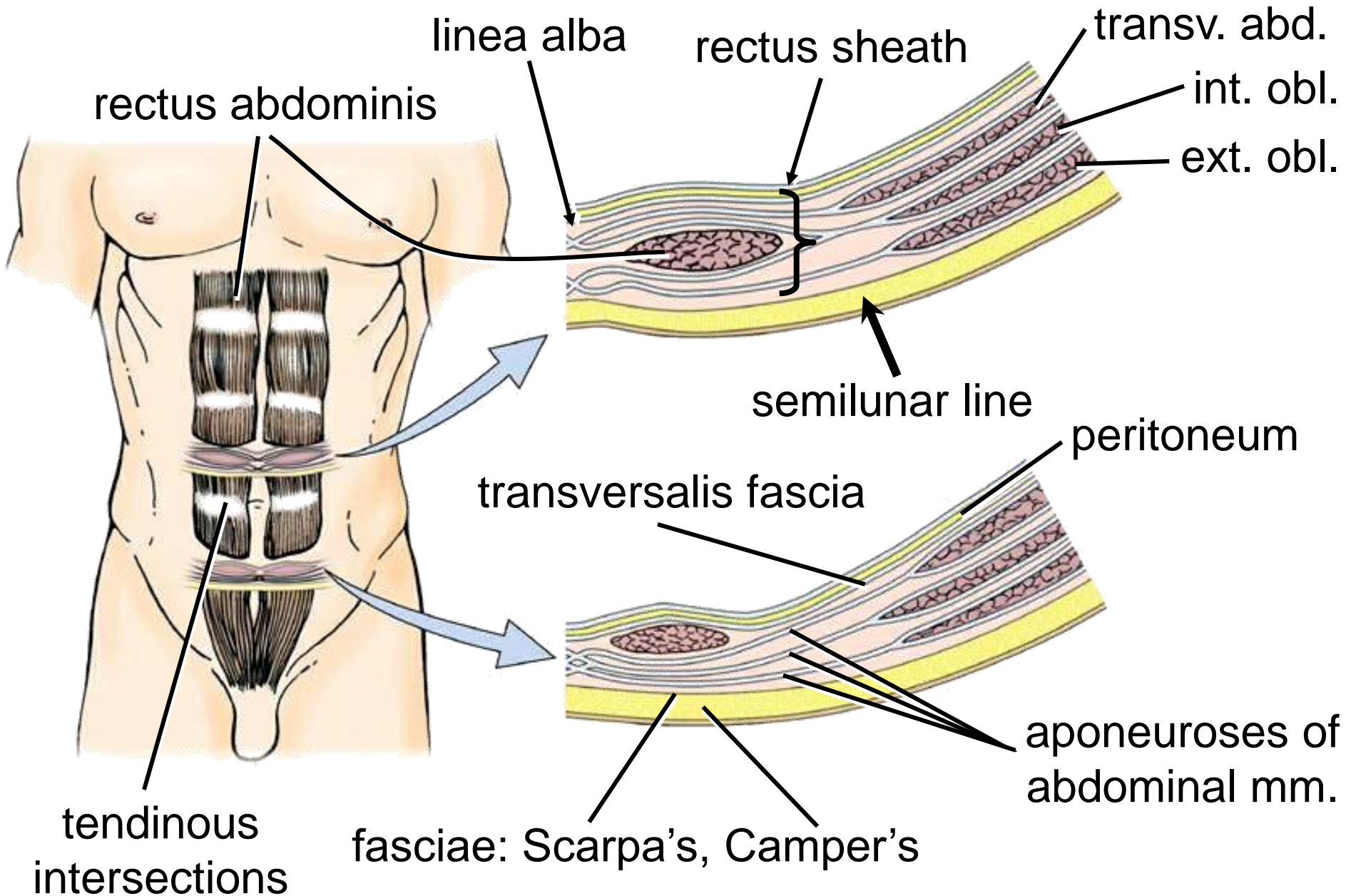
intermuscular exchange of contralateral external & internal oblique



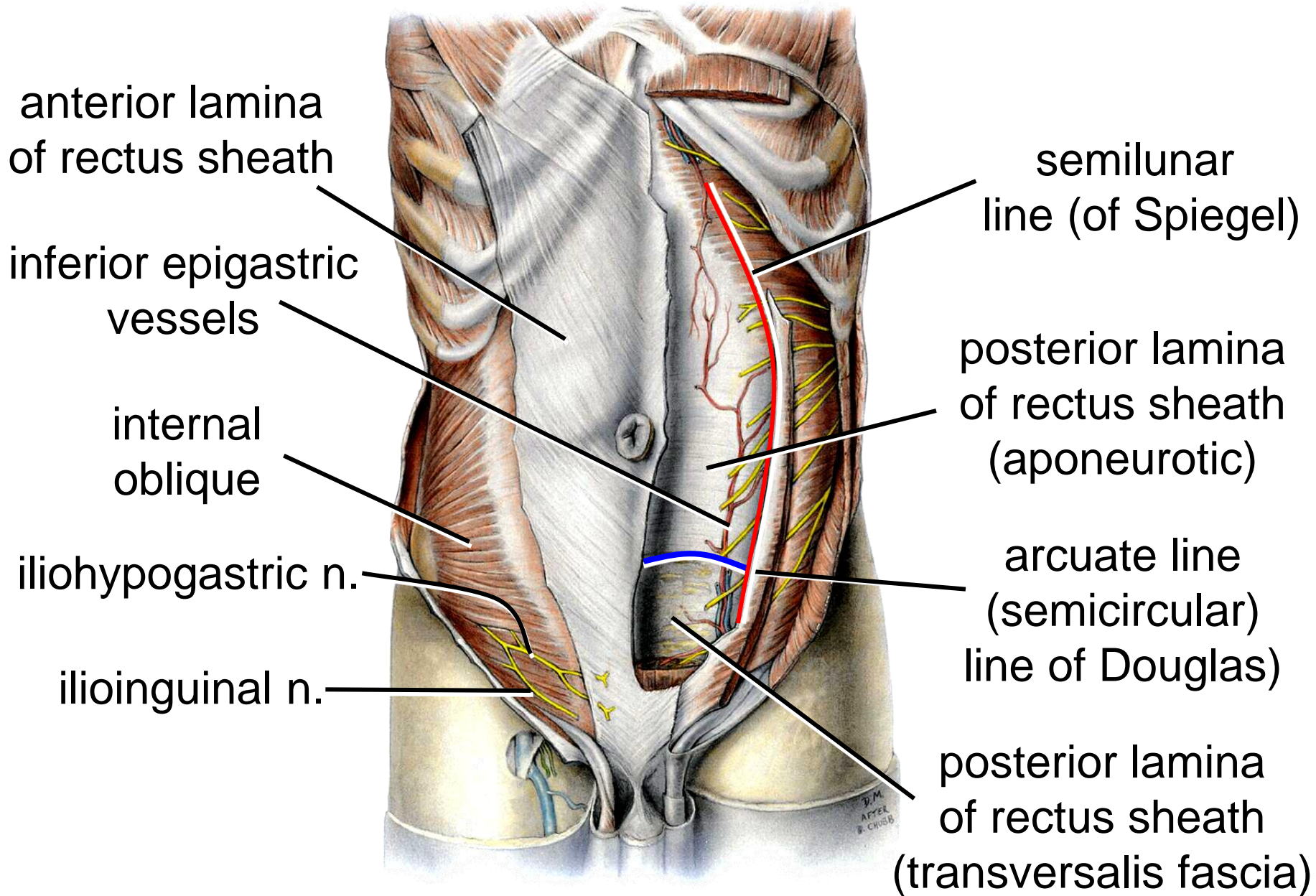
- continuity of external oblique fibers across midline
- blending of superficial & deep fibers on opposite side

- continuity of fibers across midline
- “digastric” muscle with central tendon
- torsion of trunk

Anatomical Overview

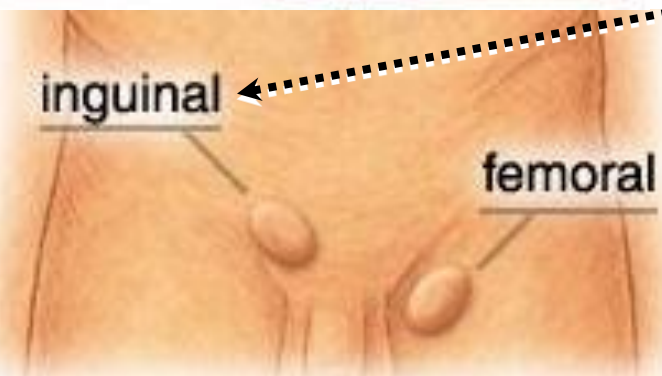
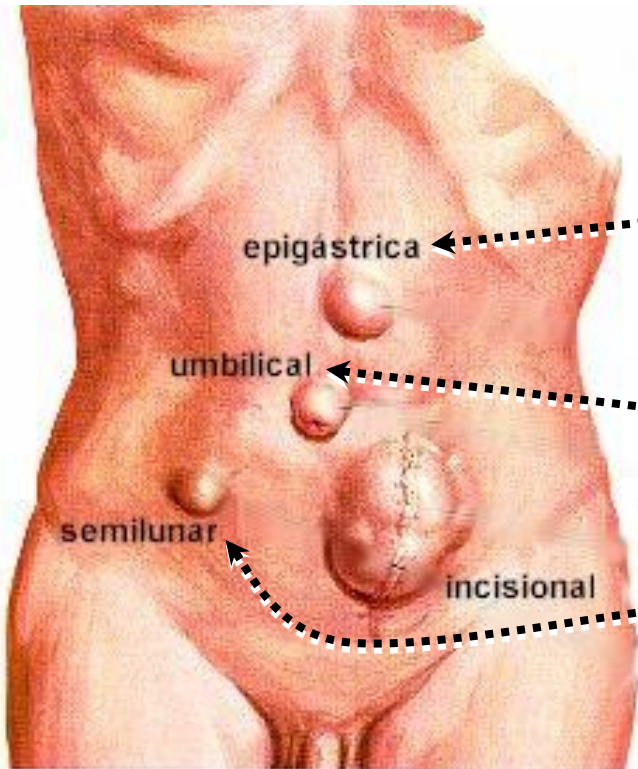


Anatomical Overview



Anatomical Overview

Anterior Abdominal Hernias



rectus sheath

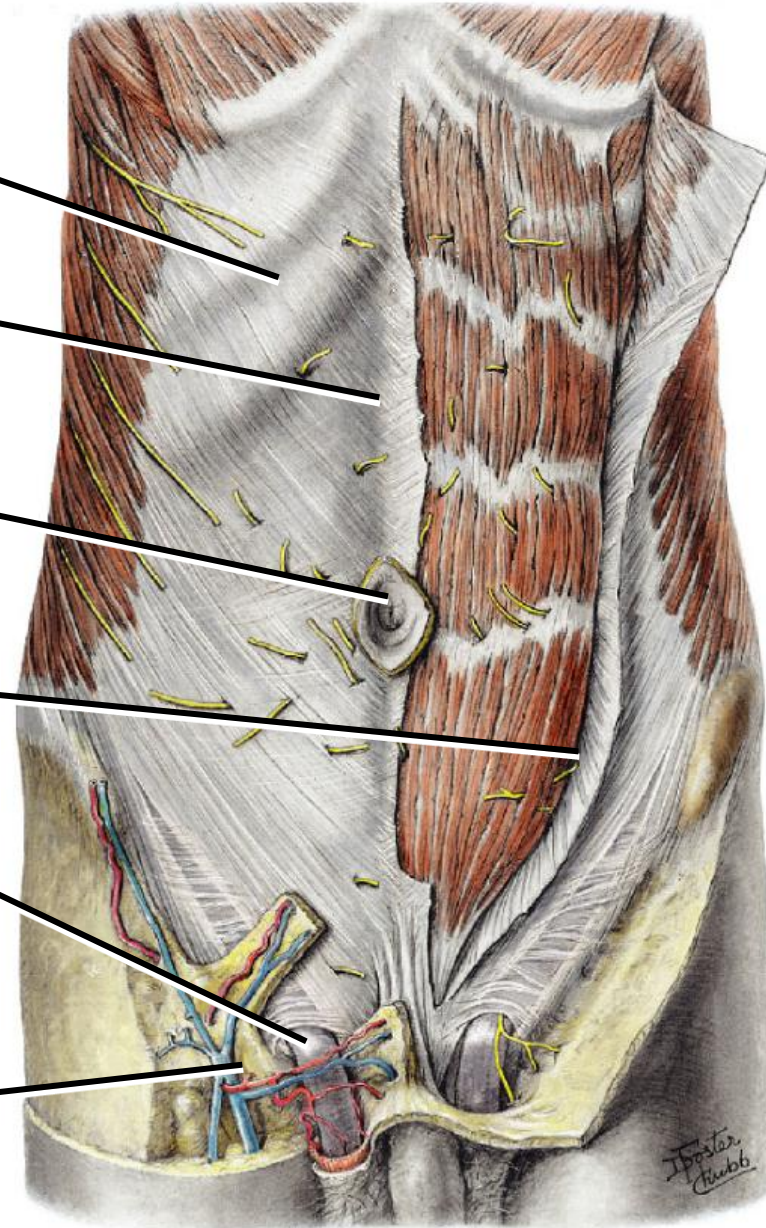
linea alba

umbilicus

semilunar line

superficial
inguinal ring

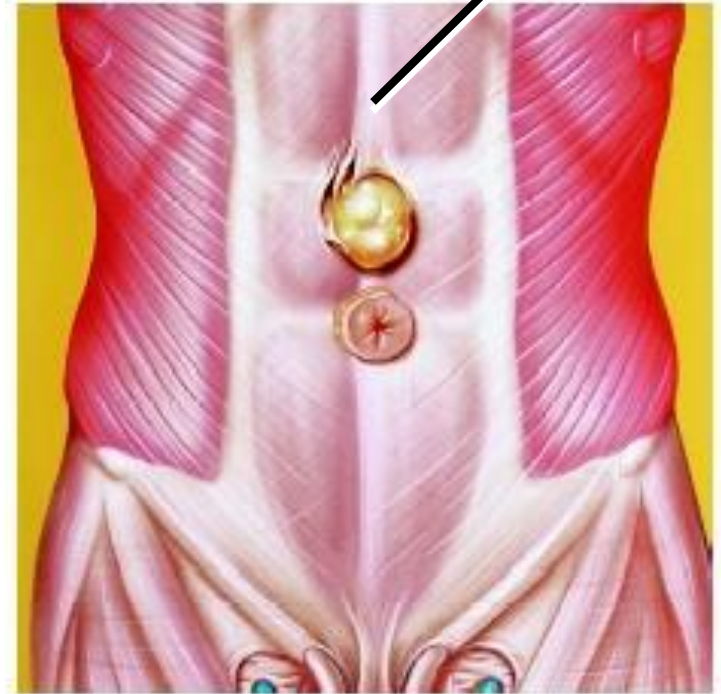
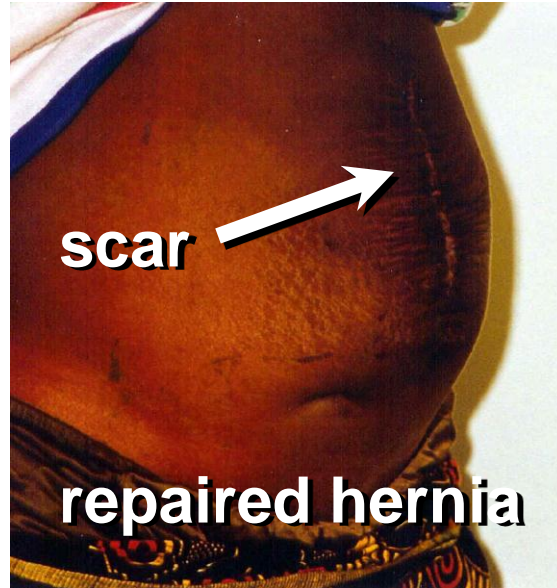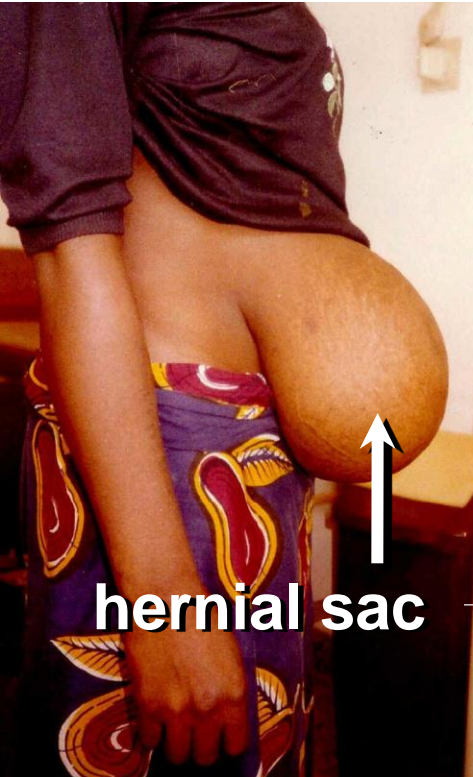femoral
canal



Epigastric (Ventral) Hernia

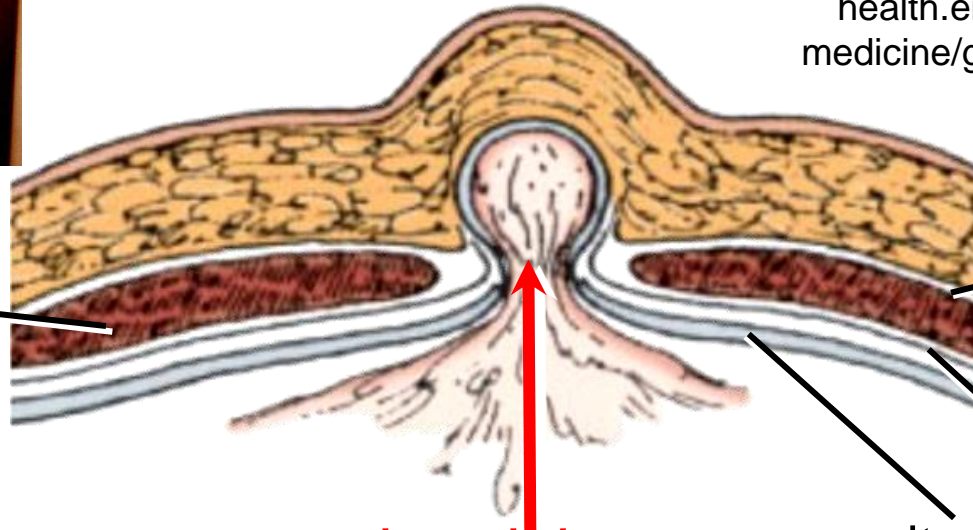
linea alba

thachers.org/images/epigastric_hernia.jpg
thachers.org/images/hernia_repair.jpg



health.enotes.com/images/medicine/gem_03_img0340.jpg

rectus abdominis



anterior rectus sheath

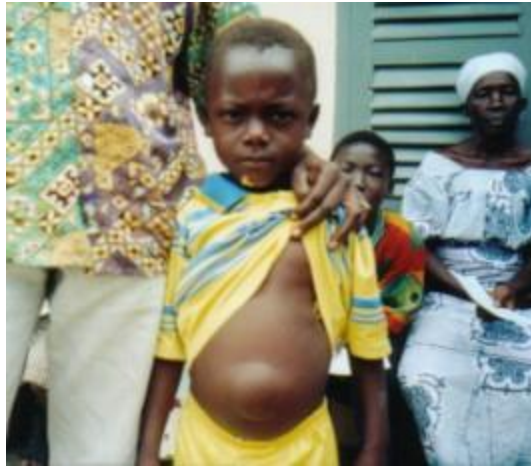posterior rectus sheath

peritoneum

hernial sac

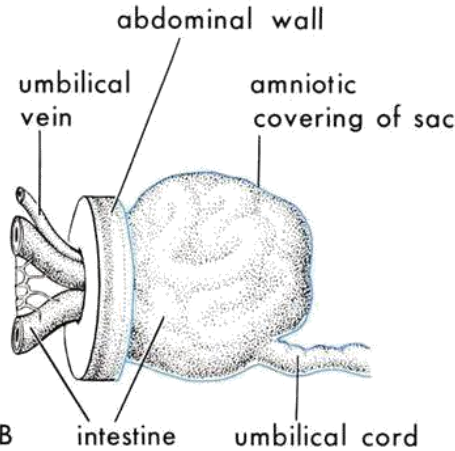
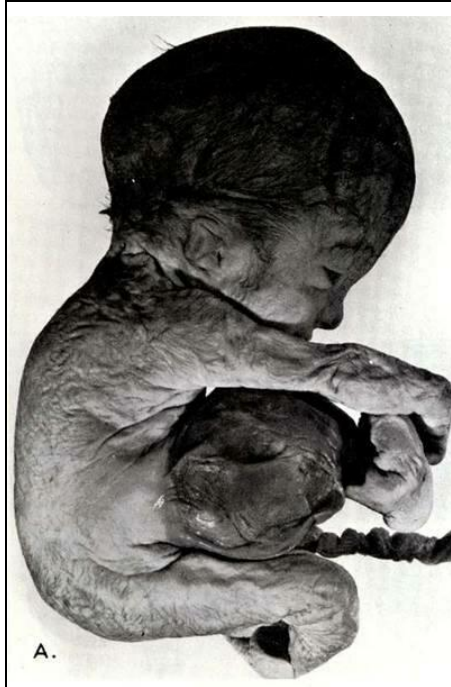Umbilical (Para-umbilical) Hernia

Congenital Umbilical Hernia



- incomplete closure of umbilical ring

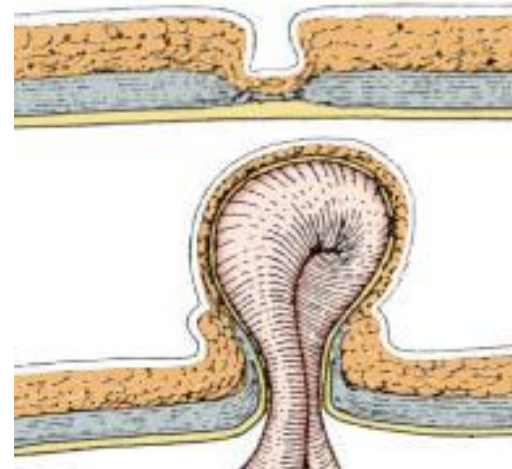
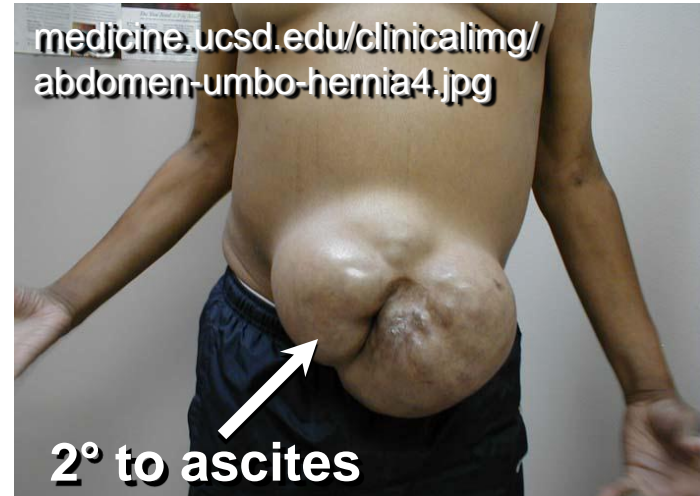Omphalocele



1988 Moore *Developing Human 4th edition*

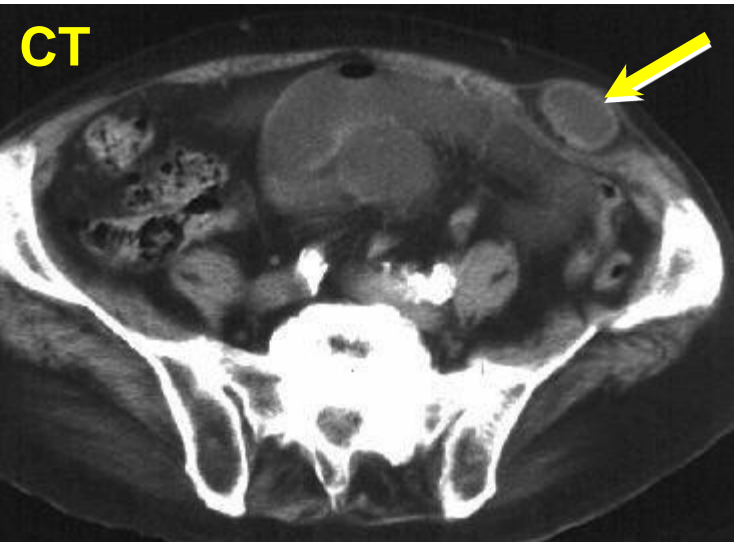Acquired Umbilical Hernia

- occur after closure of umbilical ring
- 2° to obesity, pregnancy, cirrhosis, ascites, masses

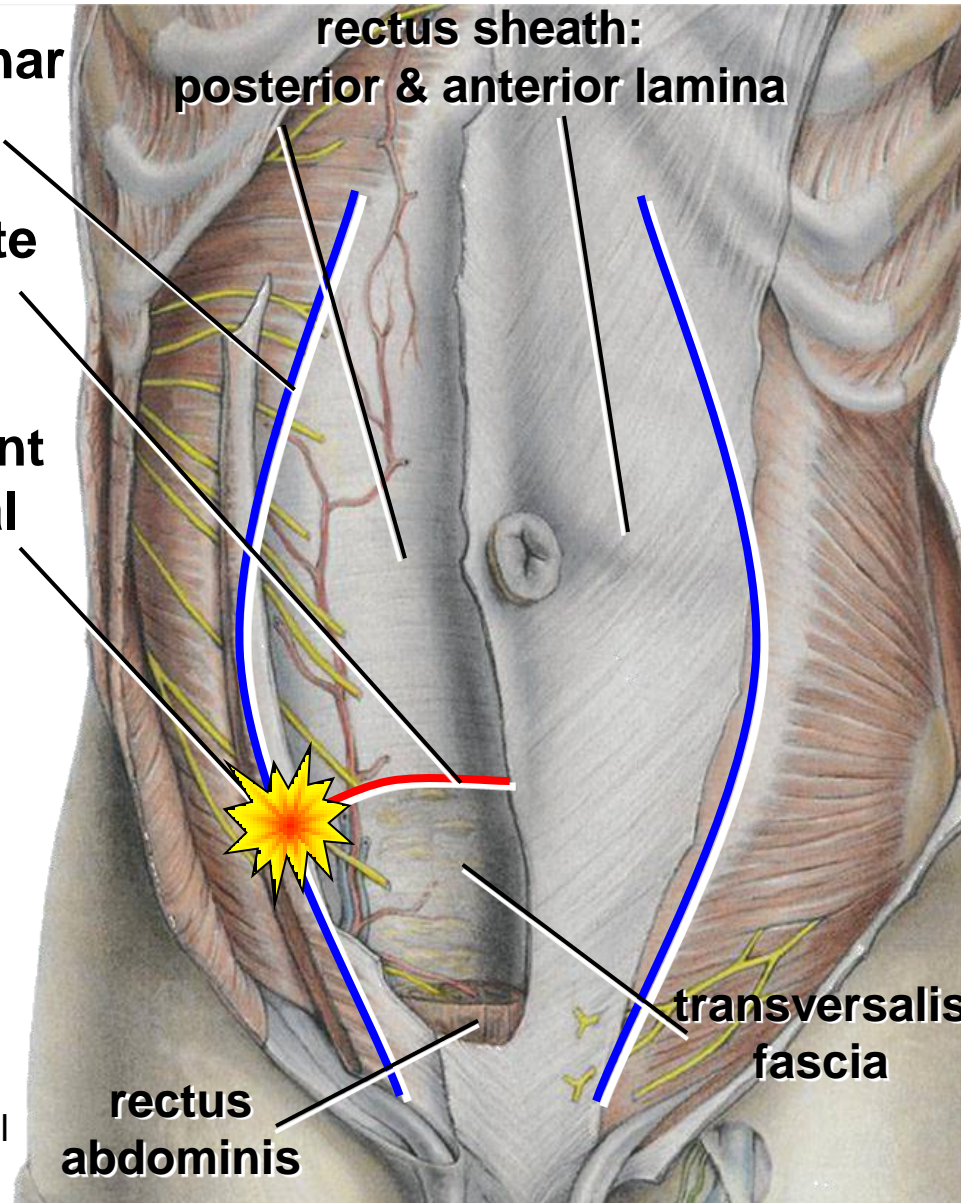


Skandalakis' Surgical Anatomy 2004

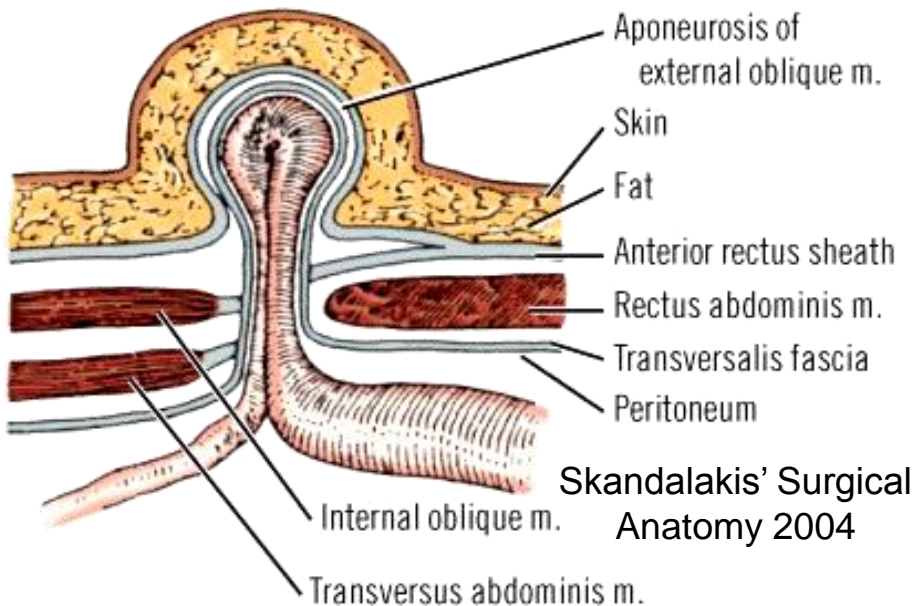
Spigelian (Lateral Ventral) Hernia



semilunar line
 arcuate line
 frequent hernial site

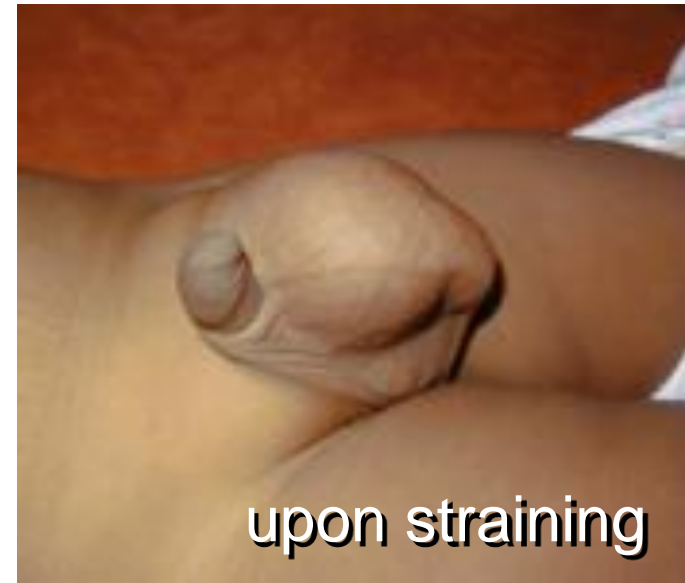
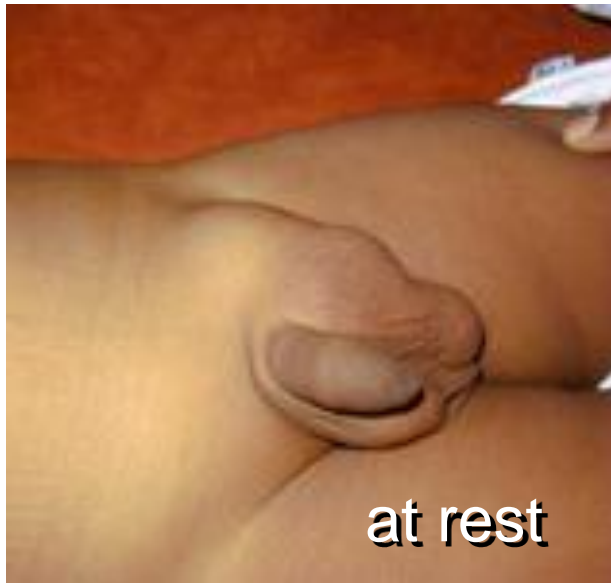
www.e-radiography.net/ibase5/Abdomen/slides/Abdomen_spigelian_hernia_ct.jpg



Case Presentation

A 3-year-old boy presents with a walnut-sized bulge in his left groin, particularly when he stands, strains, or cries. With the patient horizontal, the lump disappears. When the skin of the scrotum is invaginated by a little finger, a definite impact is felt on coughing. The diagnosis of hernia is made. How would this hernia be best characterized?

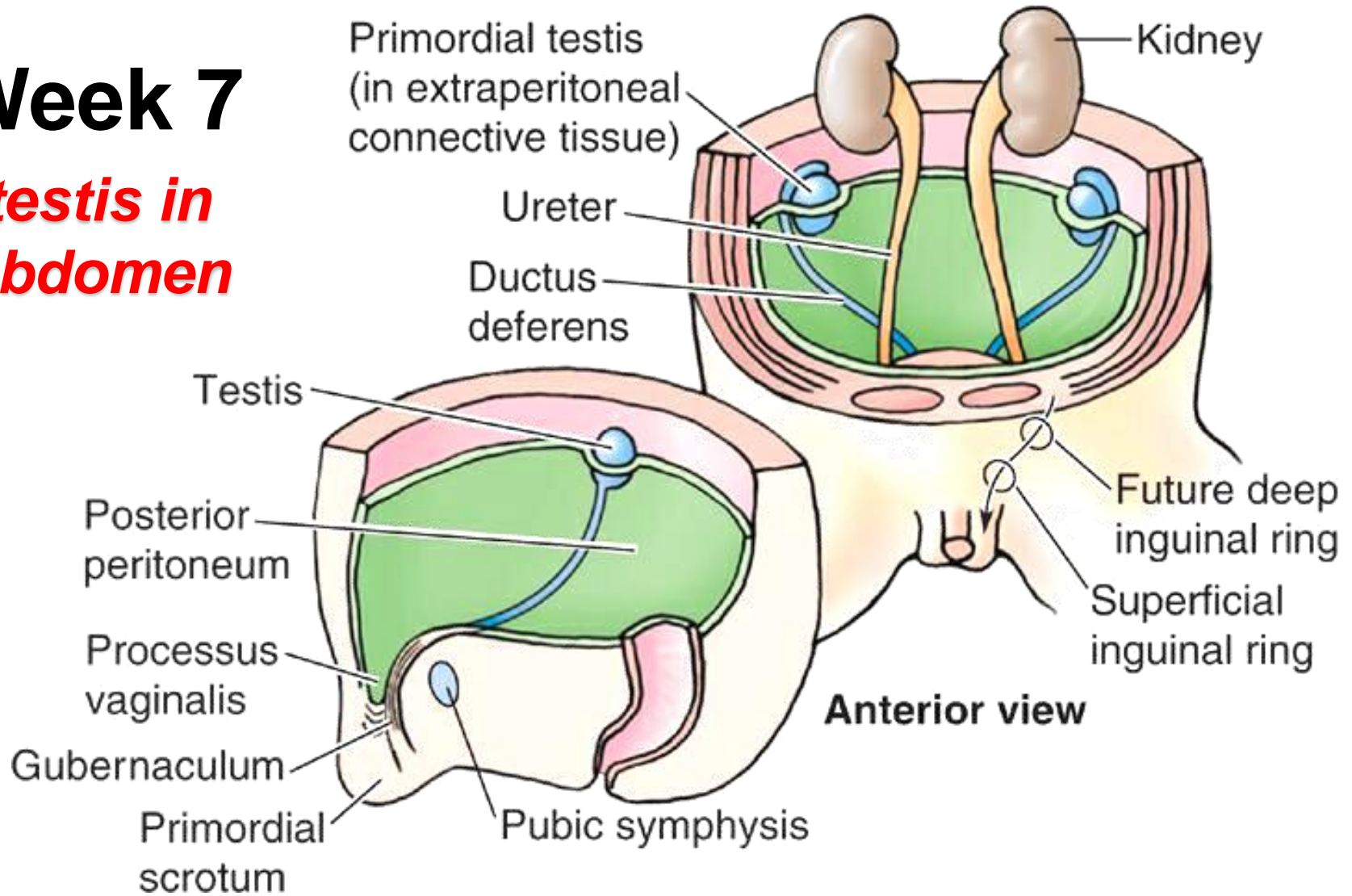


reducible, congenital, indirect inguinal hernia

Embryological Basis of Indirect Inguinal hernia

Week 7

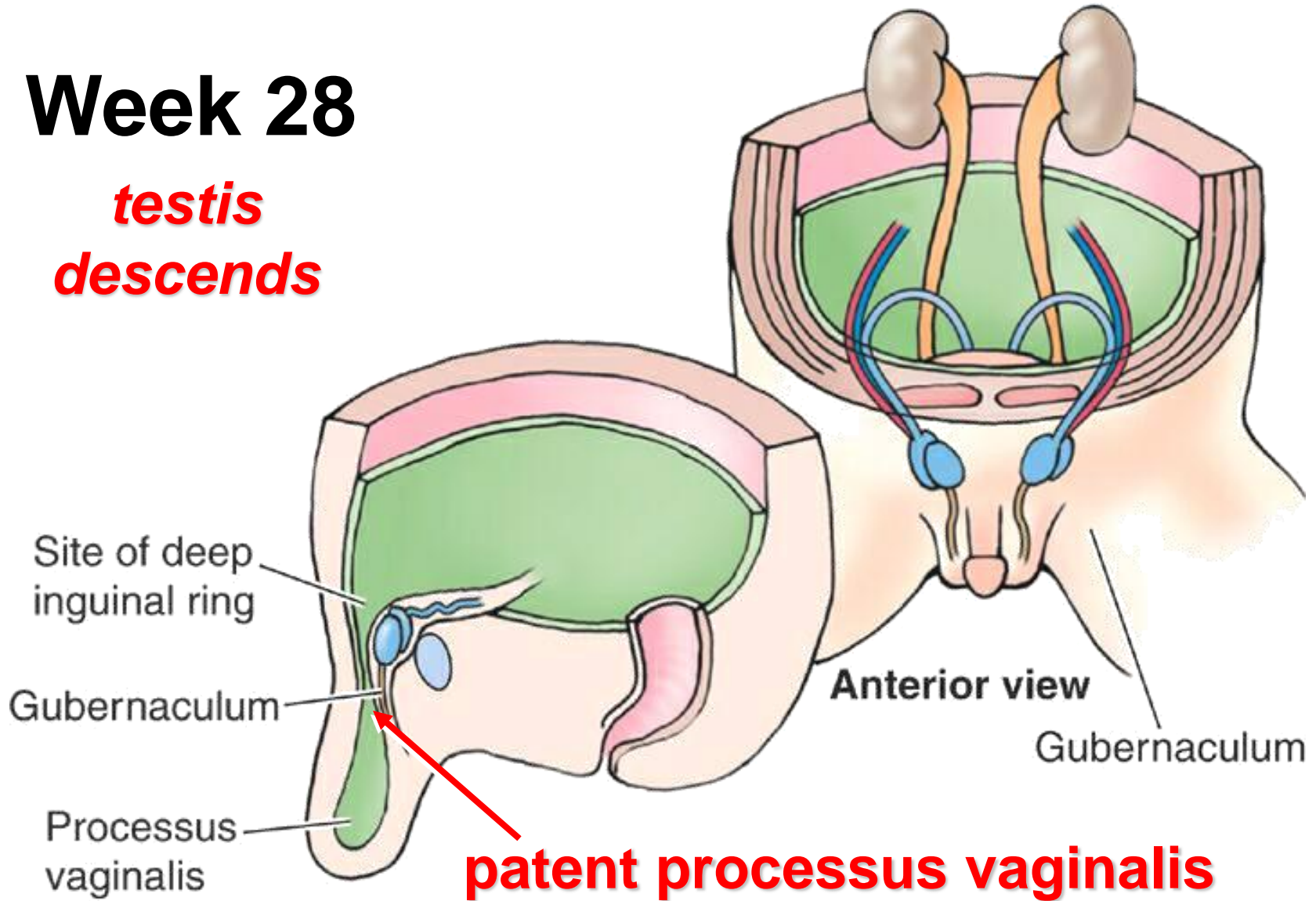
testis in abdomen



Embryological Basis of Indirect Inguinal hernia

Week 28

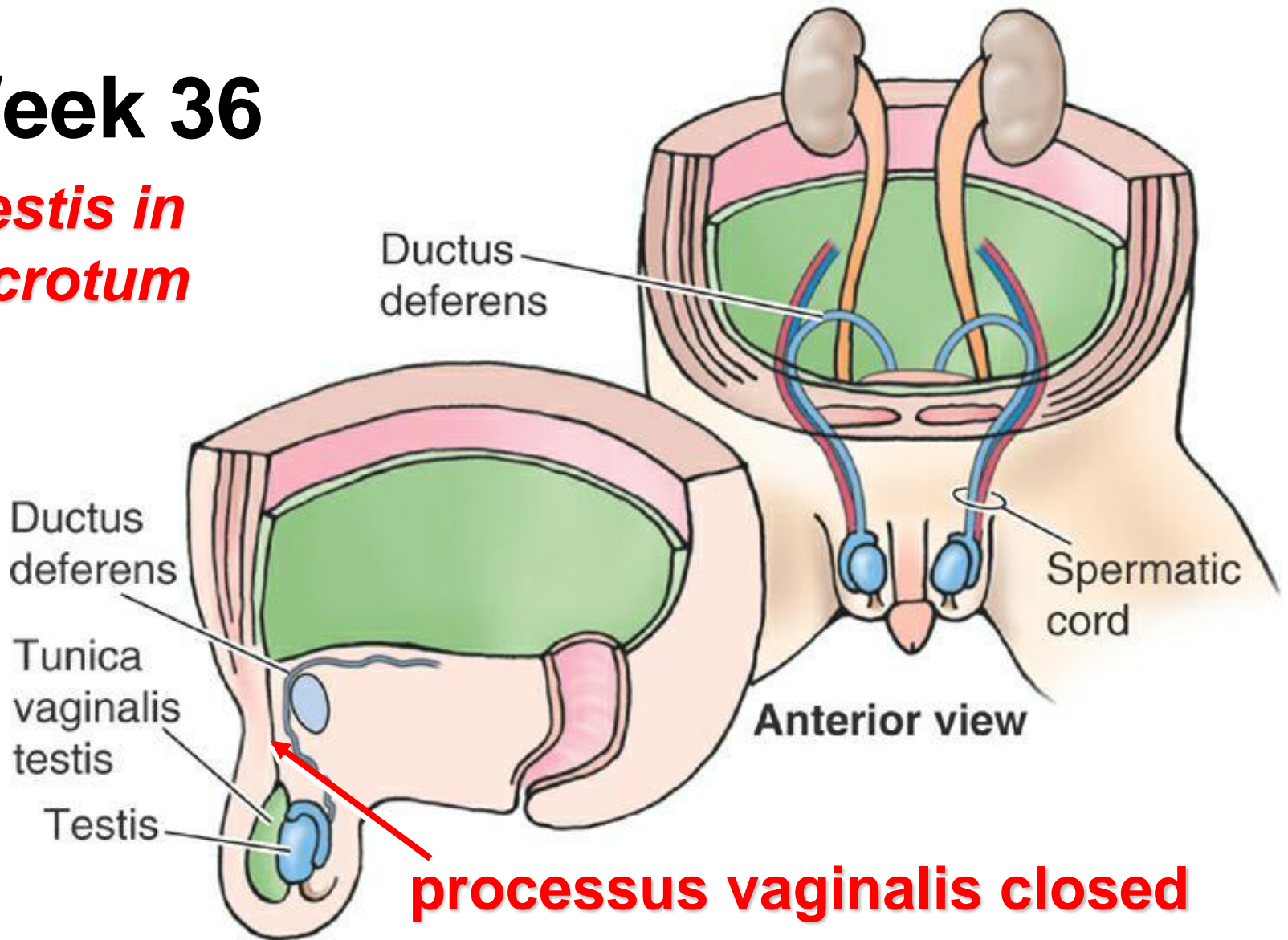
***testis
descends***



Embryological Basis of Indirect Inguinal hernia

Week 36

***testis in
scrotum***



Embryological Basis of Indirect Inguinal hernia

transversalis fascia
& peritoneum

abdominal
muscles

***partially
obliterated
processus
vaginalis***

tunica
vaginalis

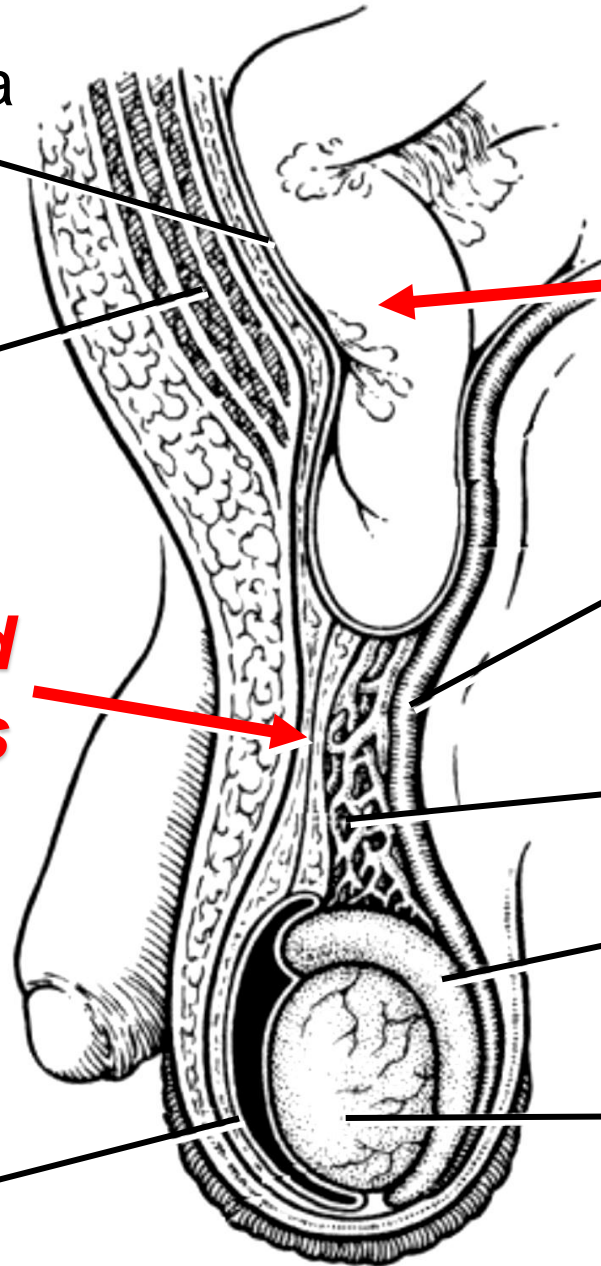
***hernial sac
within
spermatic
cord***

vas deferens

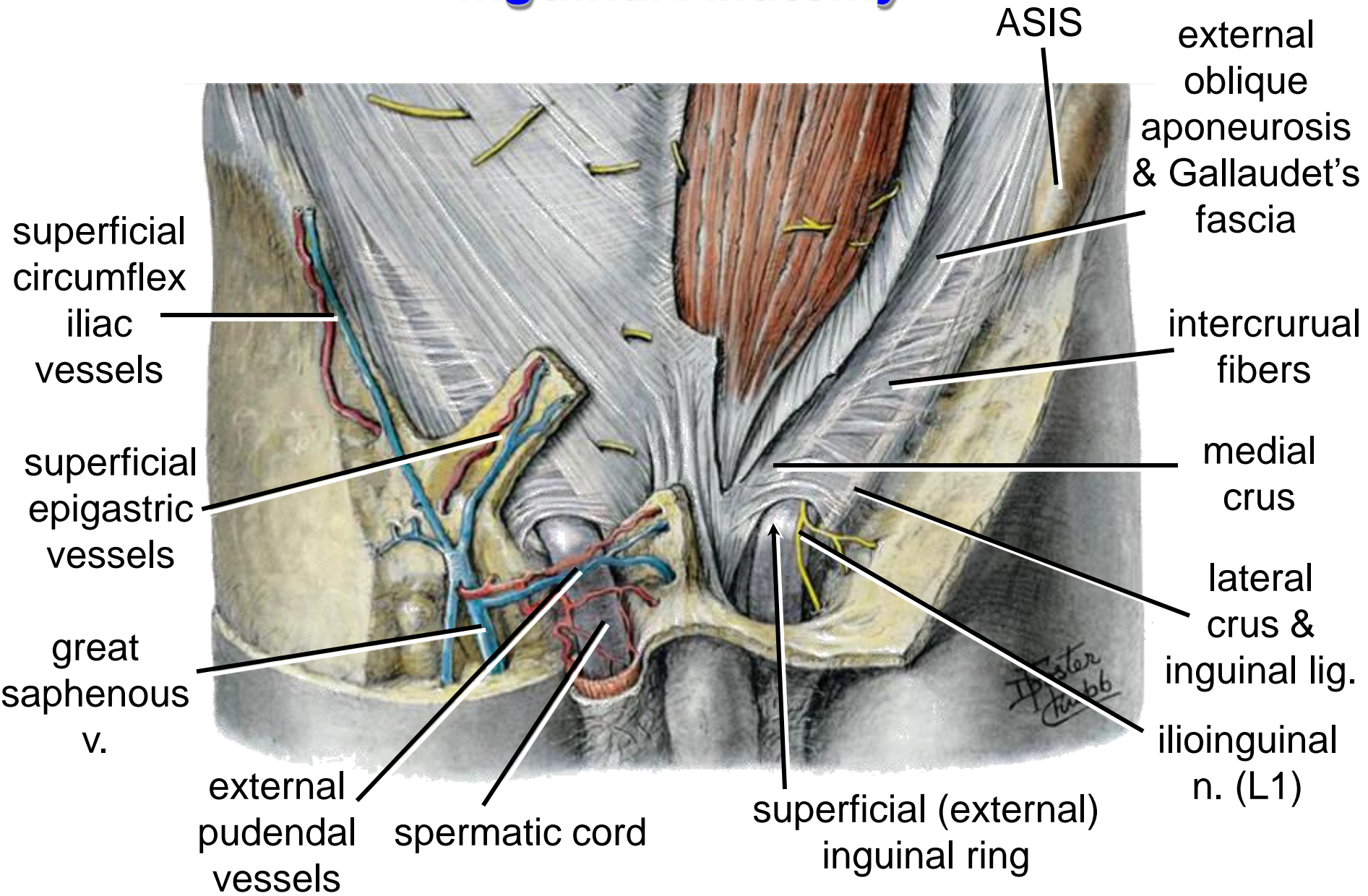
pampiniform
plexus

epididymis

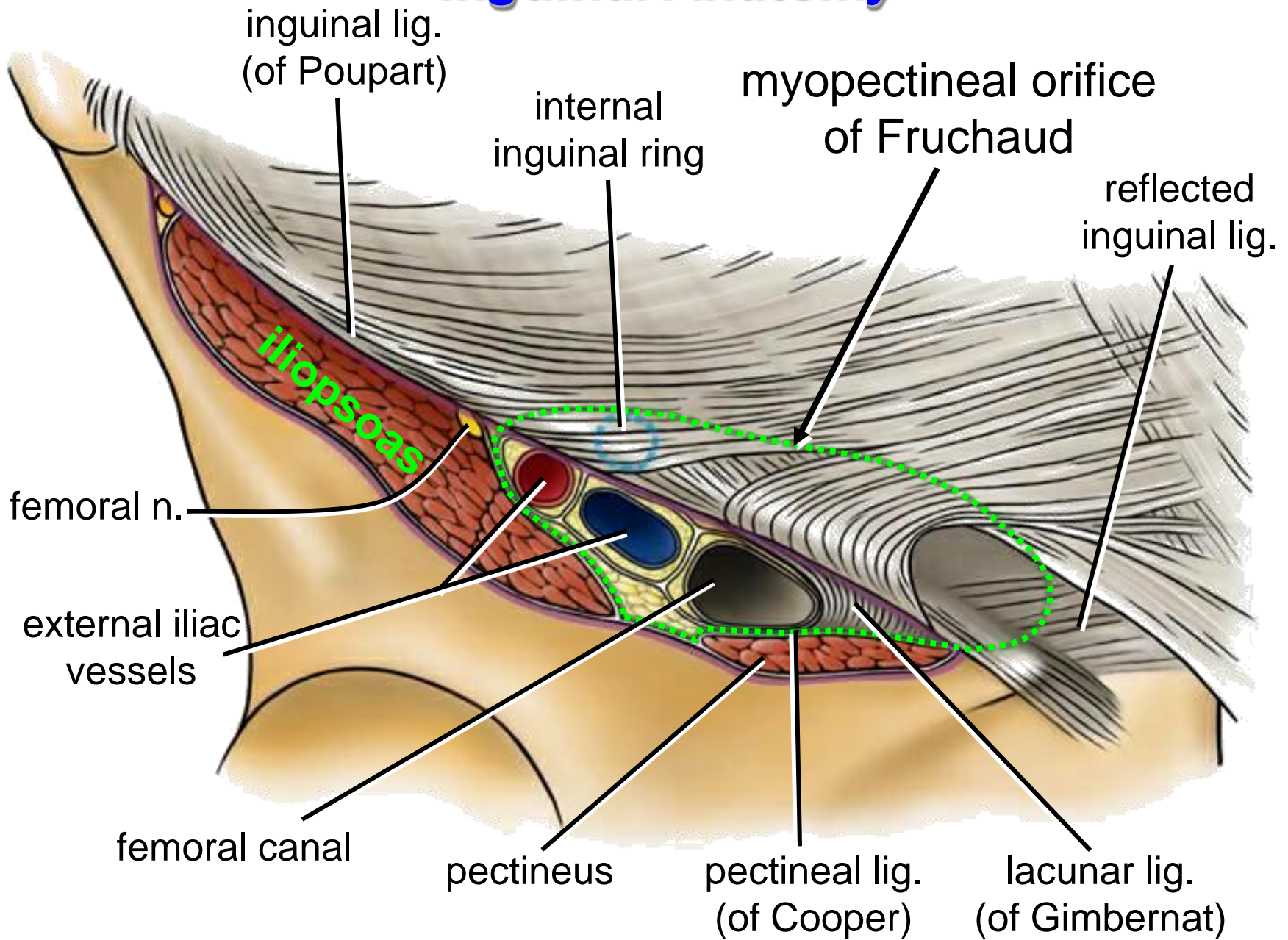
testis



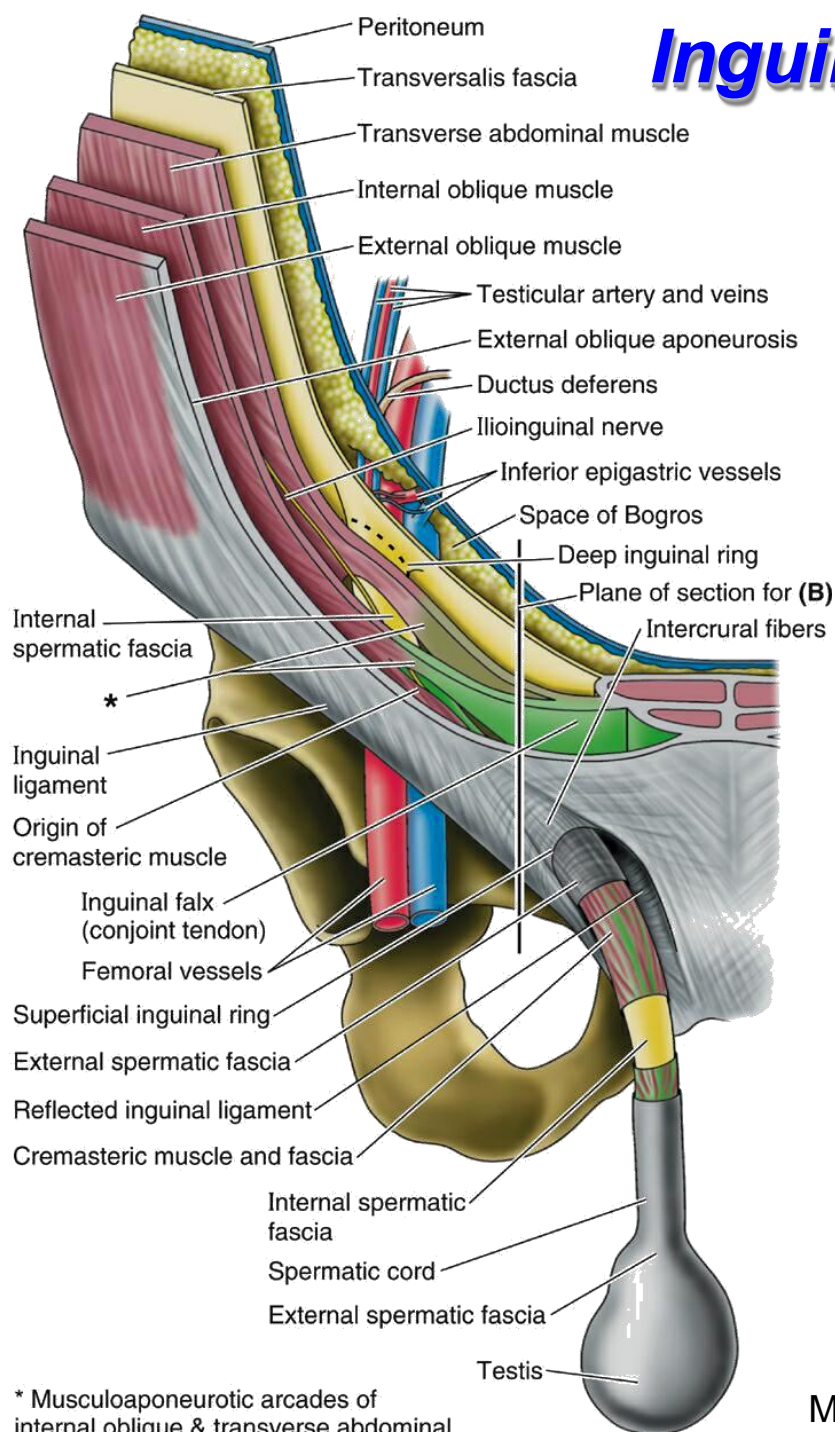
Inguinal Anatomy



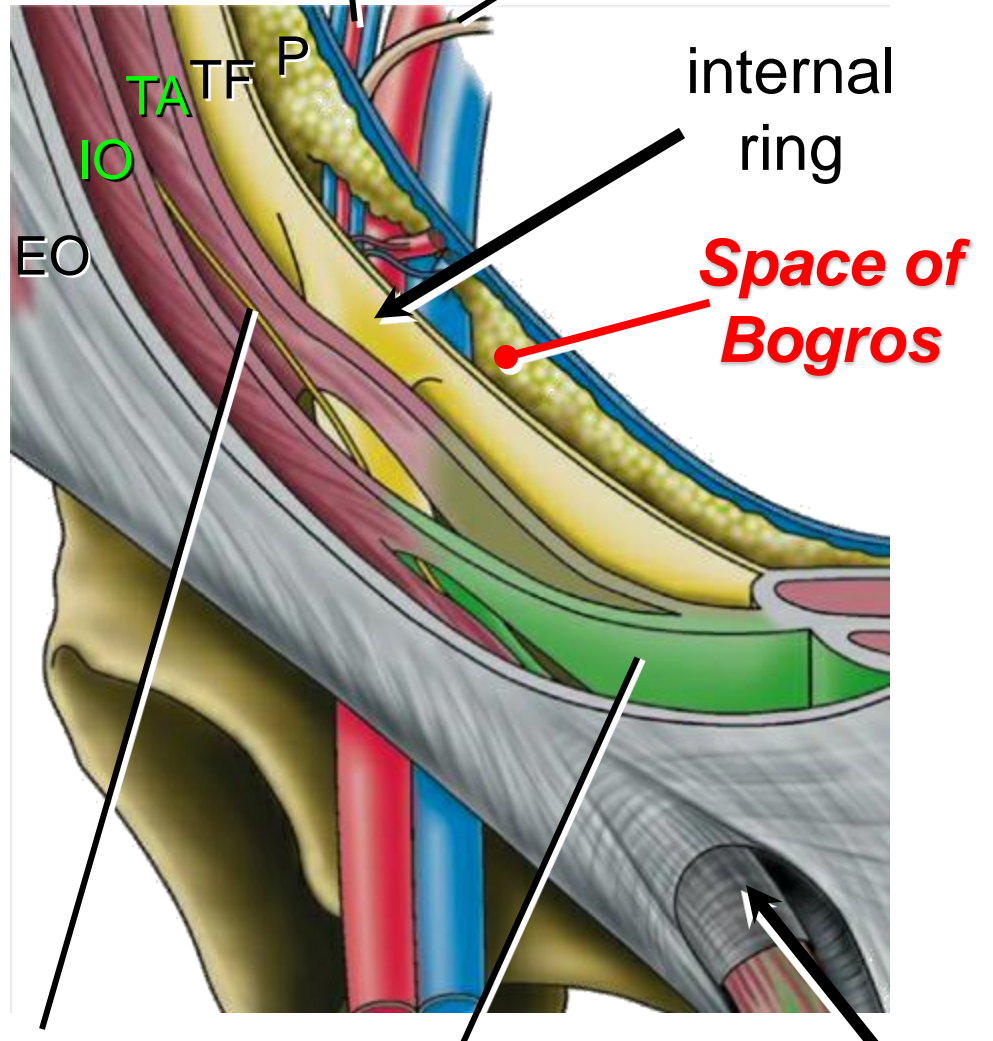
Inguinal Anatomy



Inguinal Anatomy



testicular vessels vas deferens

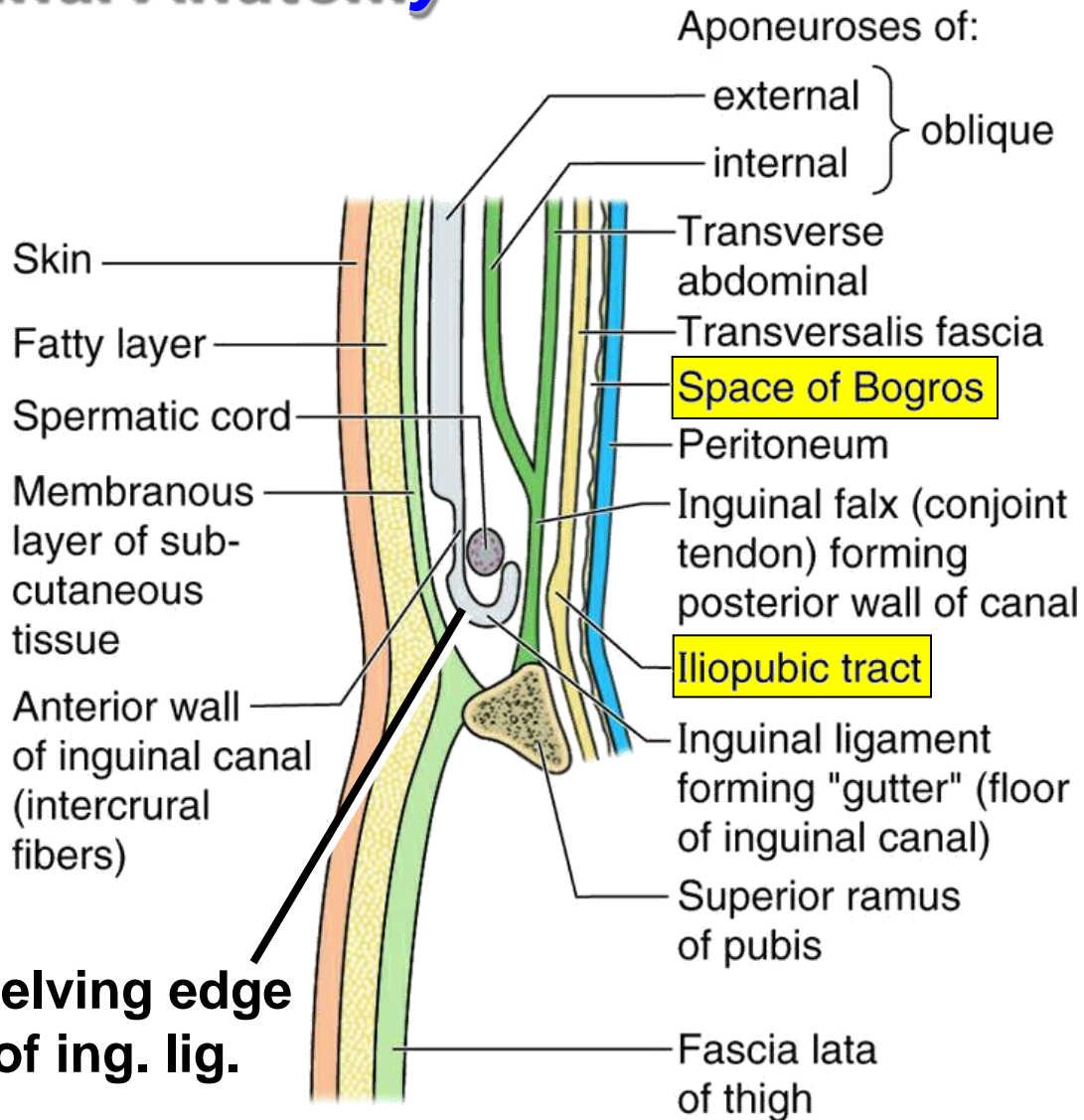
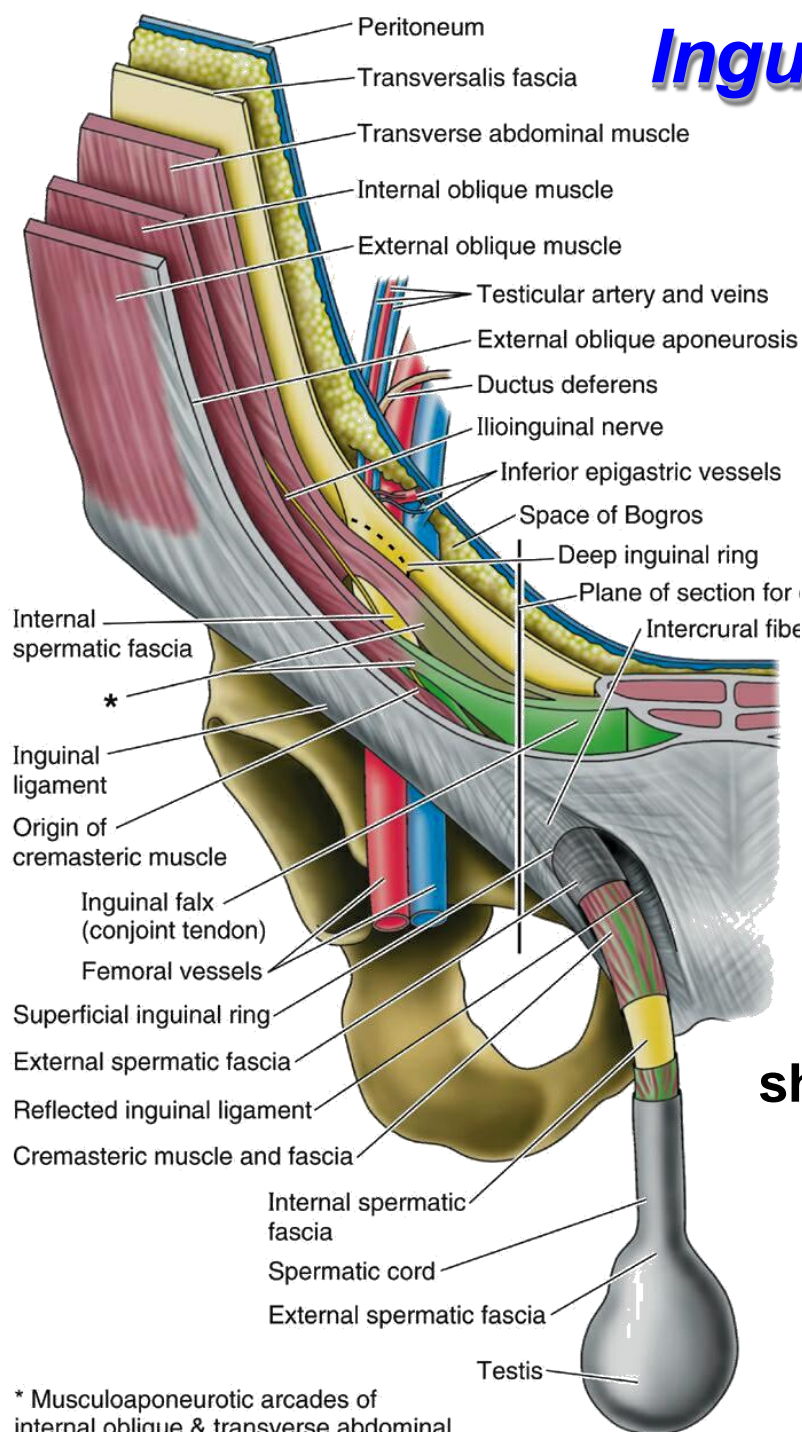


ilioinguinal n.

“conjoint tendon” ring

* Musculoaponeurotic arcades of internal oblique & transverse abdominal

Inguinal Anatomy

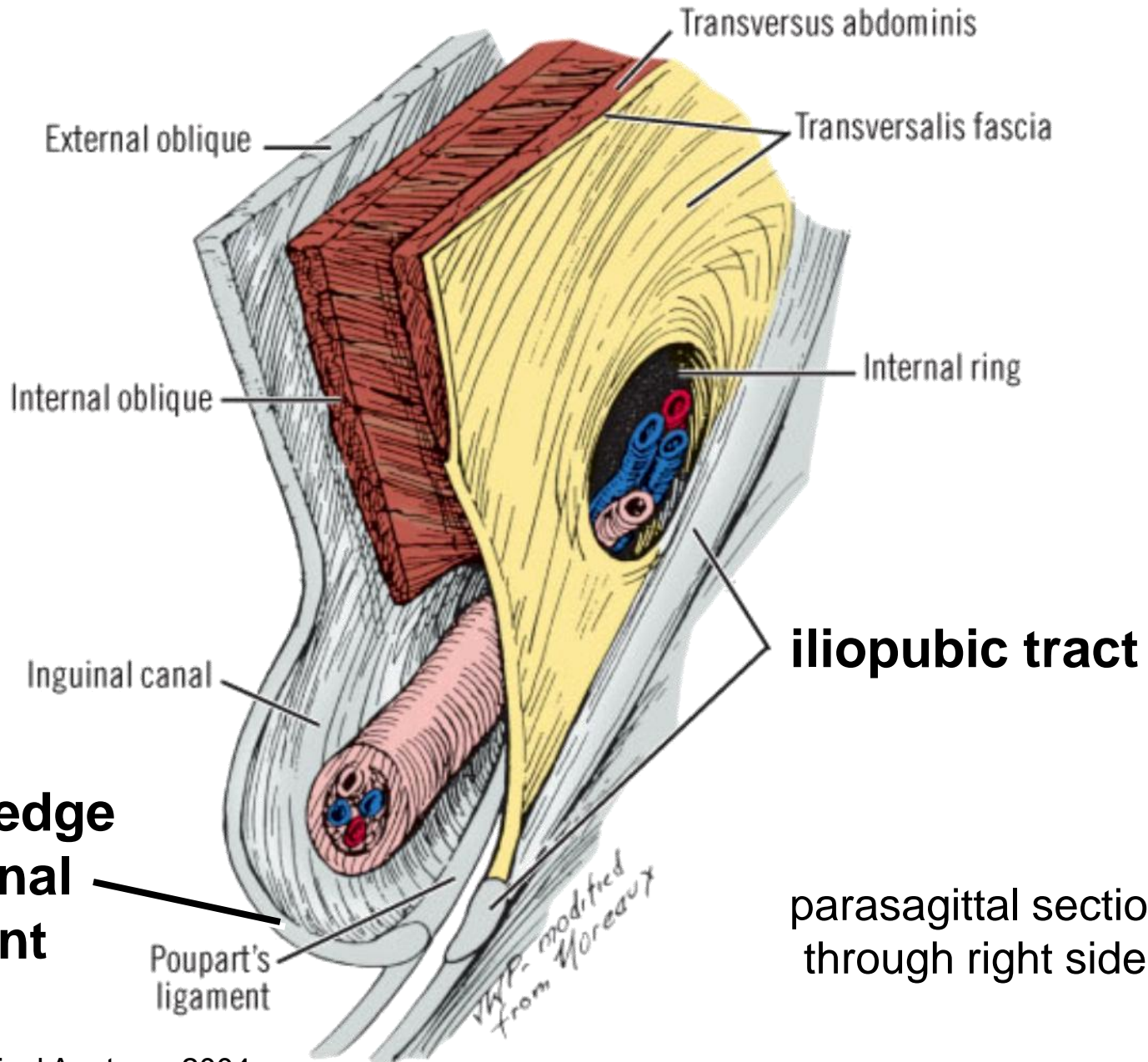


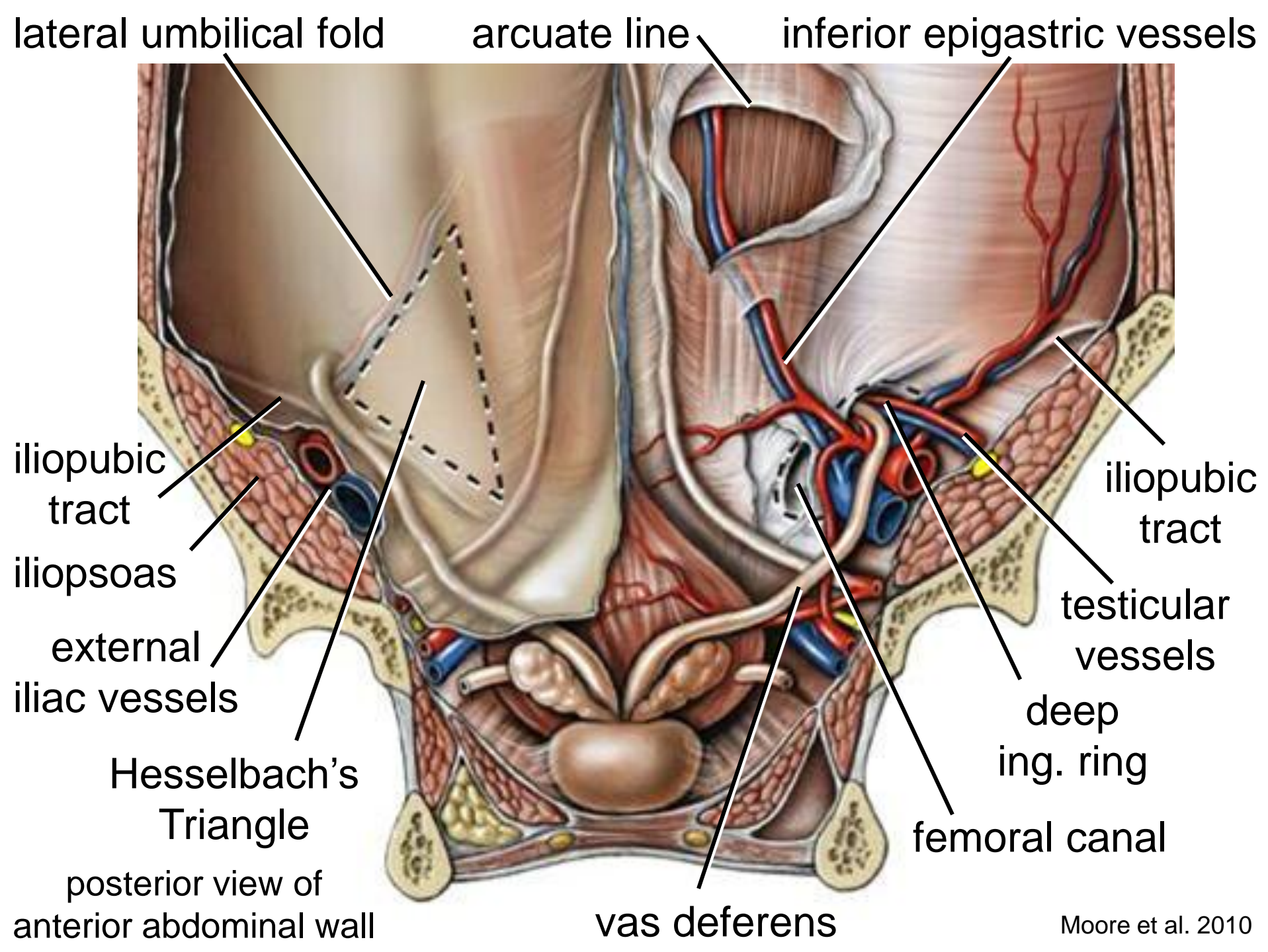
shelving edge of ing. lig.

Schematic sagittal section

* Musculoaponeurotic arcades of internal oblique & transverse abdominal

Inguinal Anatomy





Hesselbach's (Inguinal) Triangle

posterior view
of anterior
abdominal wall

Rectus abdominis

Inguinal triangle

Iliopubic tract

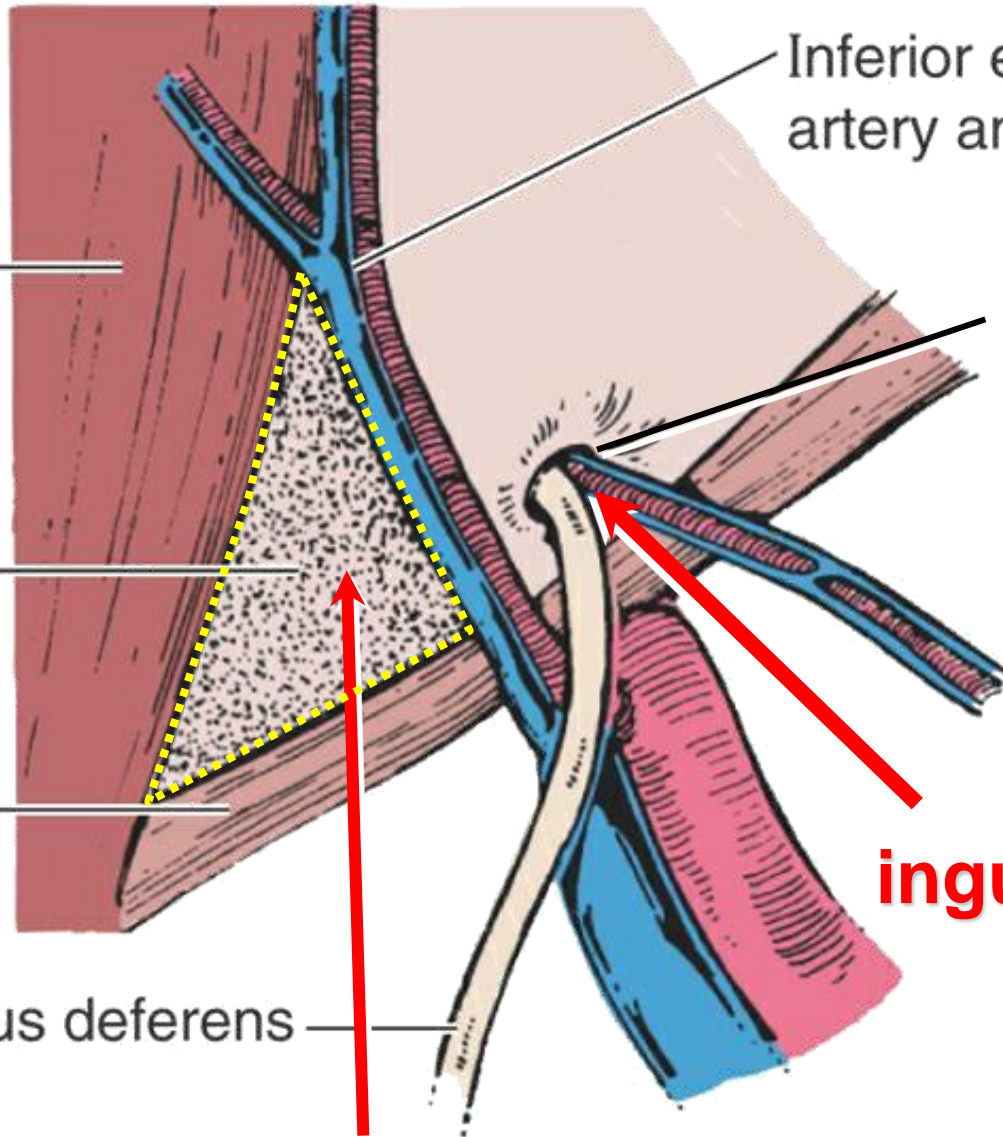
Ductus deferens

Inferior epigastric artery and vein

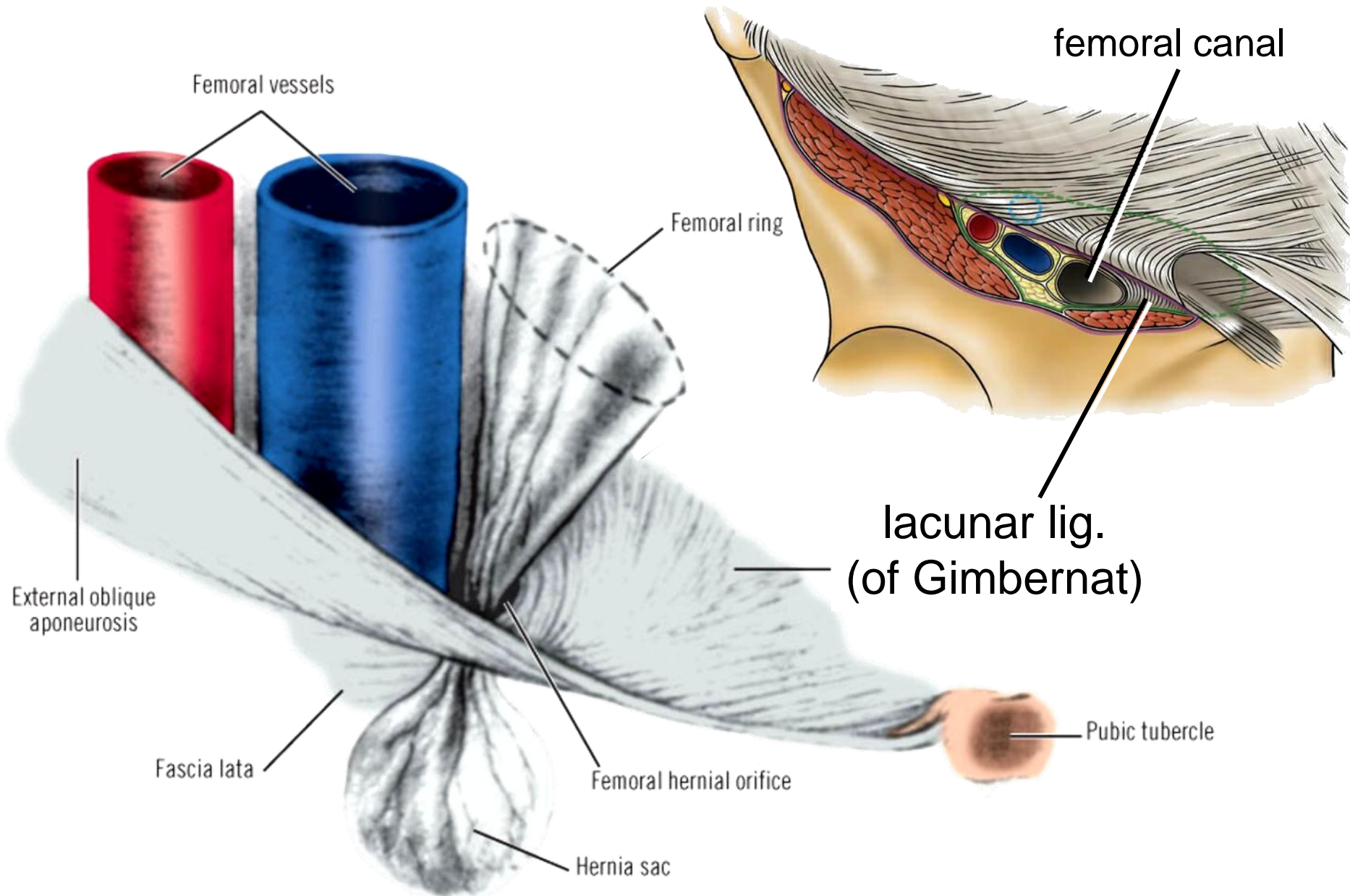
internal inguinal ring

indirect inguinal hernia

direct inguinal hernia



Femoral Hernia



References

- Cahill, D. R. 1997. *Lachman's Case Studies in Anatomy, 4th Ed.* Oxford University Press, New York.
- Moore, K. L., A. F. Dalley, and A M. R. Agur. 2010. *Clinically Oriented Anatomy, 6th Ed.* Lippincott, Williams & Wilkins, Baltimore.
- Moore, K. L. and T. V. N. Persaud. 2003. *The Developing Human. Clinically Oriented Embryology, 7th Ed.* Lippincott, Williams & Wilkins, Baltimore.
- Skandalakis, J. E., G. L. Colborn, T. A. Weidman, R. S. Foster, A. N. Kingsnorth, L. J. Skandalakis, N. P. Skandalakis, P. Mirilas (Editors). 2004. *Surgical Anatomy: The Embryologic And Anatomic Basis Of Modern Surgery.* McGraw-Hill, New York.