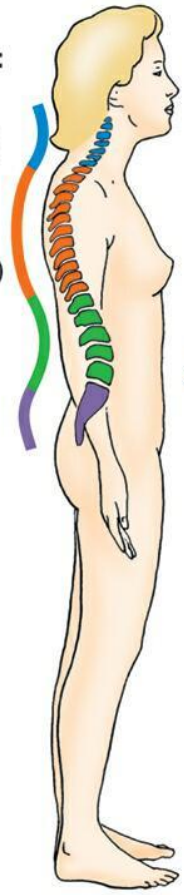
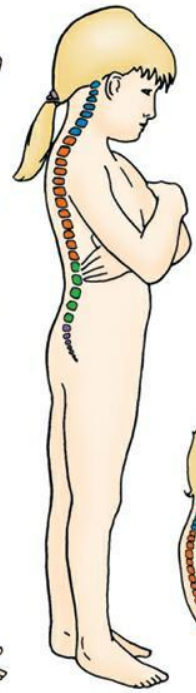
Hyperlordosis & Hyperkyphosis (and other abnormal curvatures)

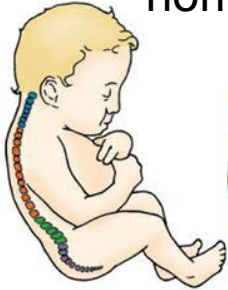Curvatures:
Cervical (2)
Thoracic (1)
Lumbar (2)
Sacral (1)



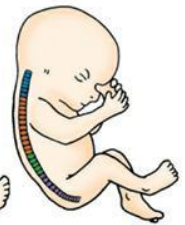Adult



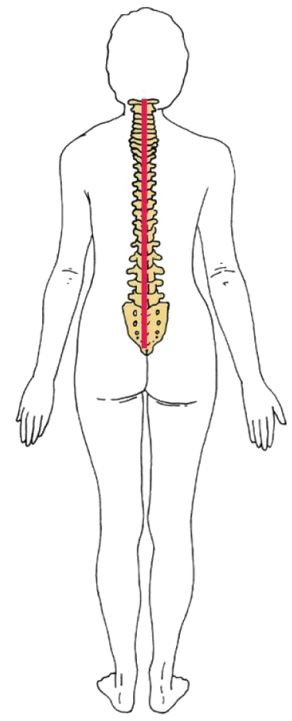
4 years



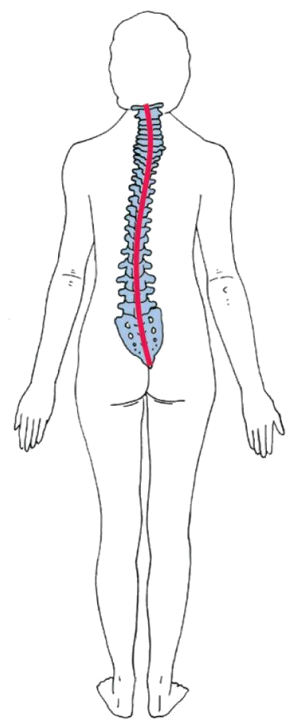
Newborn



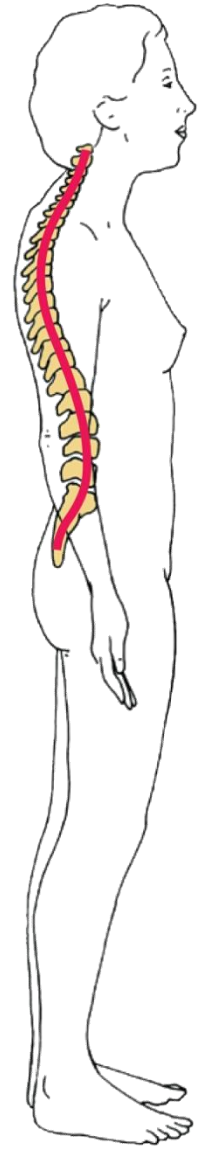Fetus



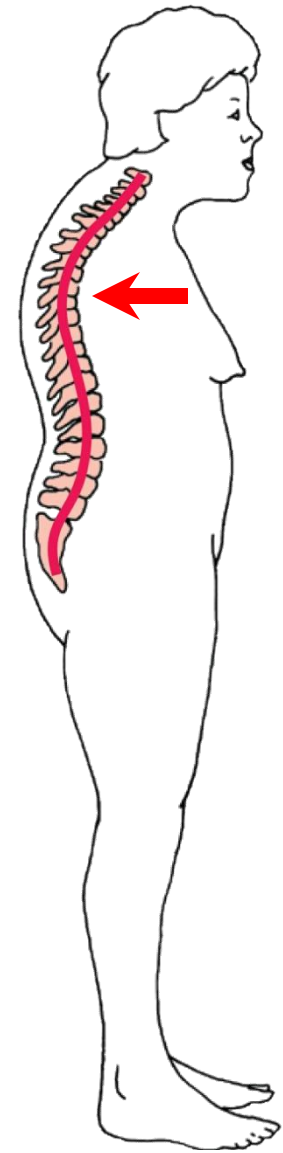
normal



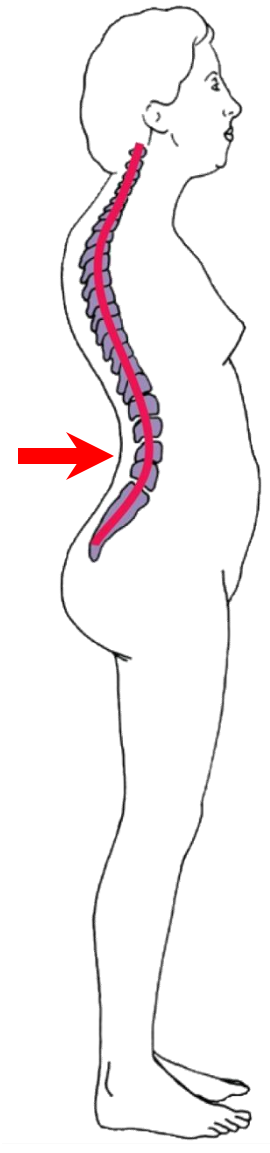
scoliosis



normal



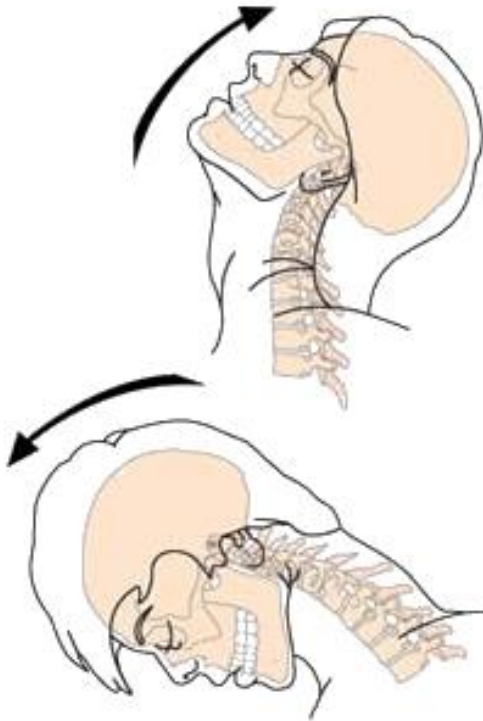
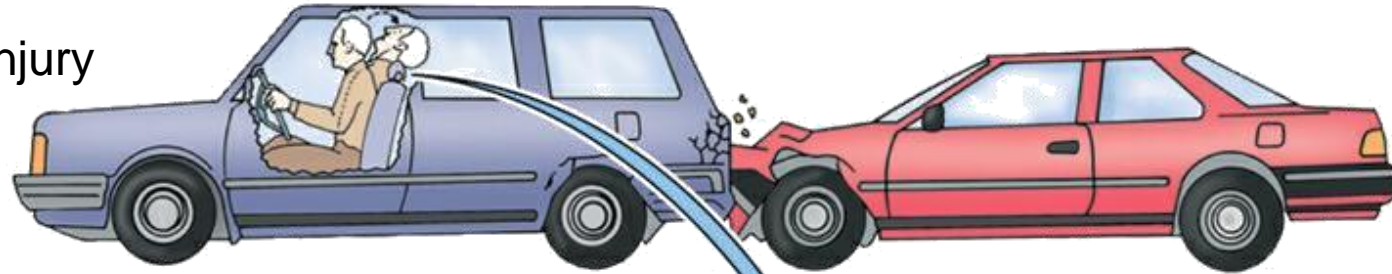hyper-
kyphosis



hyper-
lordosis

Whiplash

cervical hyperextension injury

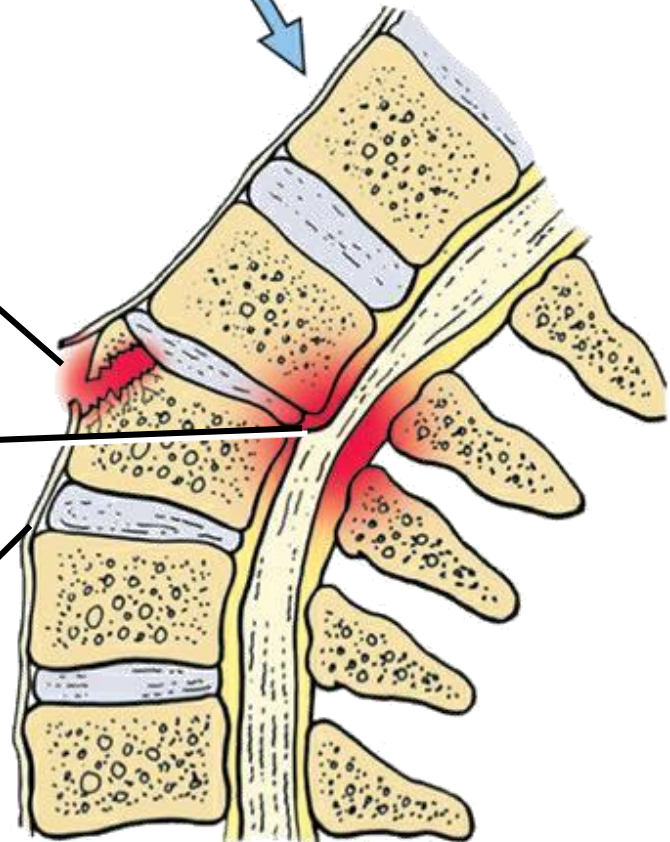


lajollaspine.com

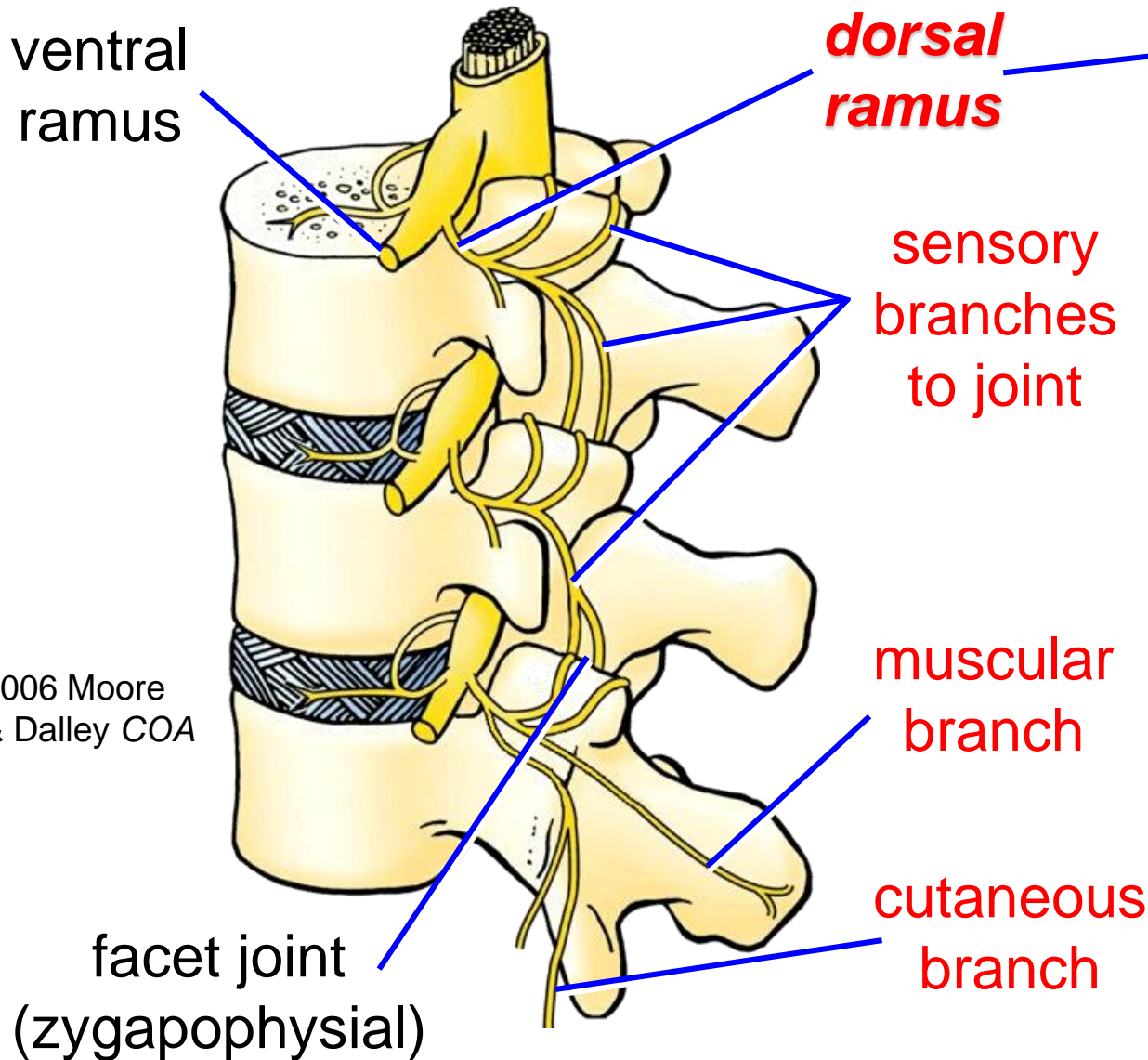
sprain or tear

cervical IV
disc bulges

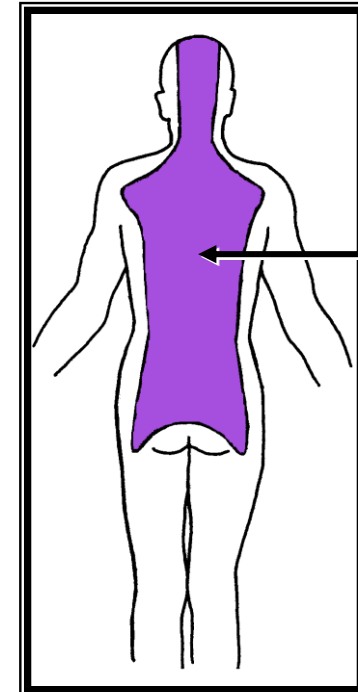
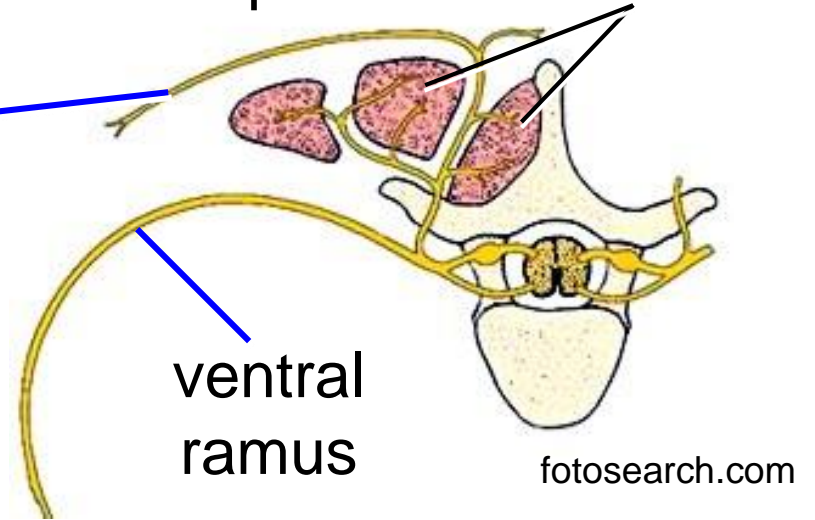
anterior longitudinal lig.



Innervation of Facet Joints



deep back muscles



cutaneous territory of dorsal rami

Stern *Essentials of Gross Anatomy*