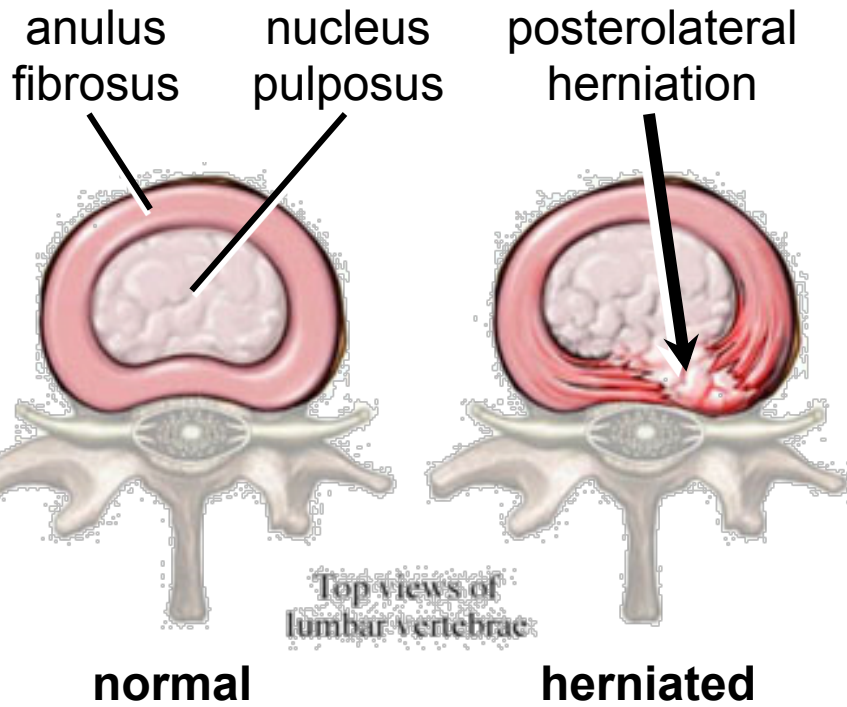


Herniated Disc

("slipped disc")



back1.com

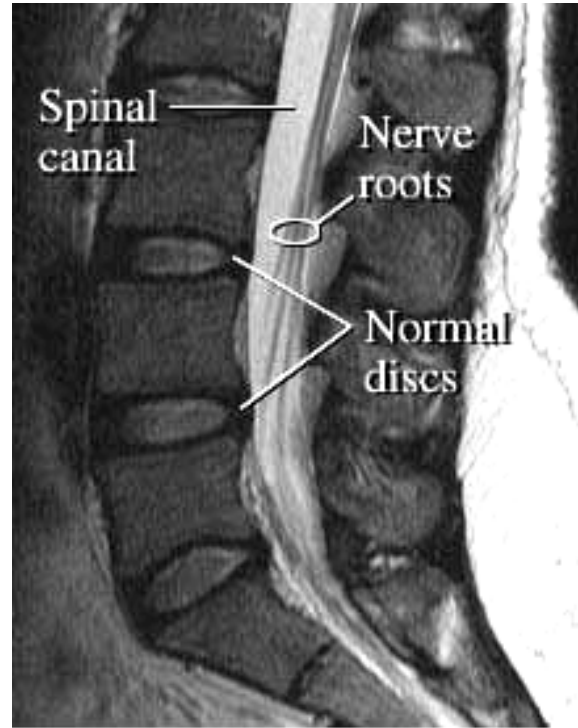


Figure 1

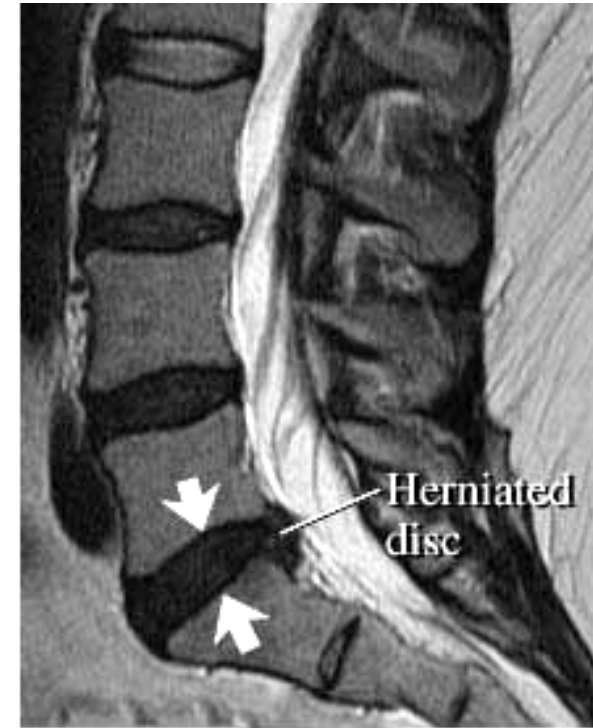


Figure 2

myhealth.barnesjewish.org

Herniated Disc

("slipped disc")

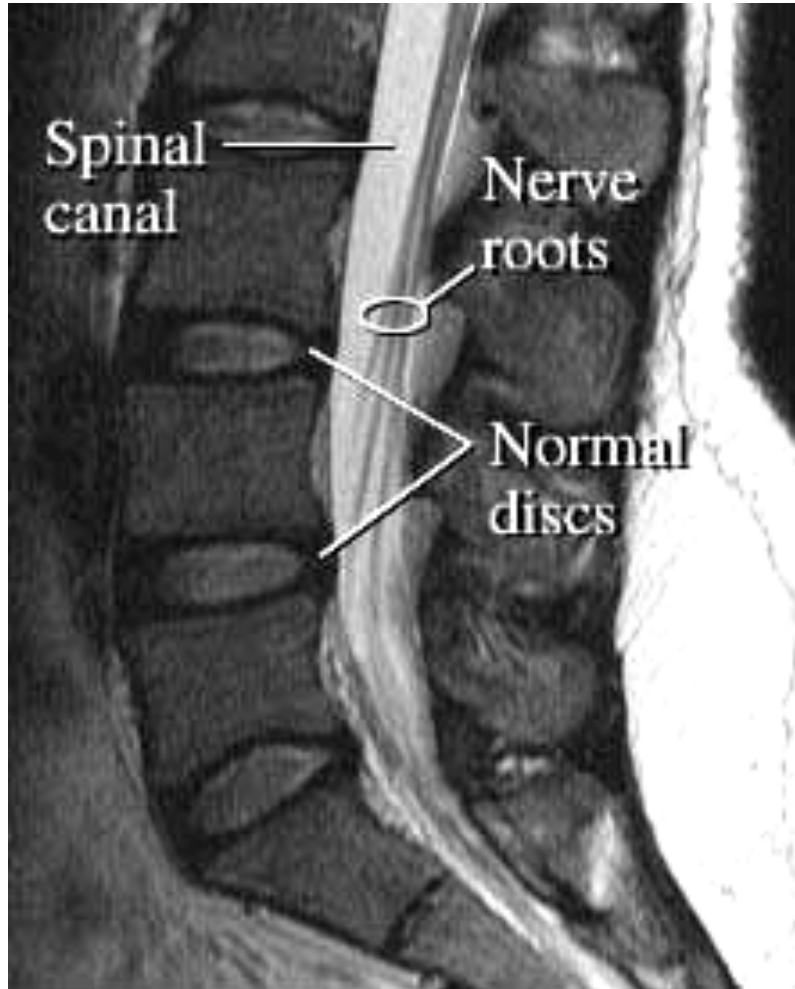


Figure 1

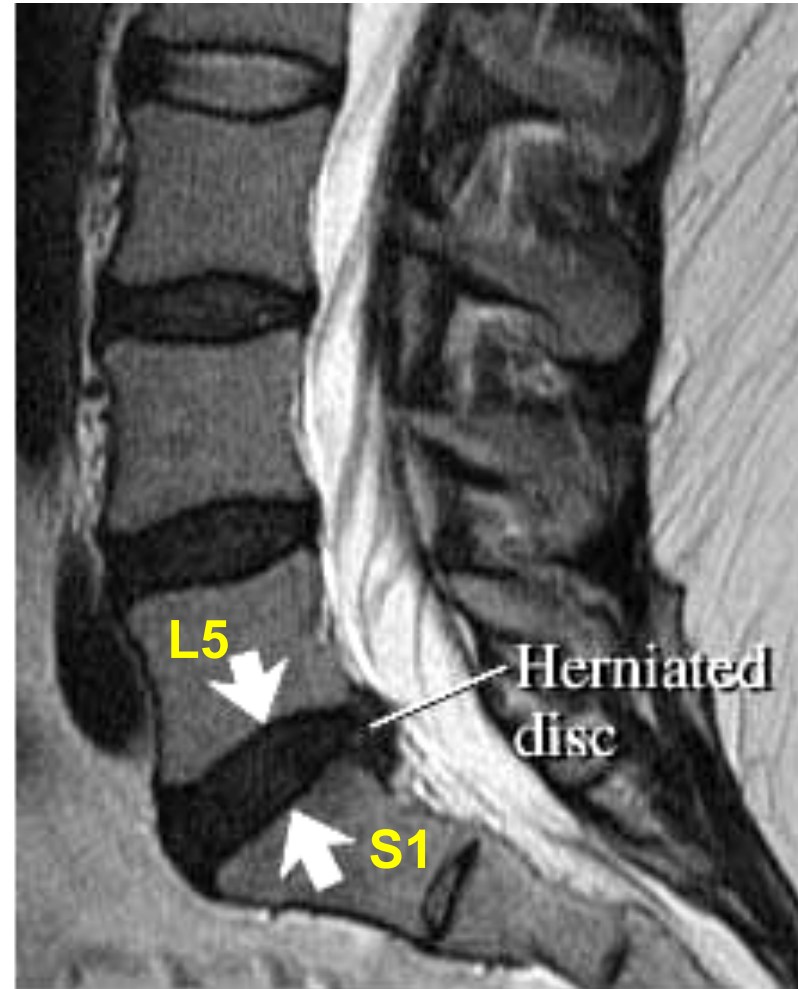


Figure 2

Herniated Disc

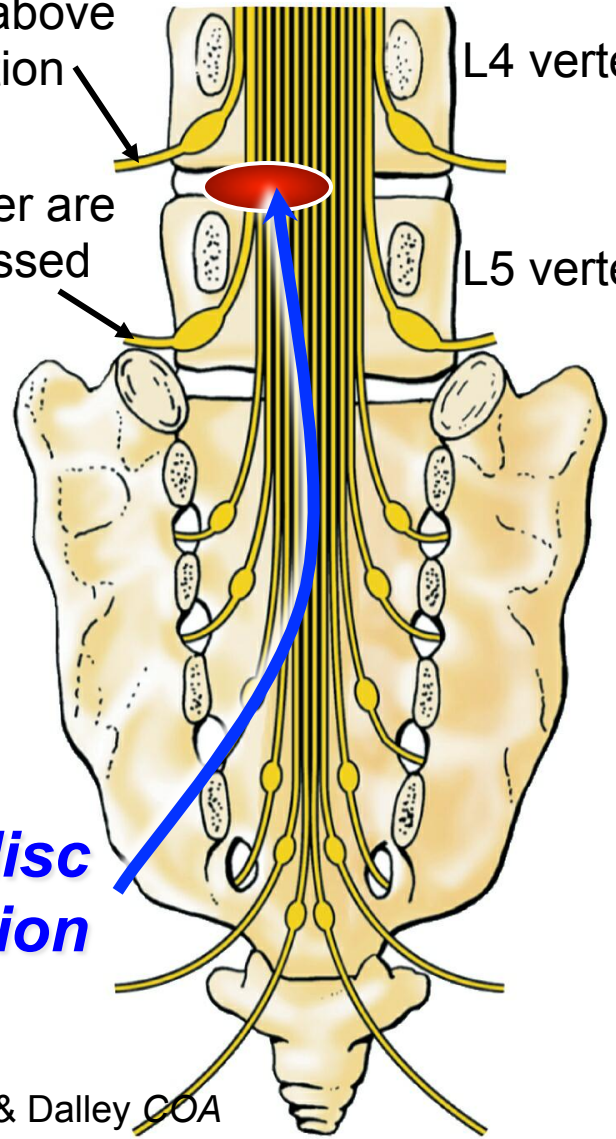
("slipped disc")

L4 exits above herniation

L5 & lower are compressed

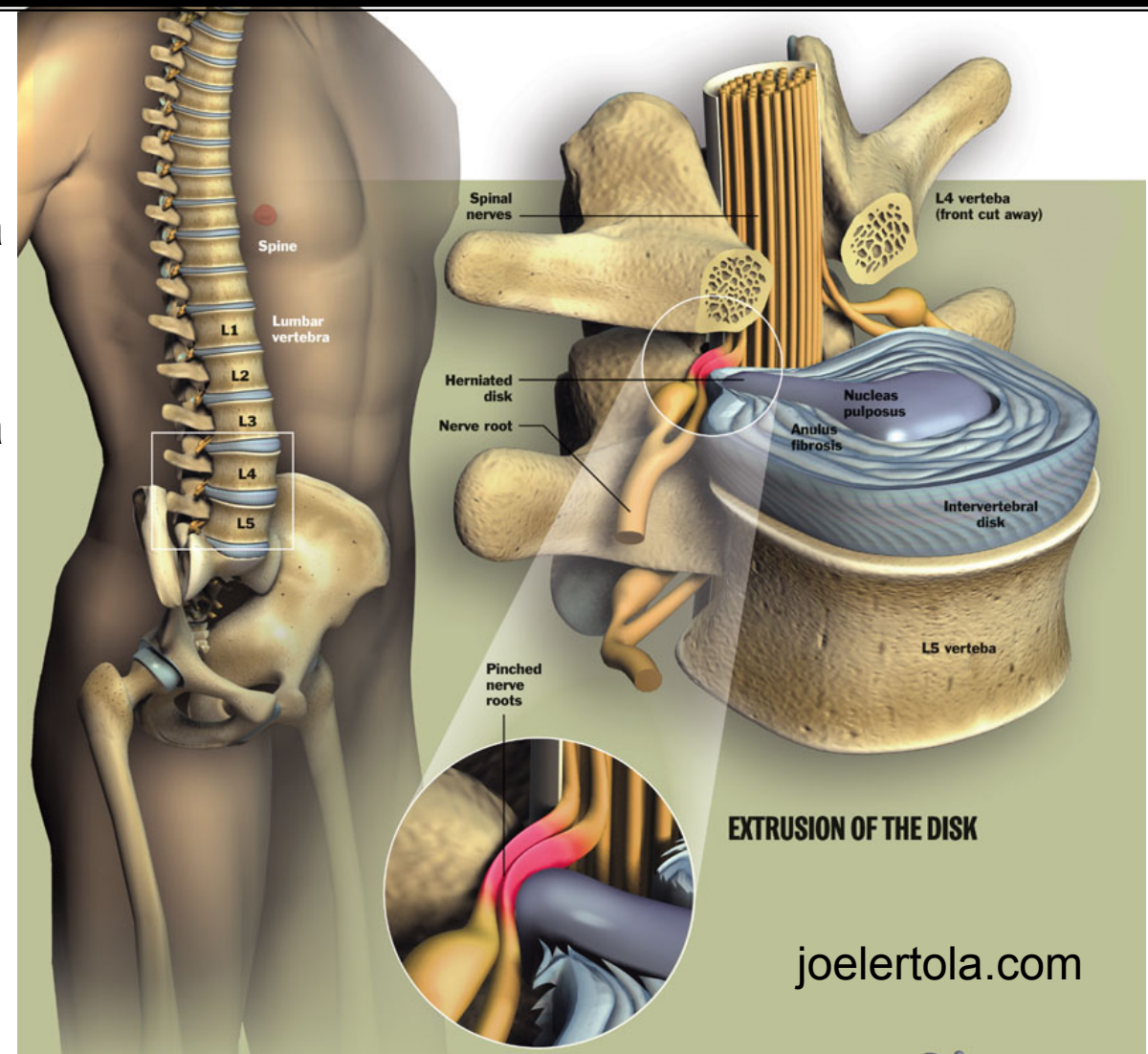
L4 vertebra

L5 vertebra



L4/L5 disc herniation

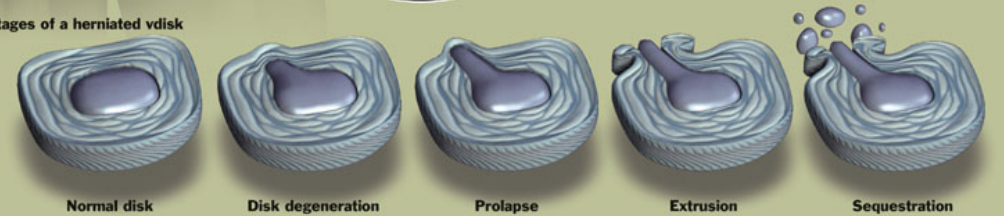
2006 Moore & Dalley COA



EXTRUSION OF THE DISK

joelertola.com

Stages of a herniated disk



Normal disk

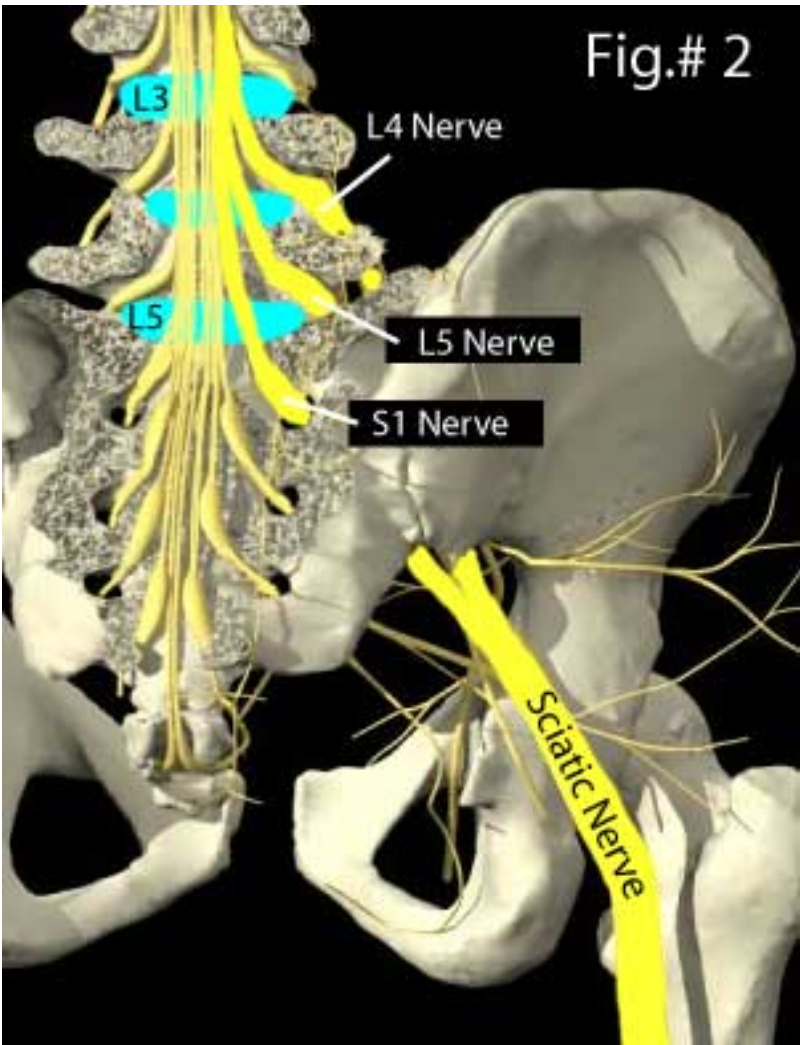
Disk degeneration

Prolapse

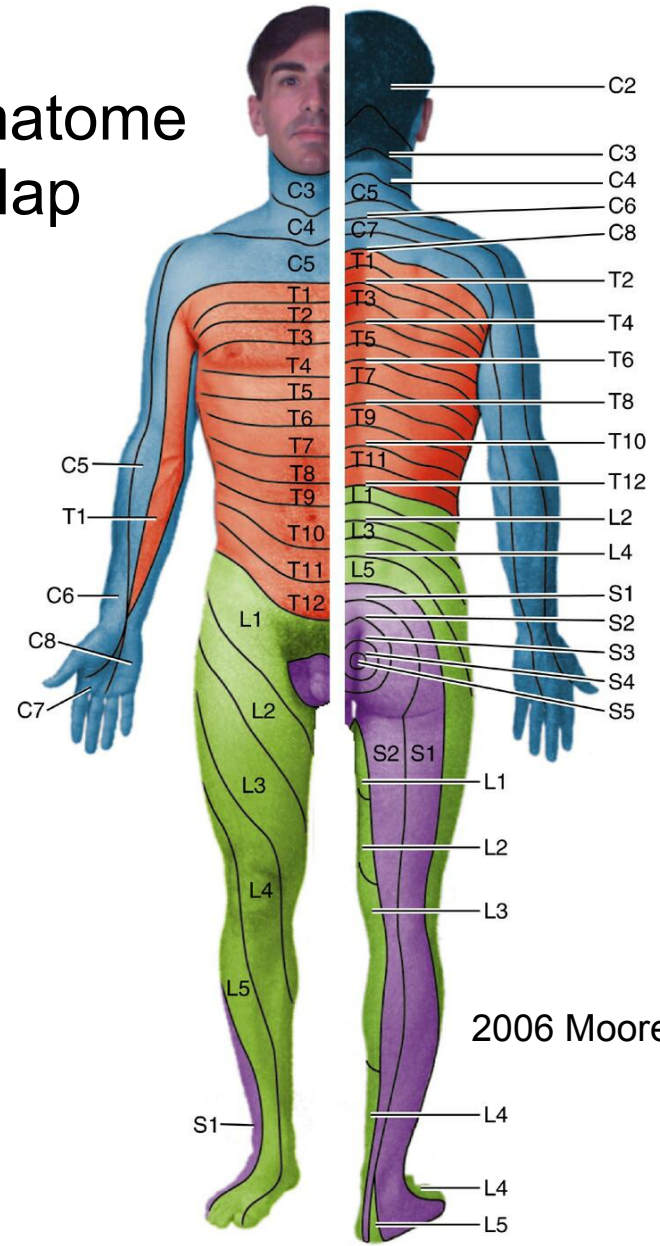
Extrusion

Sequestration

Sciatica



Dermatome Map

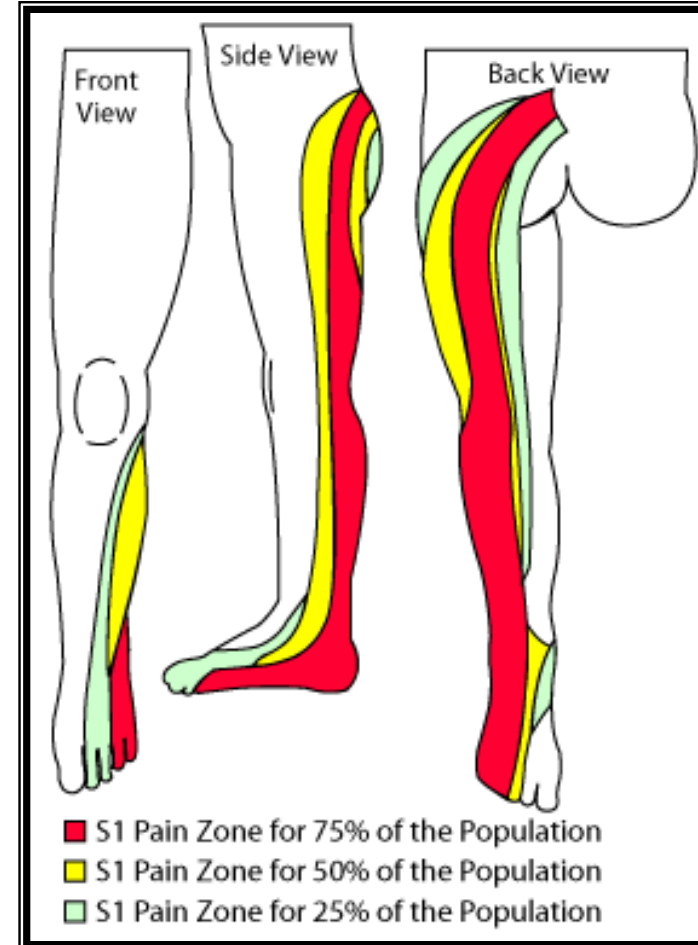
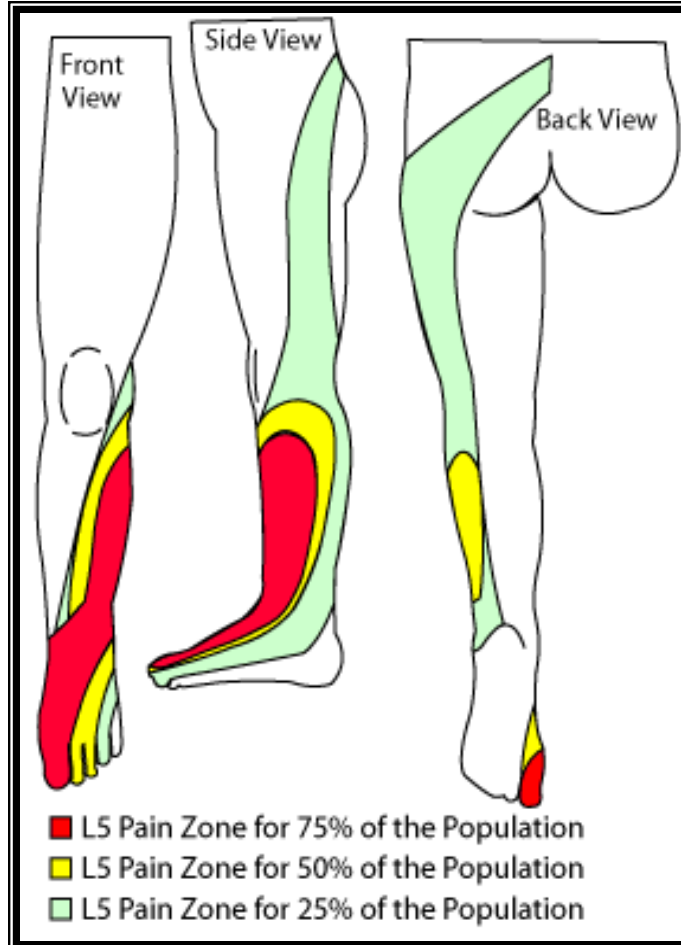
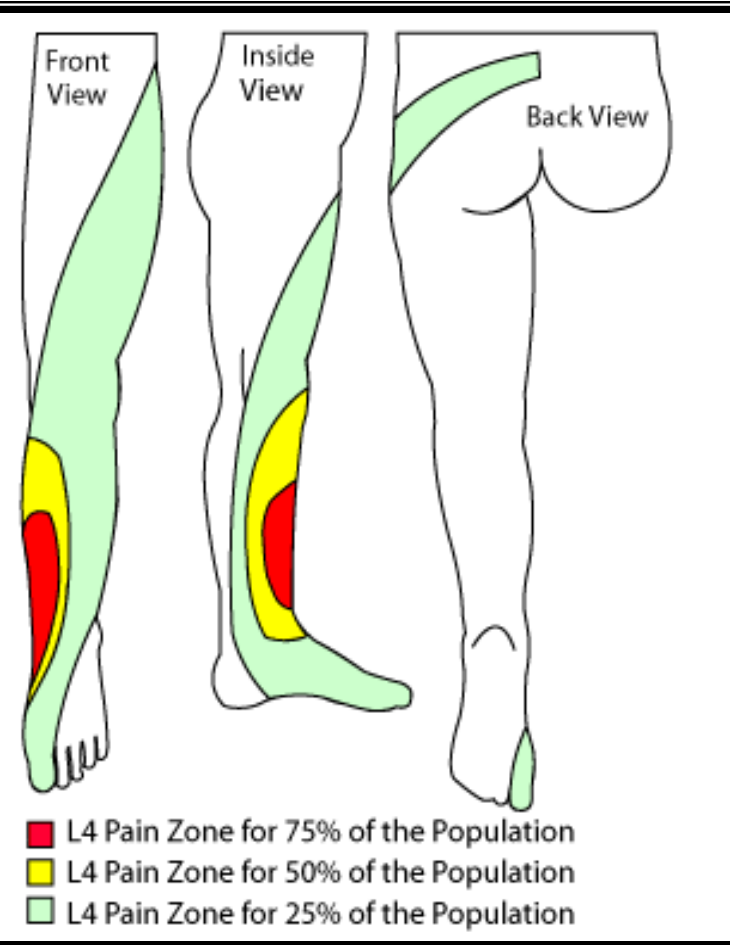


2006 Moore & Dalley COA

Anterior view Posterior view

Sciatica


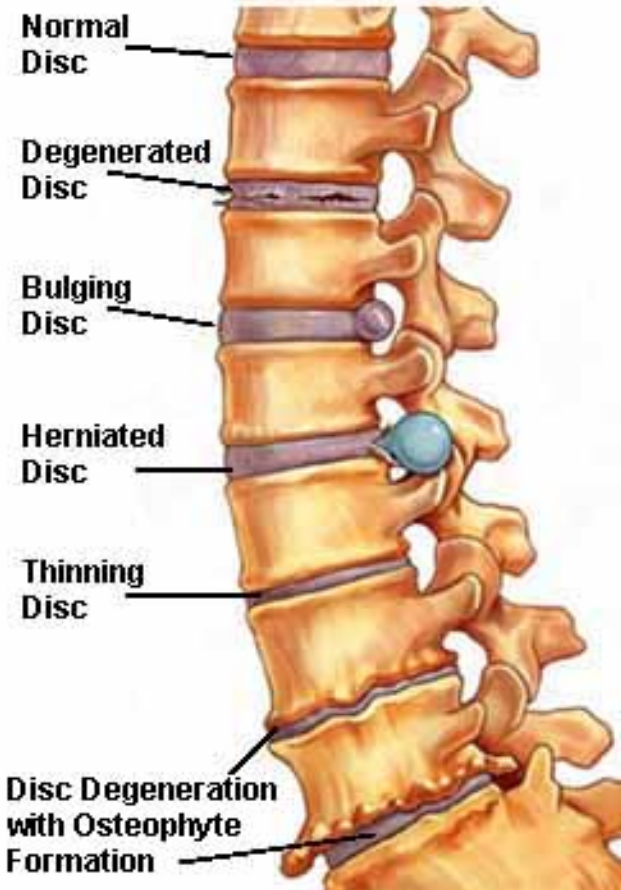
Variation in Radicular Pain



Lumbar Spondylosis

osteophyte formation

Examples of Disc Problems



Left anterior superior oblique view

* = osteophytes