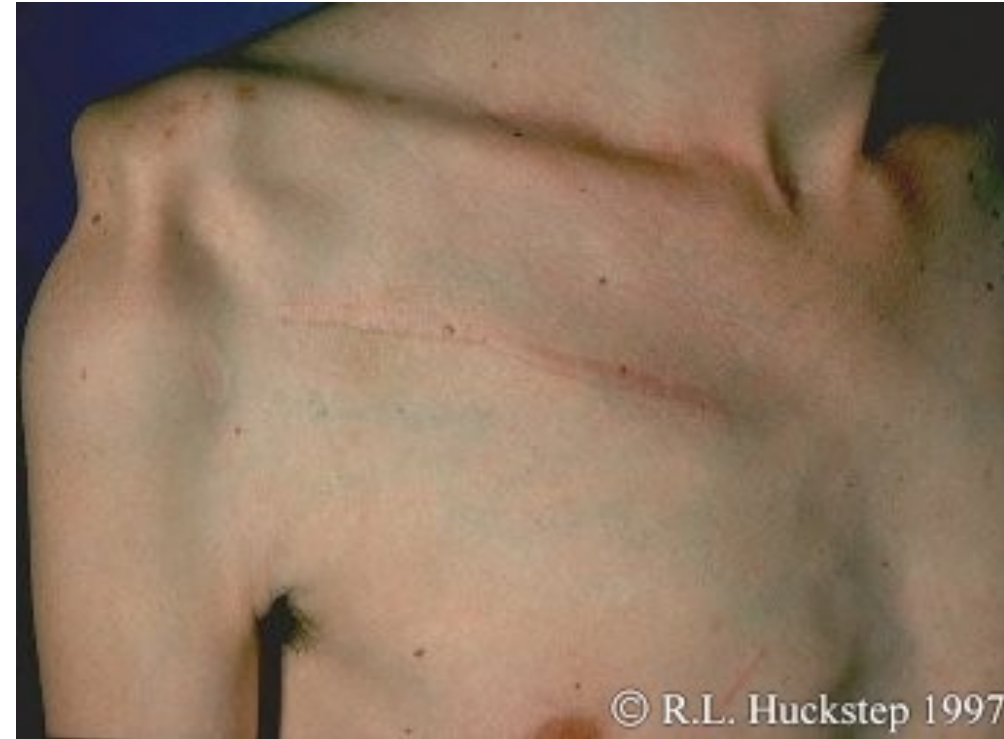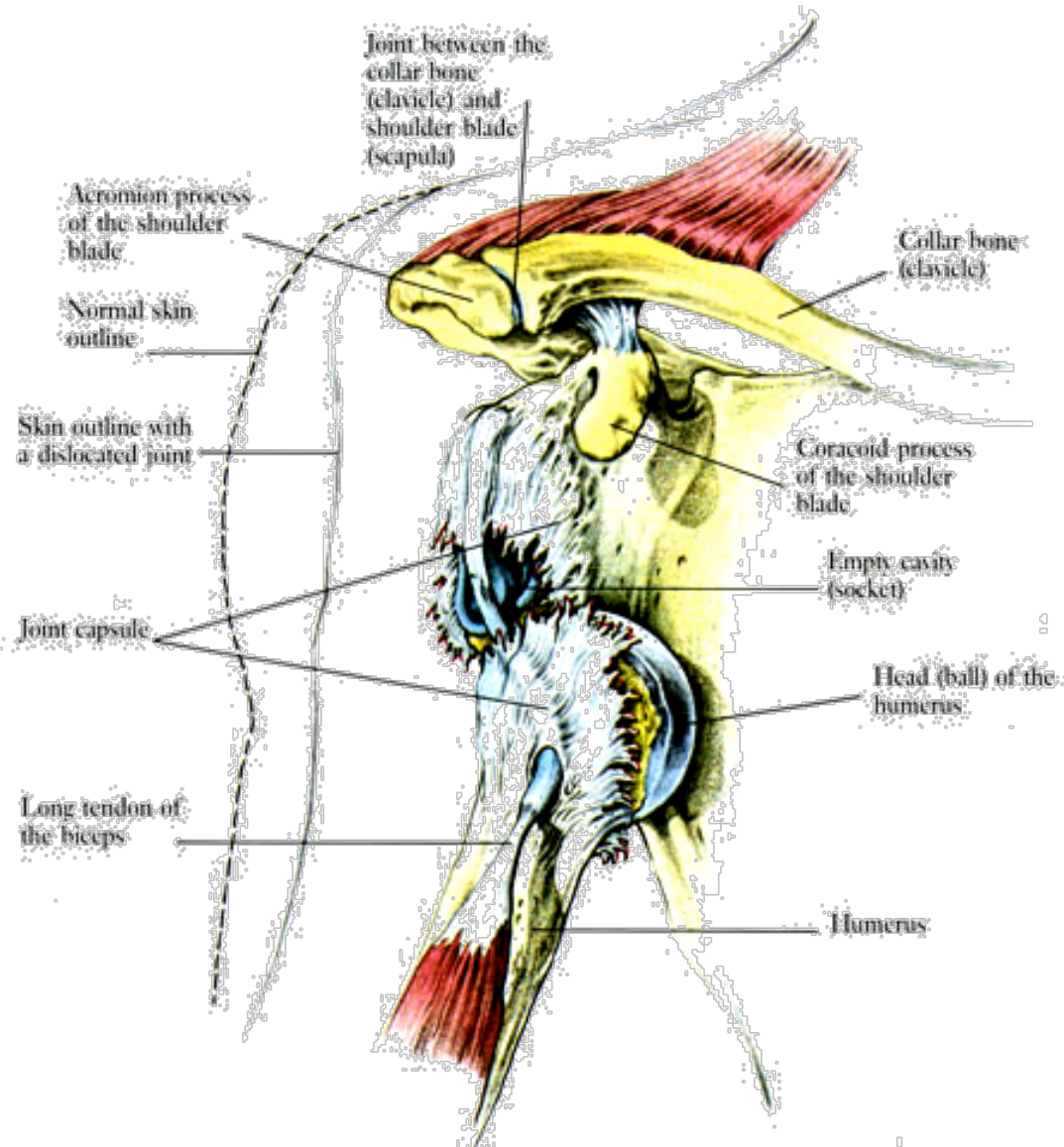
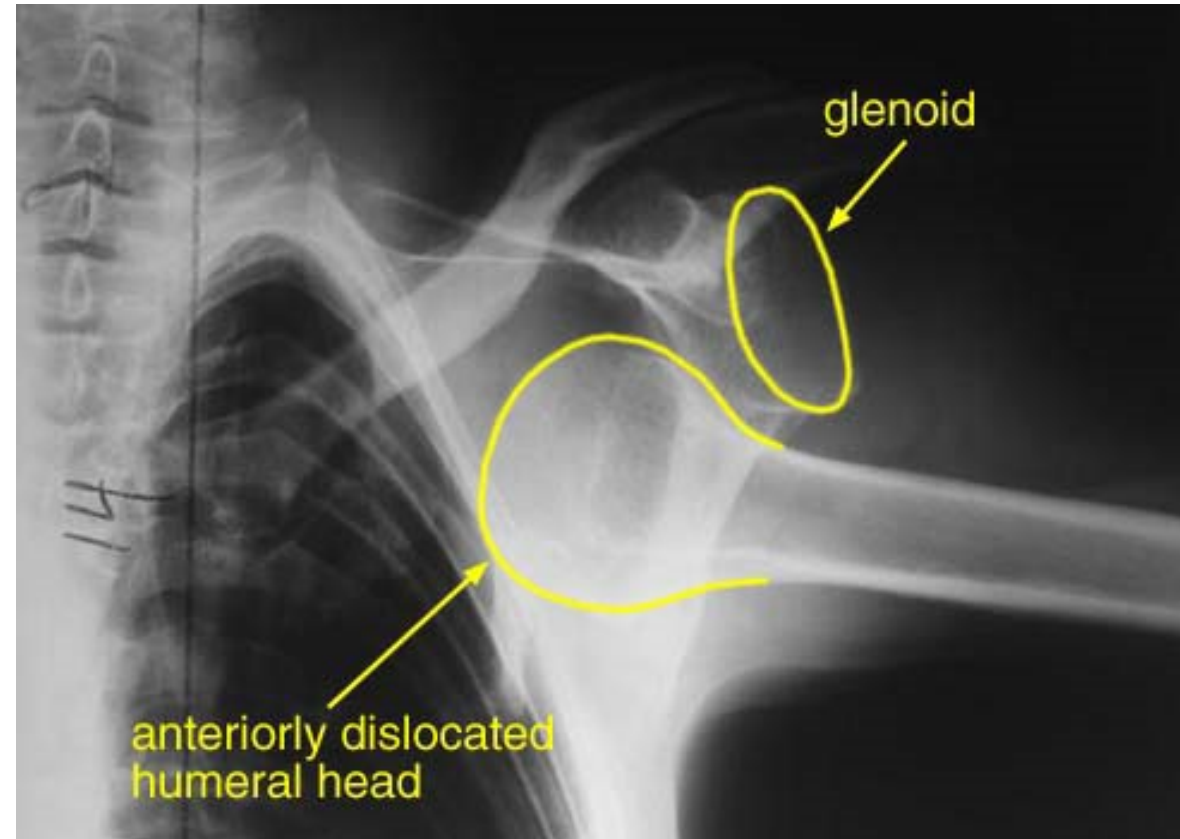


Anterior glenohumeral dislocation

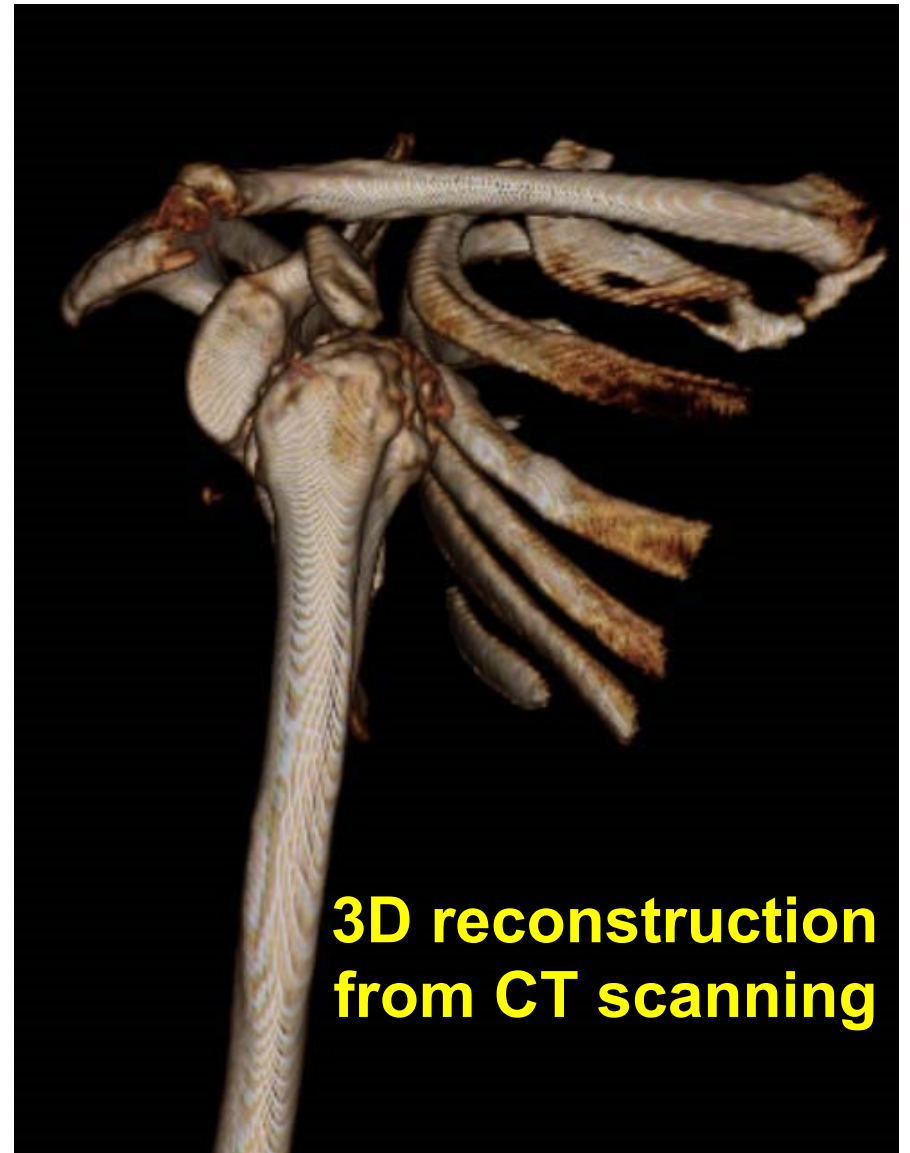


[physiomonkey.blogspot.com/images/
medium_dislocated_shoulder.jpg](http://physiomonkey.blogspot.com/images/medium_dislocated_shoulder.jpg)

Anterior glenohumeral dislocation

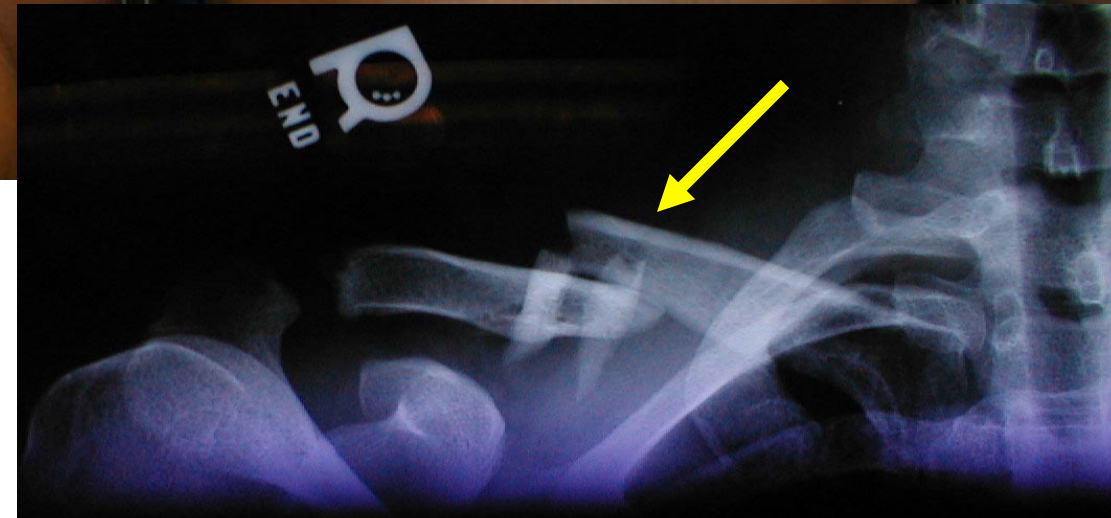
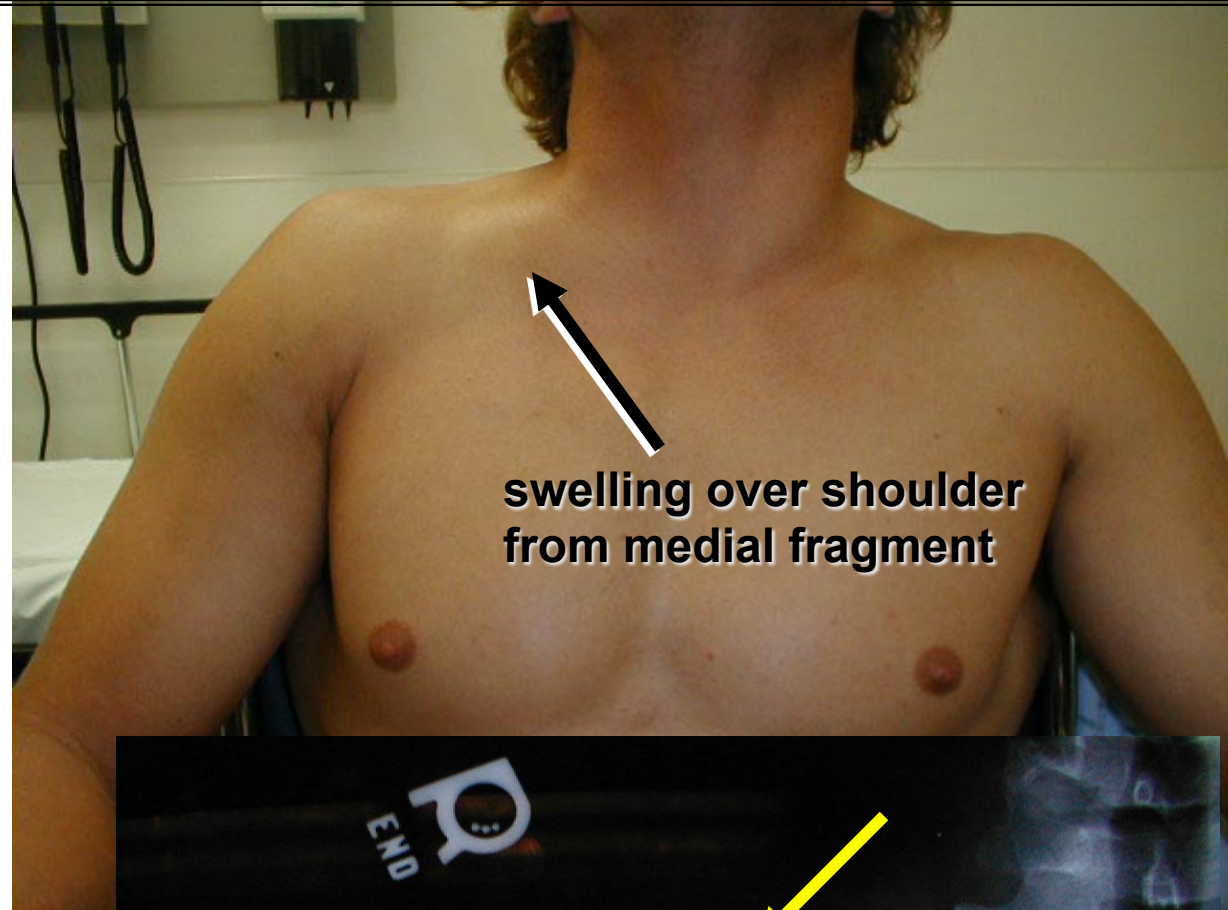
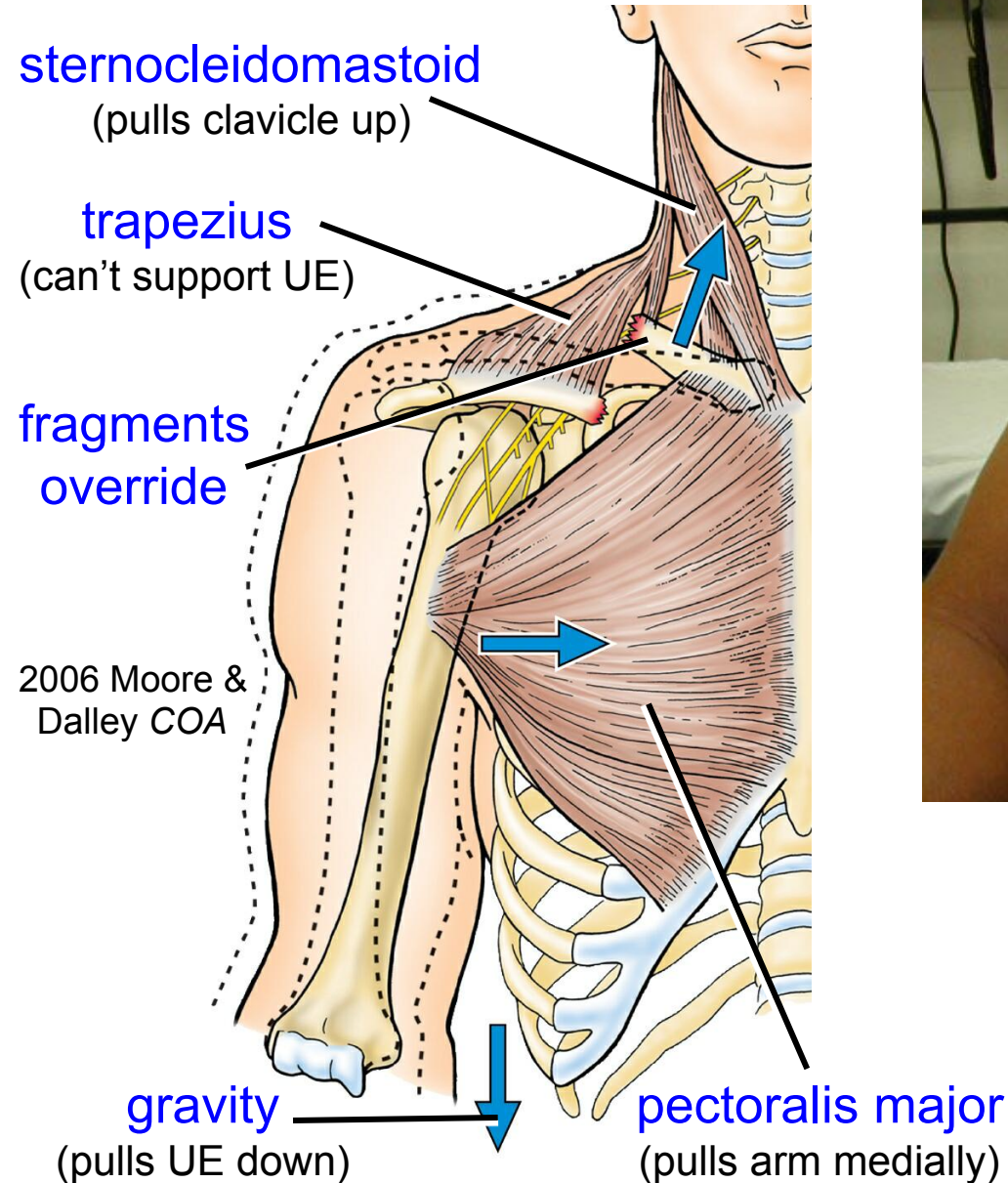


[meded.ucsd.edu/isp/2005/orthopedic/
images/ShoulderDislocationAntL.jpg](http://meded.ucsd.edu/isp/2005/orthopedic/images/ShoulderDislocationAntL.jpg)

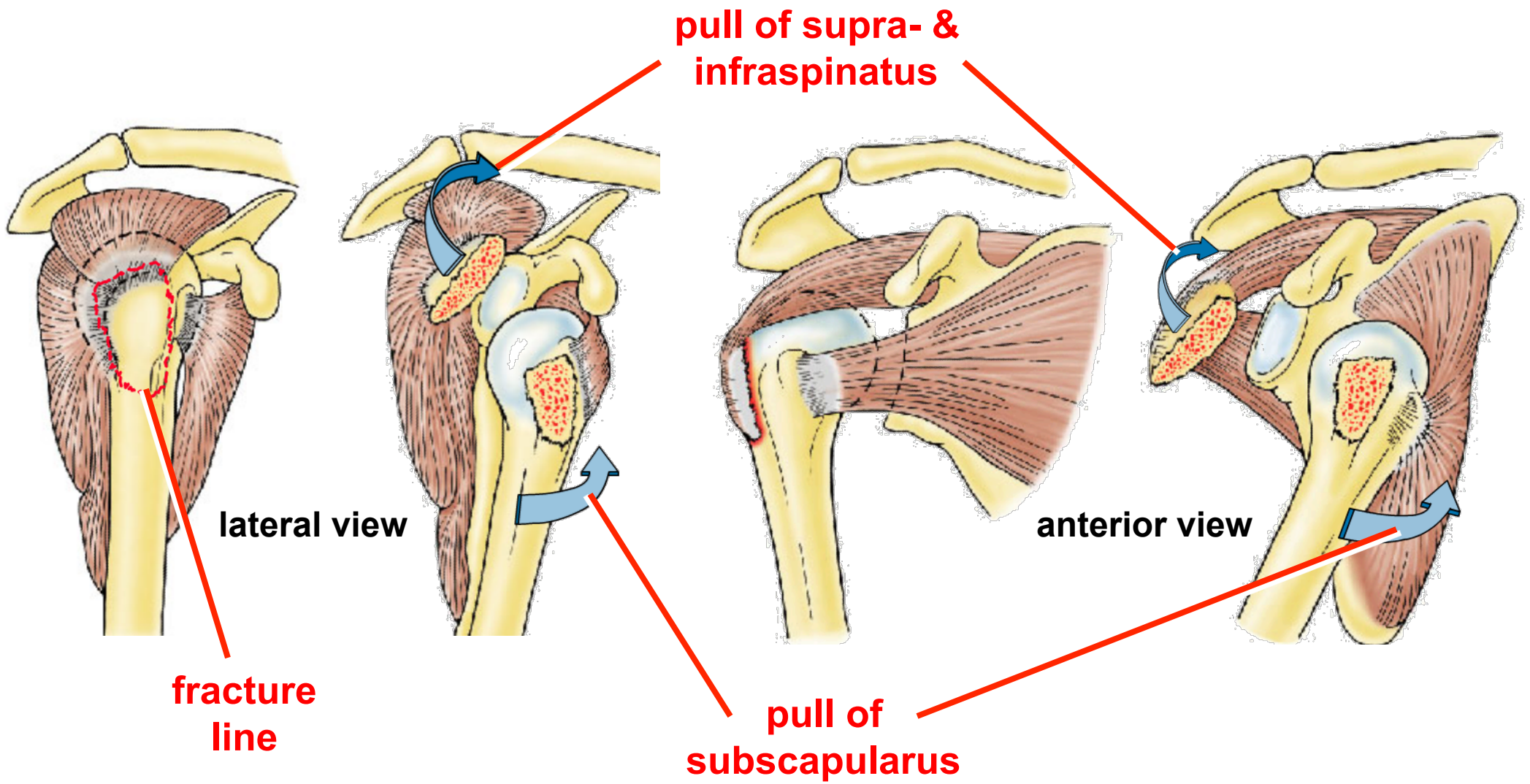


refindia.net/ref/quiz/images2006/vol8no02_fig3b.jpg

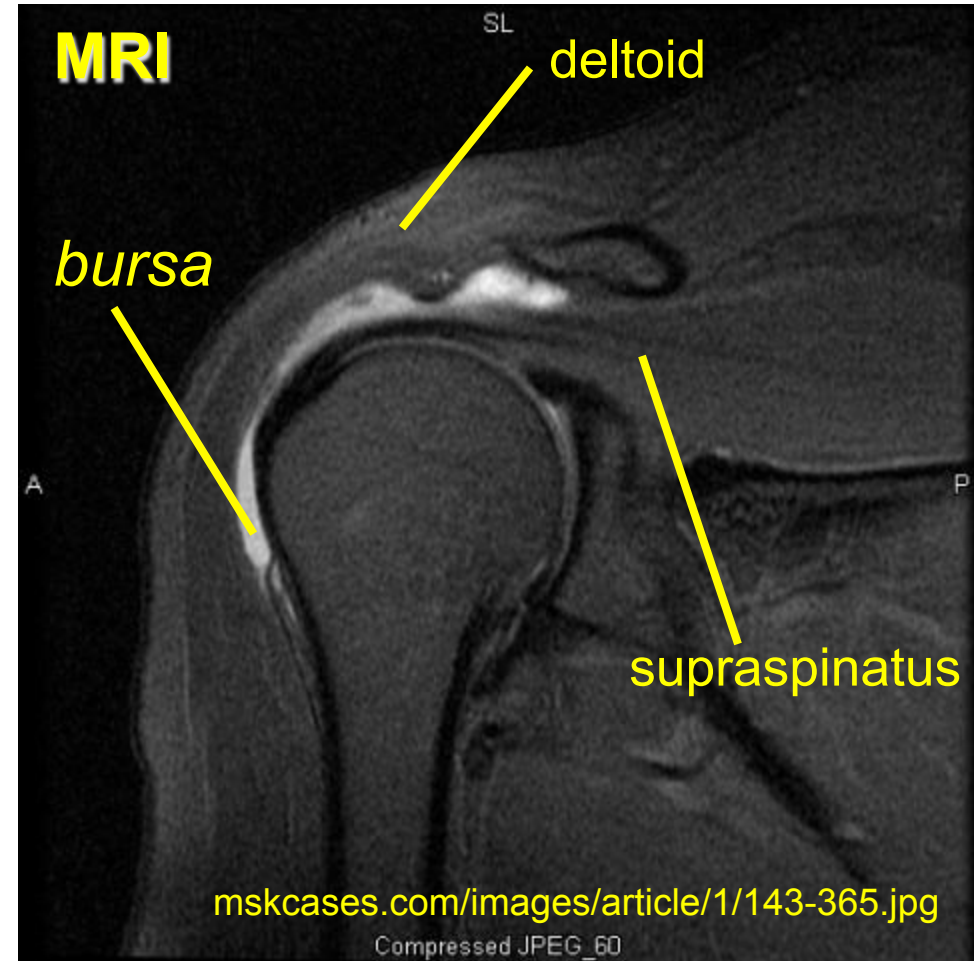
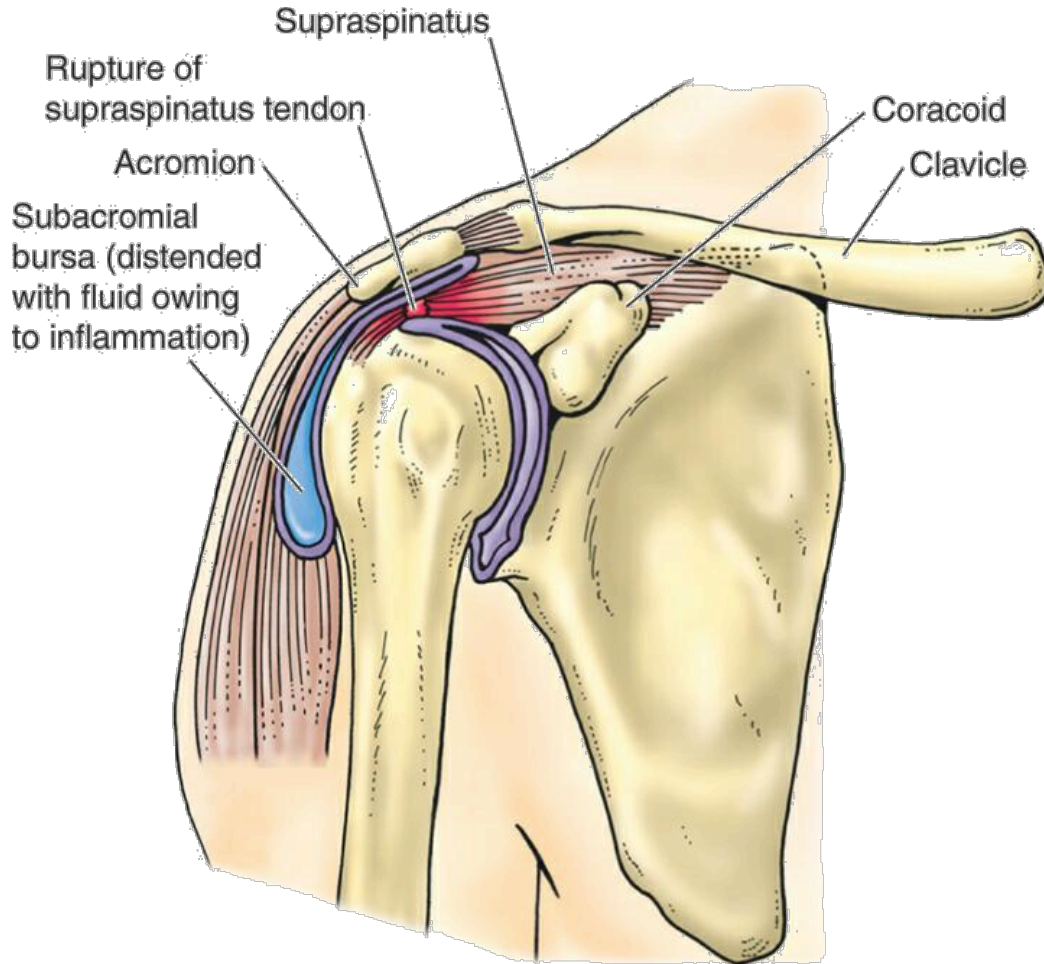
Clavicular fracture



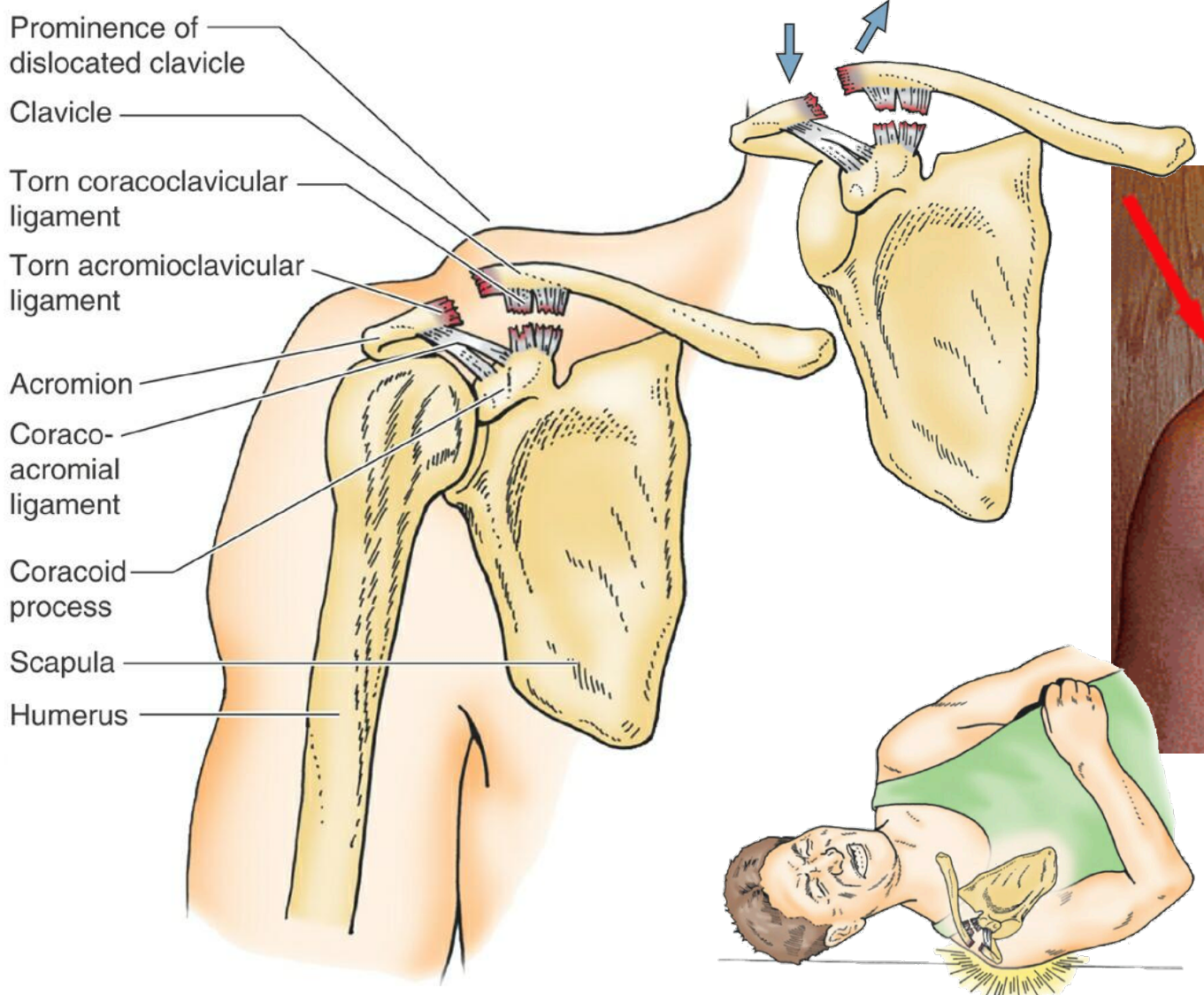
Avulsion of Greater Tubercle



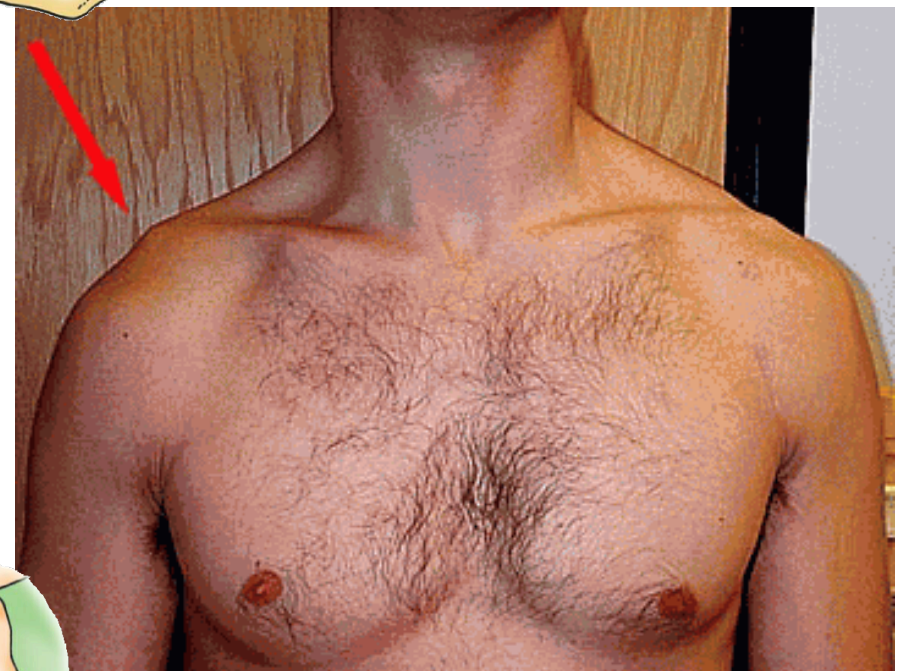Subacromial bursitis



Acromioclavicular dislocation



Note clavicular bump (arrow)



sportsandortho.com/images/patient_education/SeparatedShoulder3.jpg