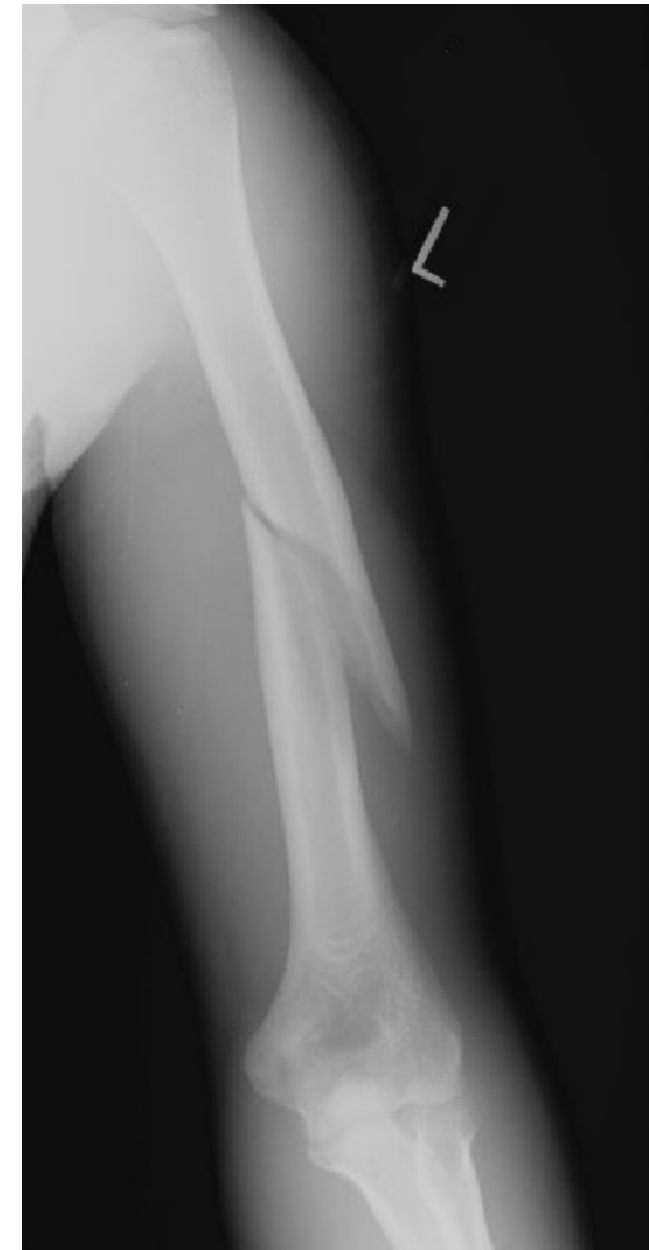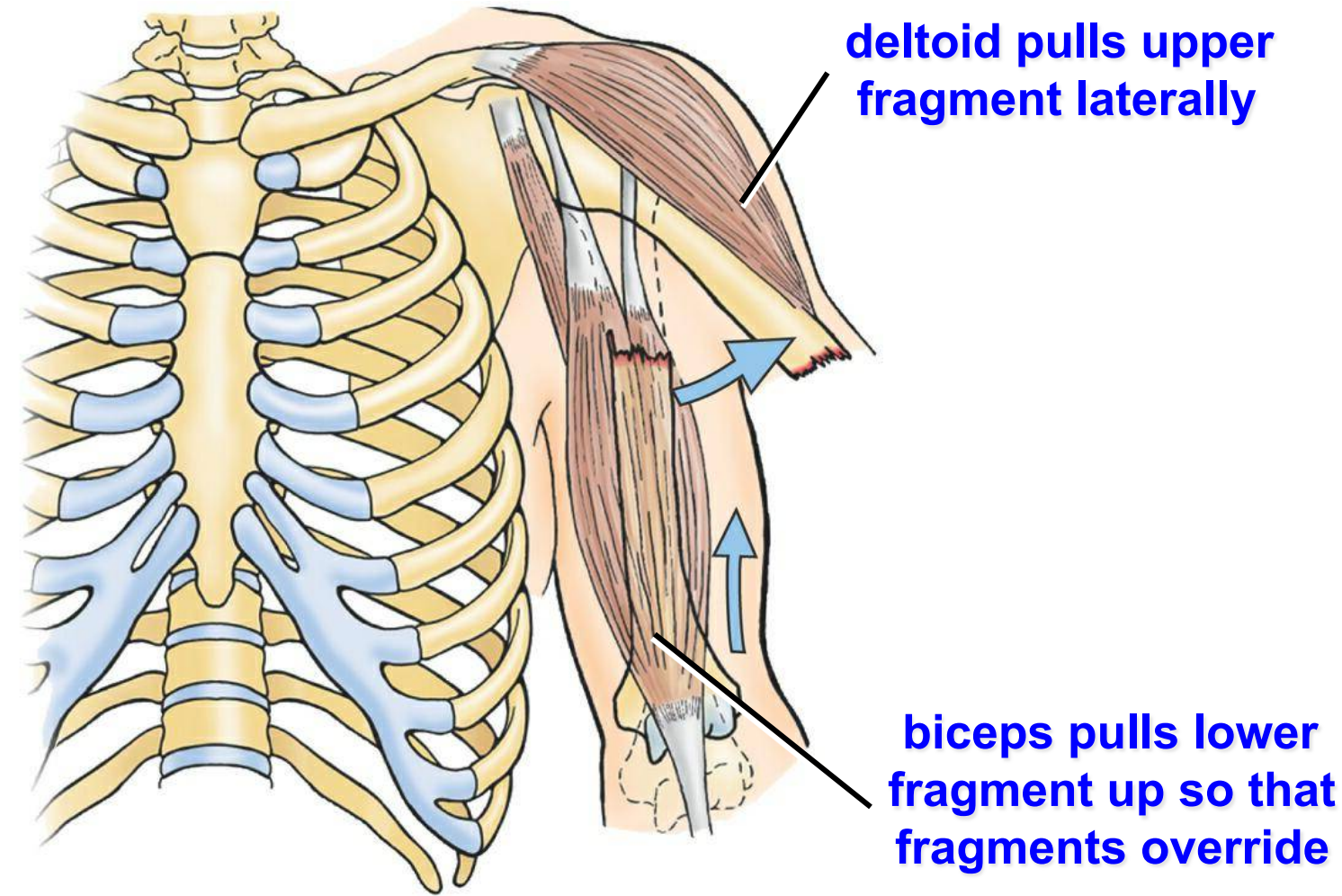
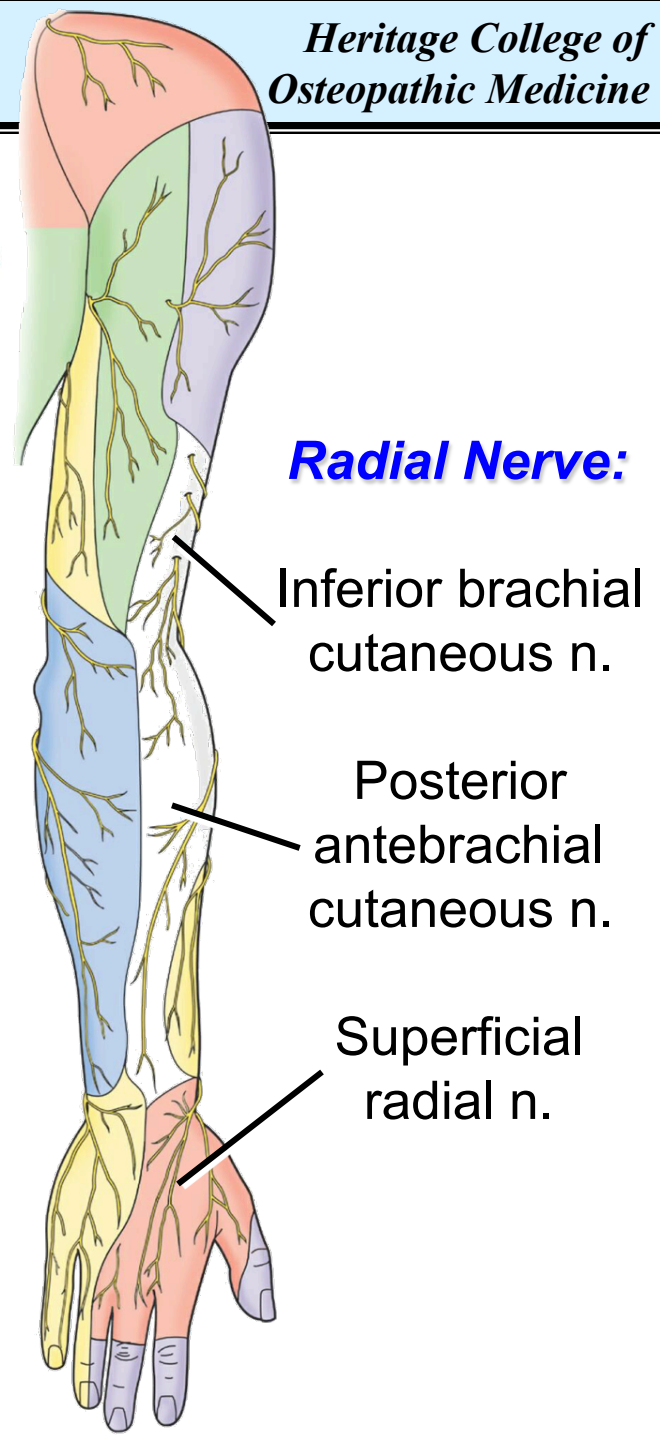
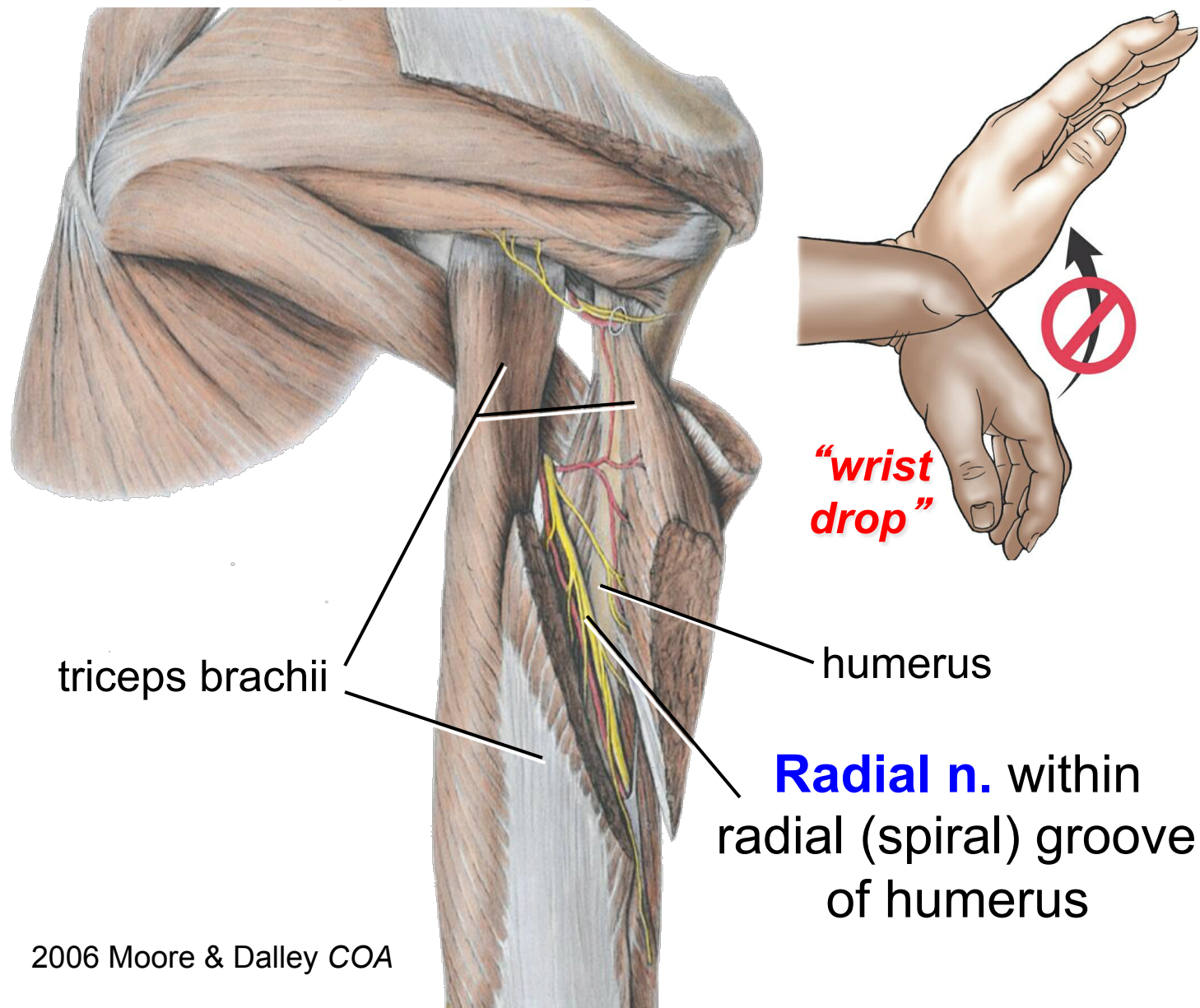


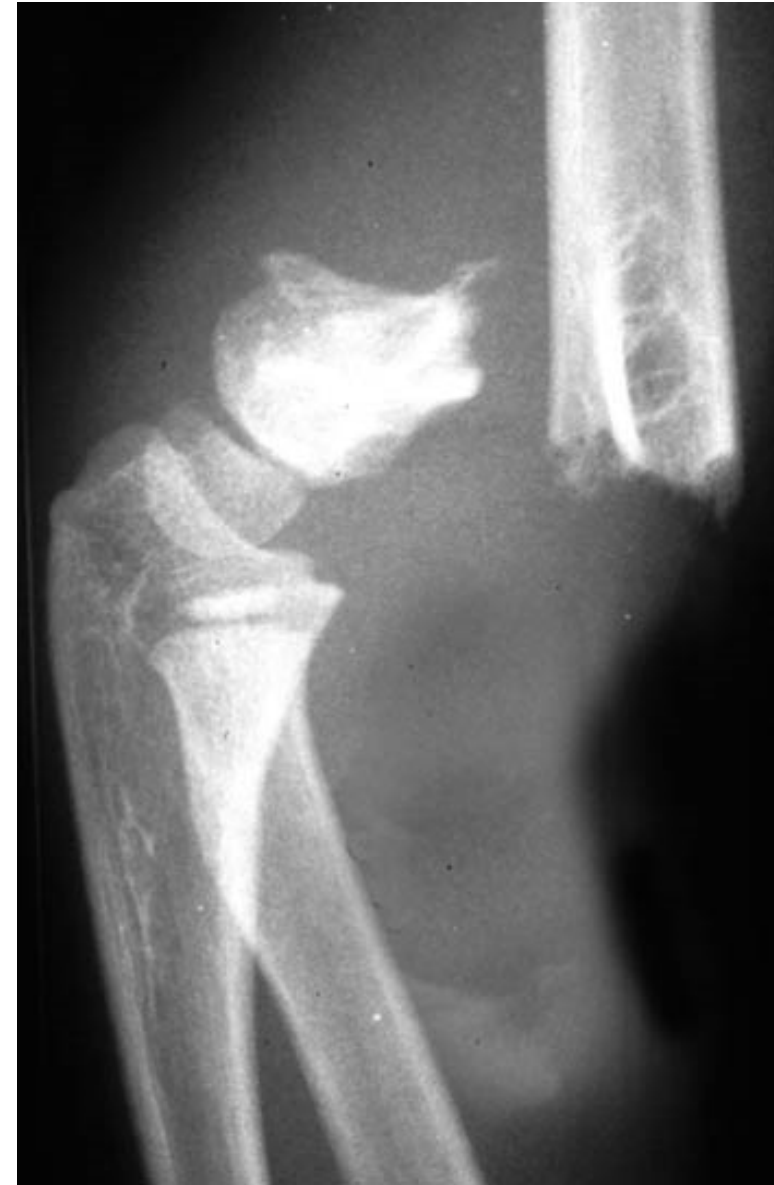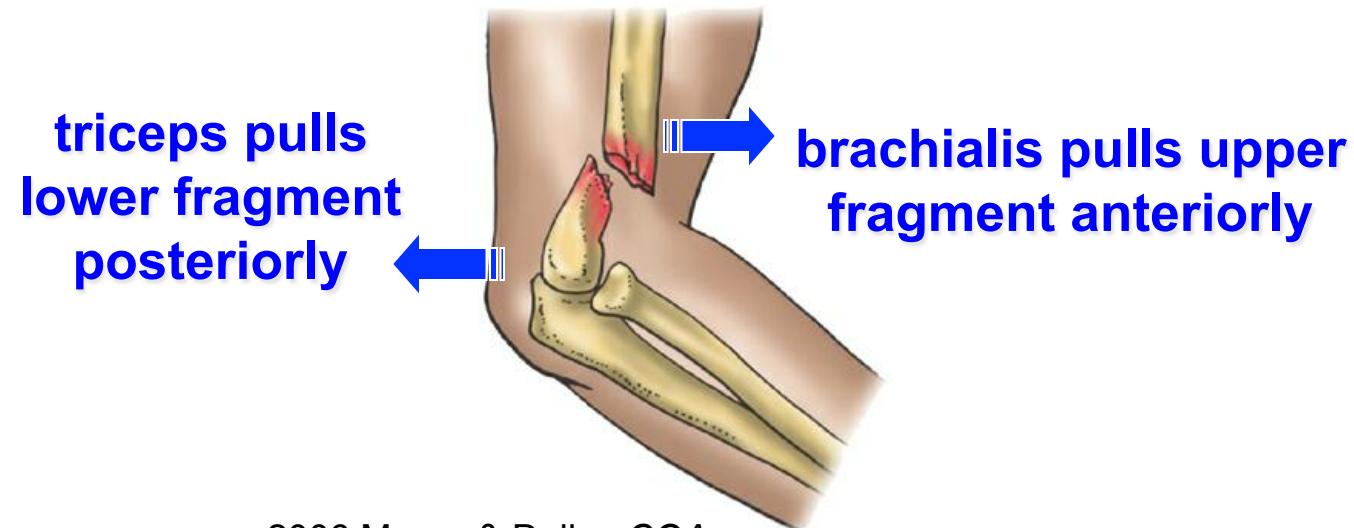
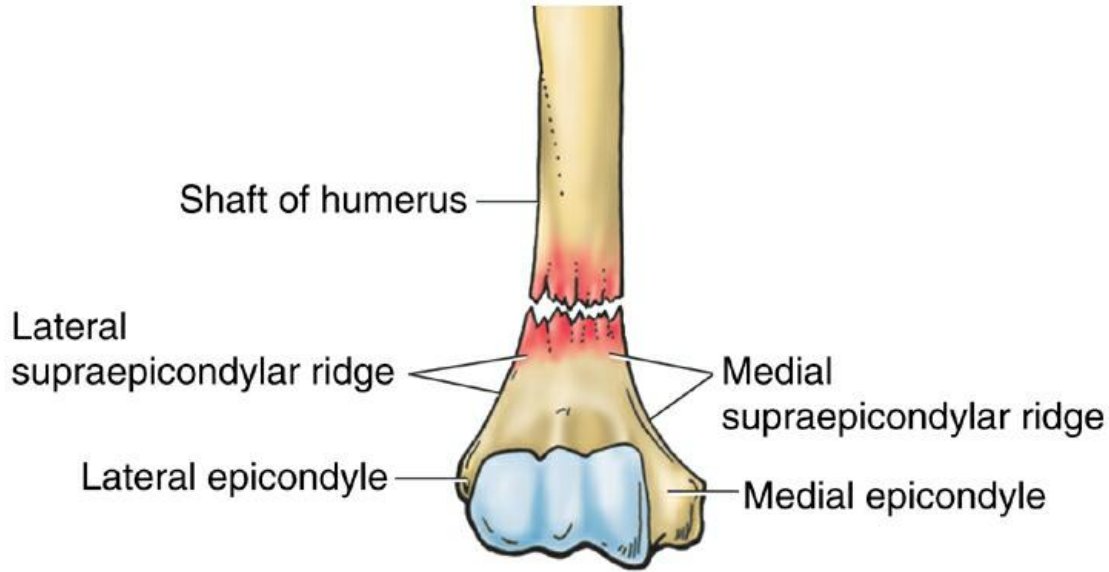
Transverse (Mid-Shaft) Humeral Fractures



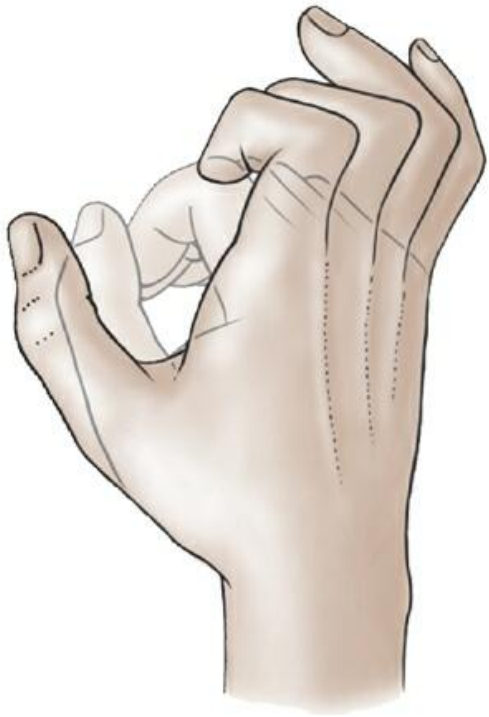
Transverse (Mid-Shaft) Humeral Fractures



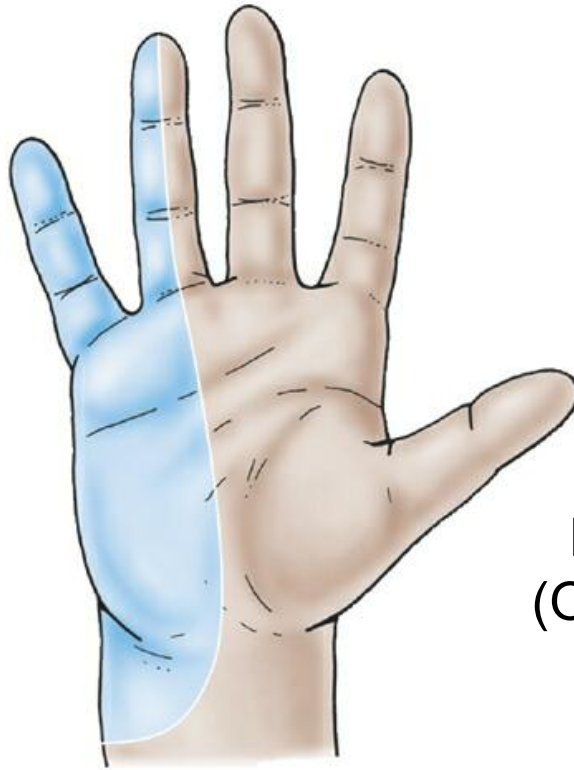
Supracondylar Humeral Fractures



Cubital Tunnel Syndrome



motor deficit
("claw hand")



sensory deficit
(paresthesia)

ulnar nerve
medial
epicondyle
FCU arcade
(Osborne's lig.)
flexor carpi
ulnaris (FCU)

