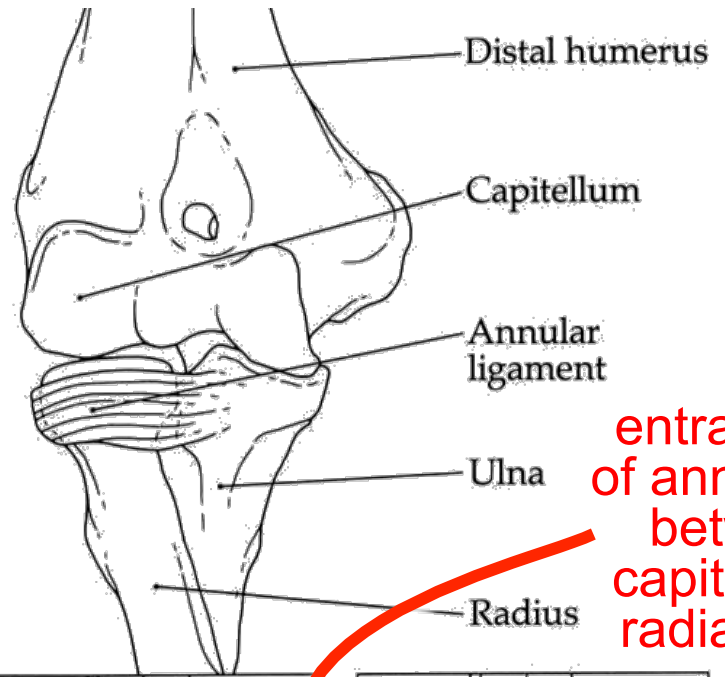


Radial head subluxation ("pulled or nursemaid's elbow")



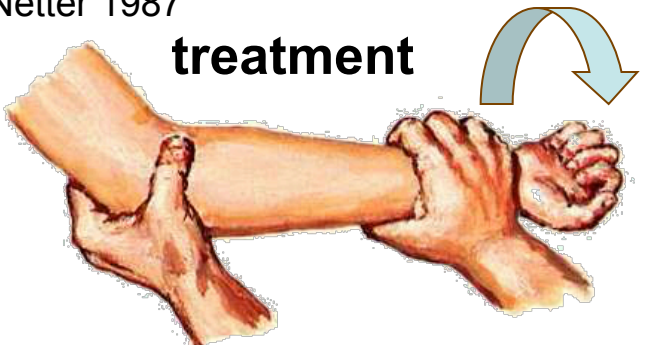
ouch!



entrapment
of annular lig.
between
capitulum &
radial head

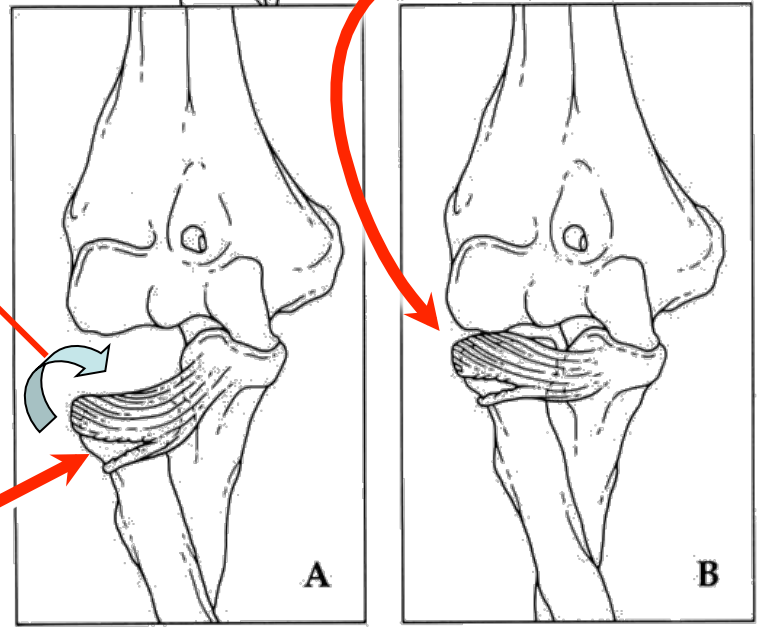
Netter 1987

treatment



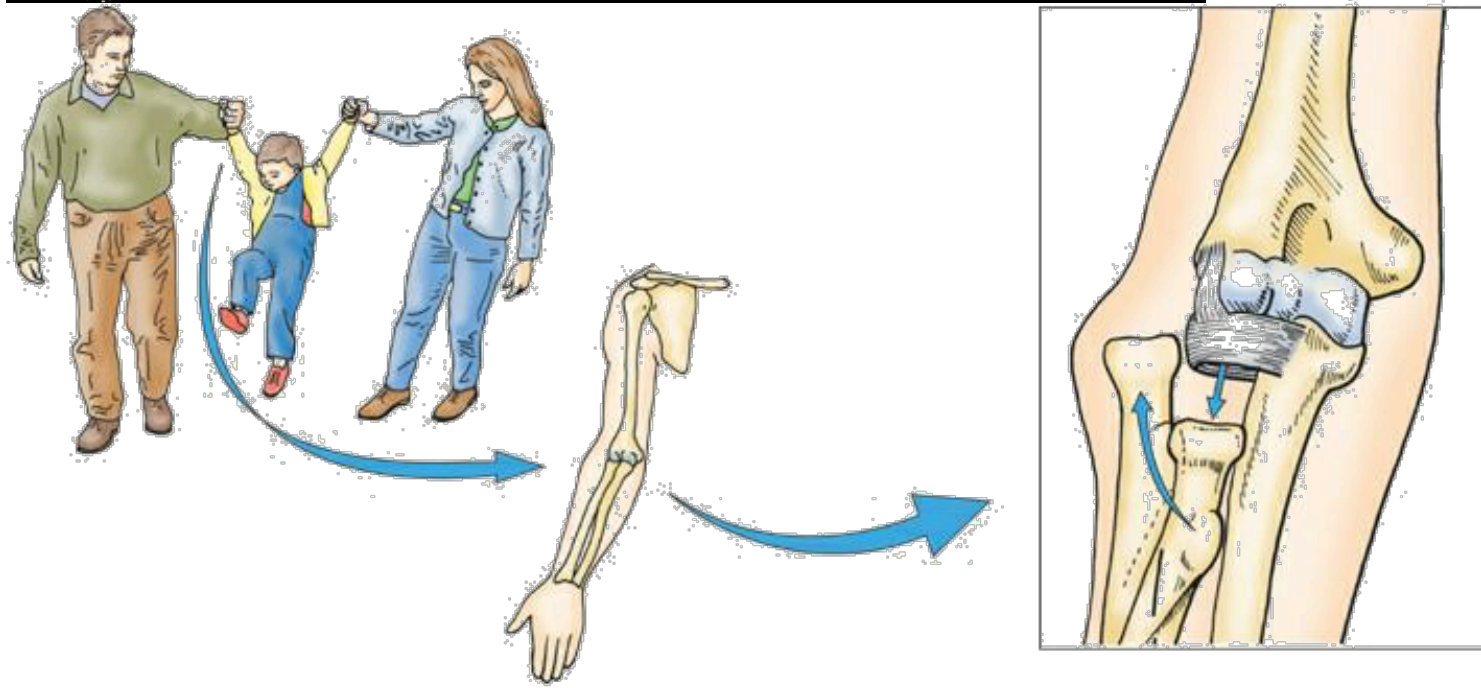
annular lig.
slides
proximally

distal
tear

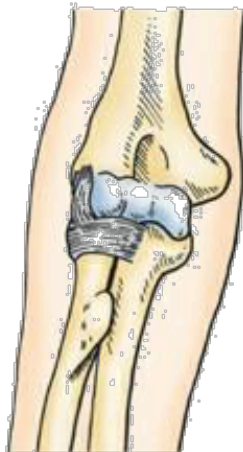

Slaby et al.
1994

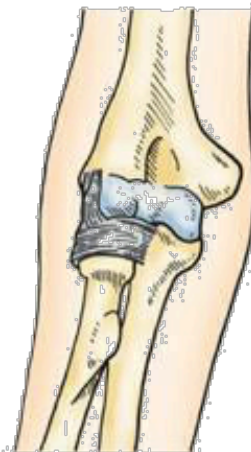Radial head subluxation vs. dislocation



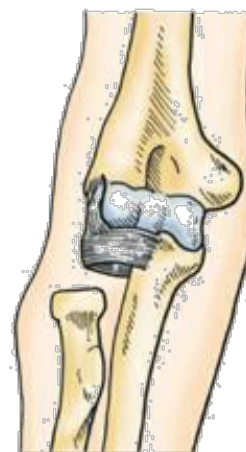subluxation
followed by
dislocation



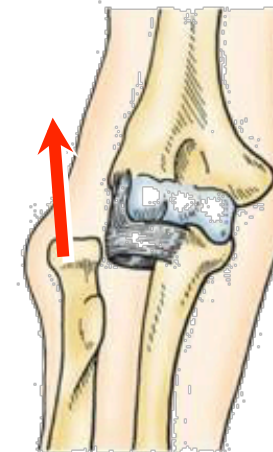
normal



partial subluxation

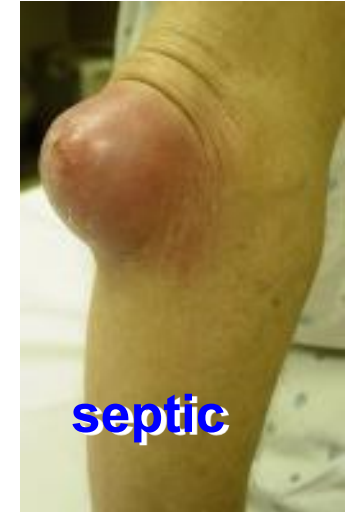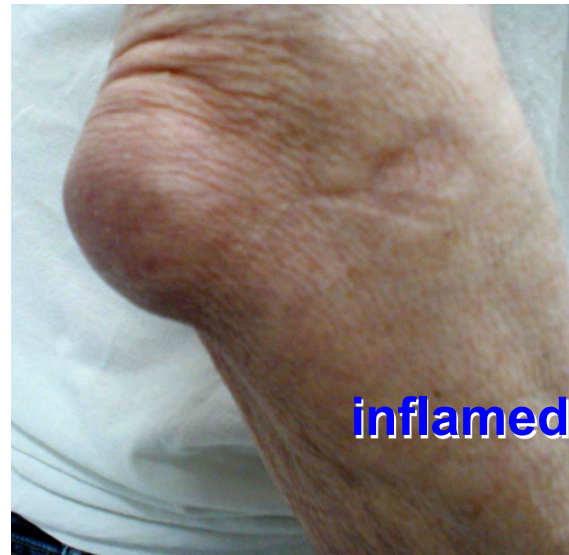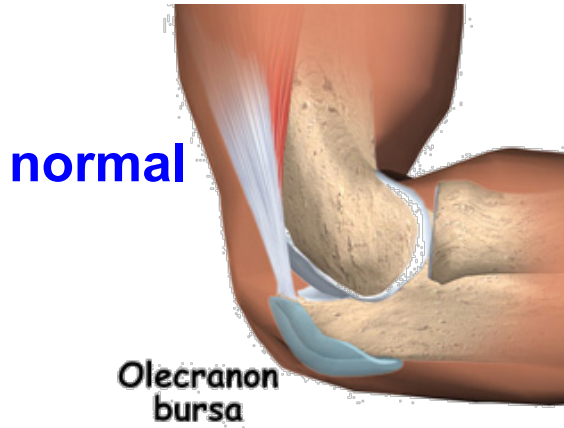


subluxation



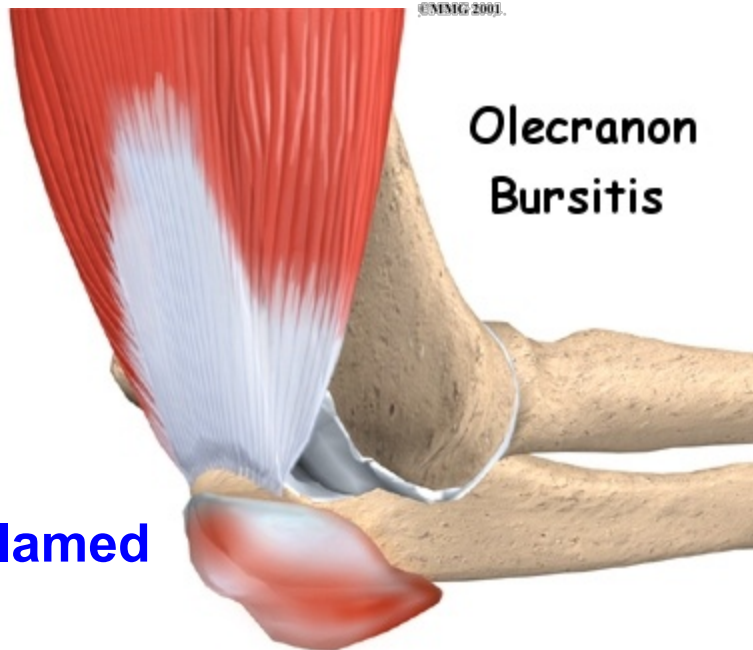
dislocation

Subcutaneous Olecranon Bursitis

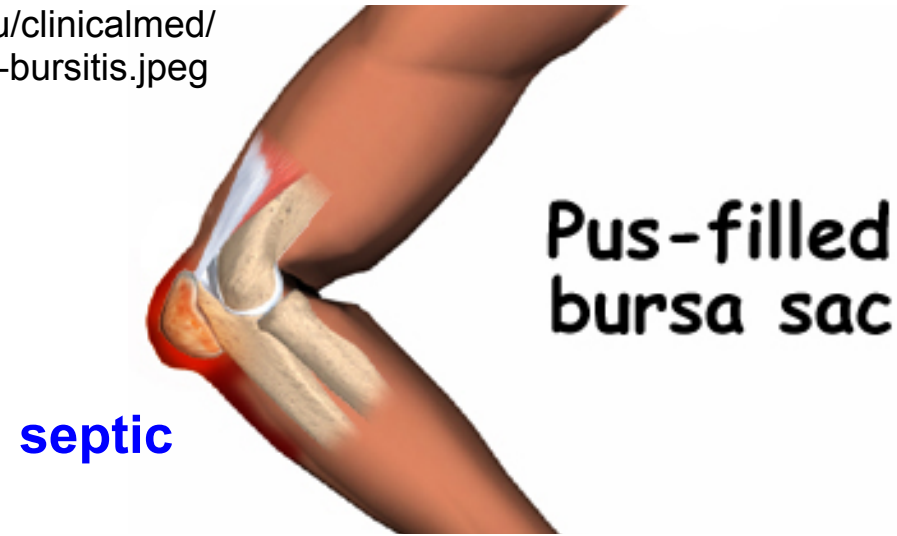


emedicine.com/emerg/images/947Cnv0003-Elbow1.jpg

medicine.ucsd.edu/clinicalmed/upper-olechronon-bursitis.jpeg

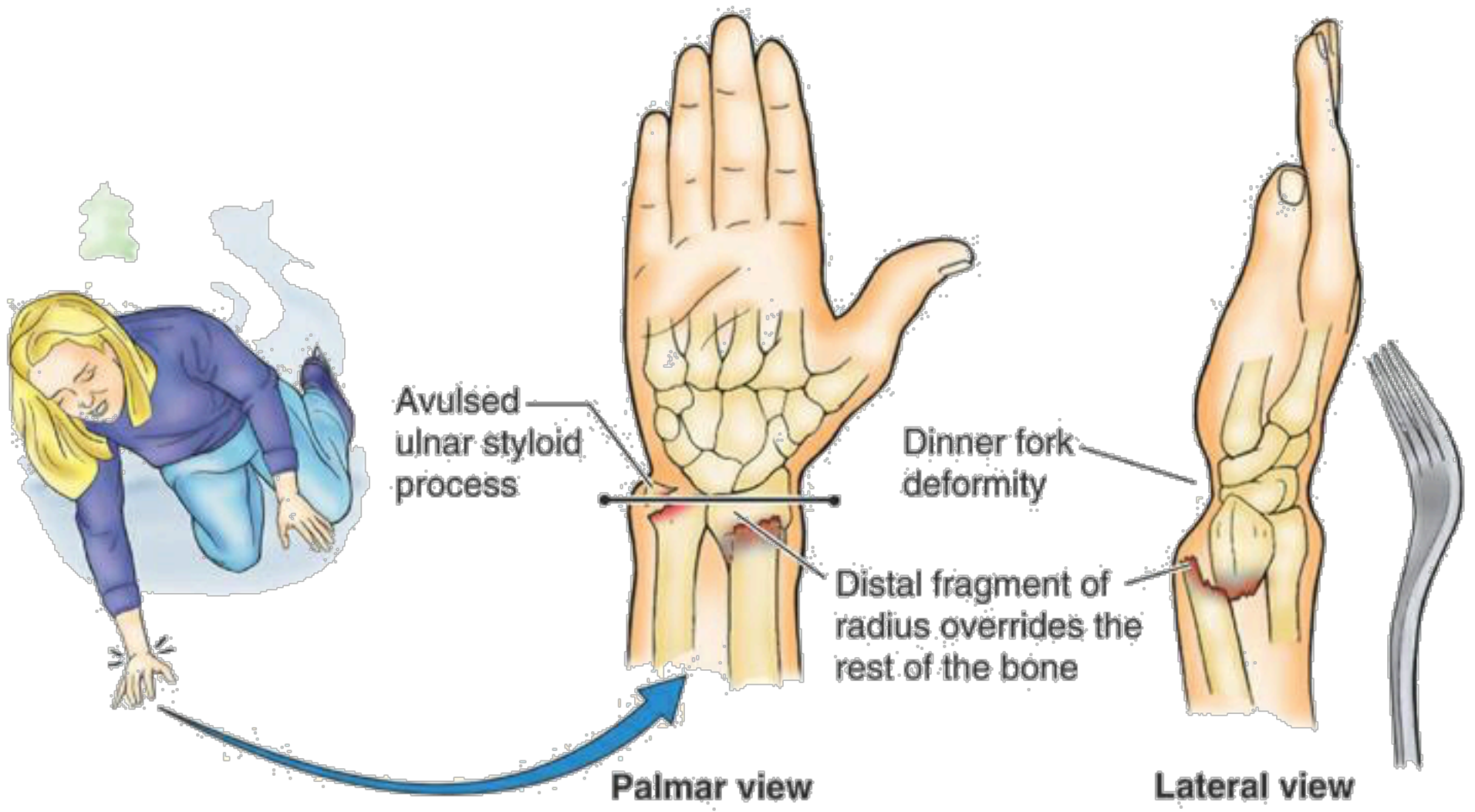


eorthopod.com/images/ContentImages/elbow/elbow_bursitis/elbow_bursitis_intro01.jpg

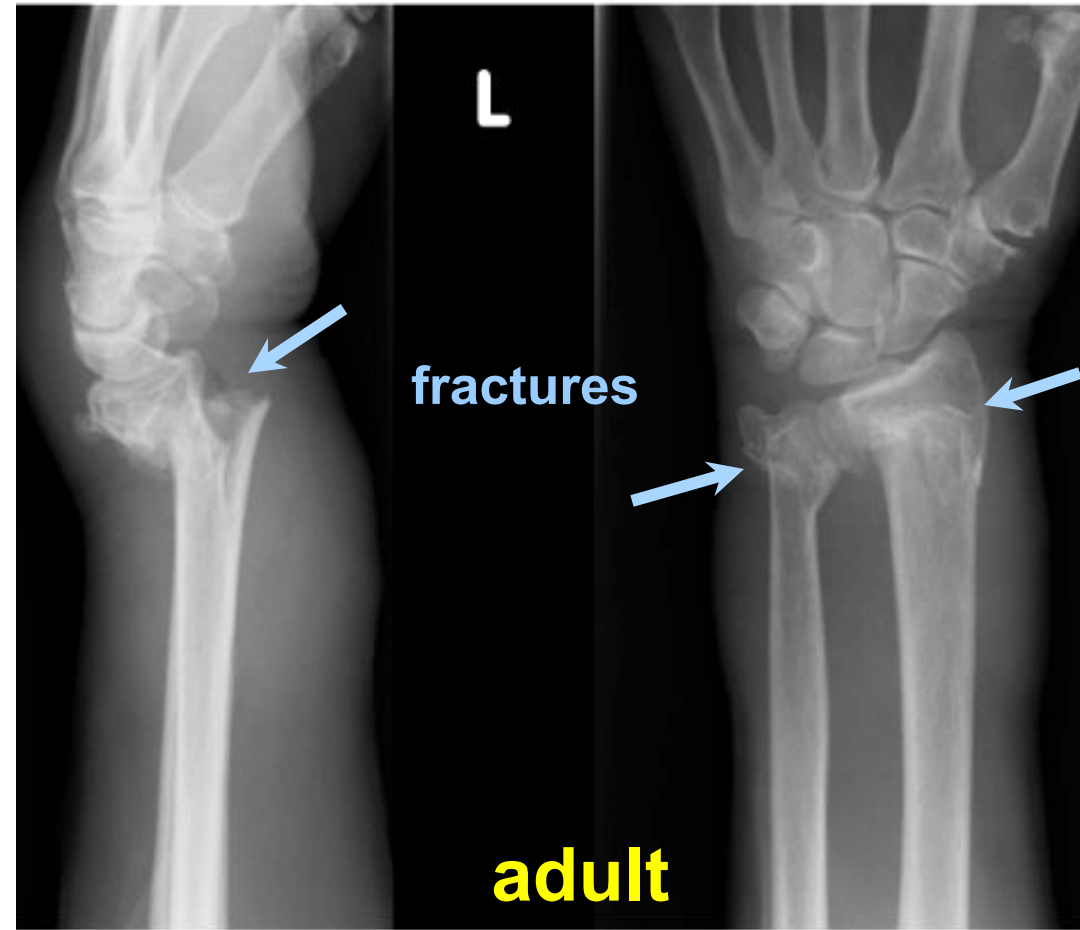


eorthopod.com/images/ContentImages/elbow/elbow_bursitis/elbow_bursitis_cause02.jpg

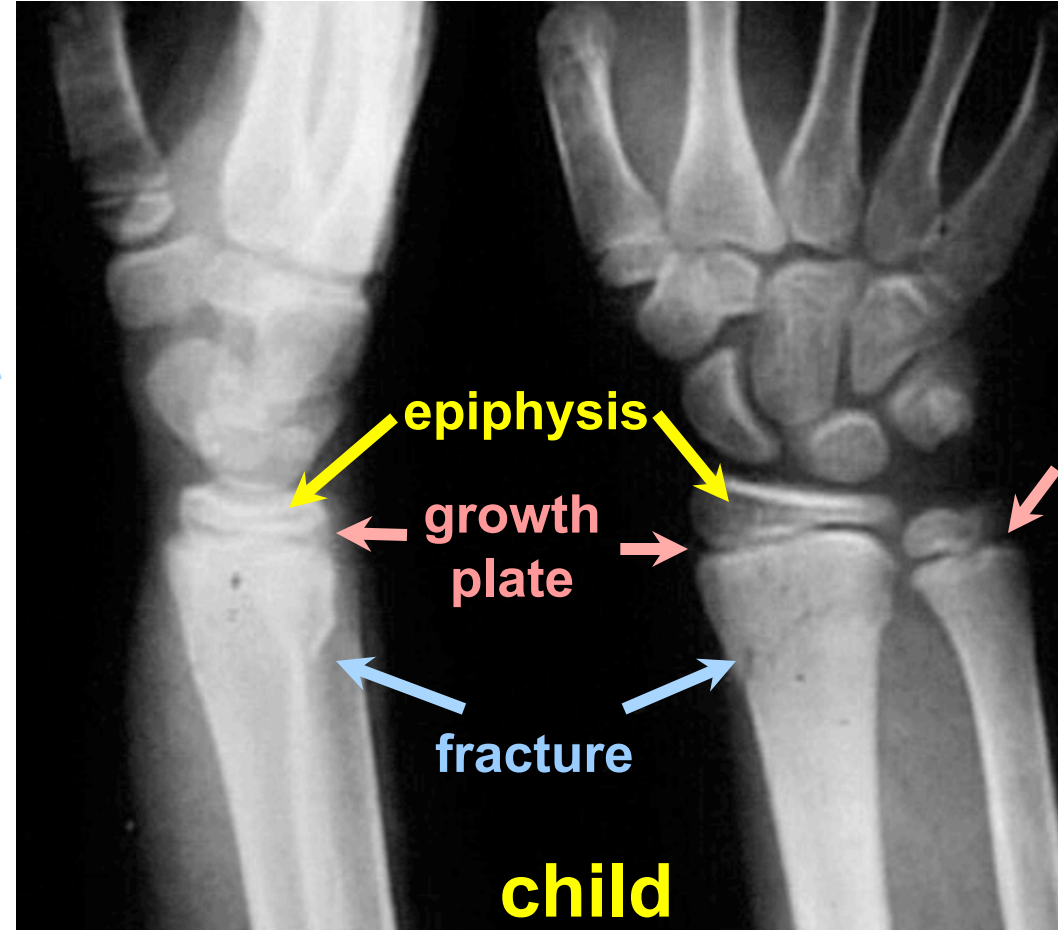
Colles Fracture



Colles Fracture



www.e-radiography.net/ibase5/Wrist/slides/Wrist_colles.jpg



[anatomy.med.umich.edu/radiology/
upper_limb/wrist_colles_fracture.jpeg](http://anatomy.med.umich.edu/radiology/upper_limb/wrist_colles_fracture.jpeg)