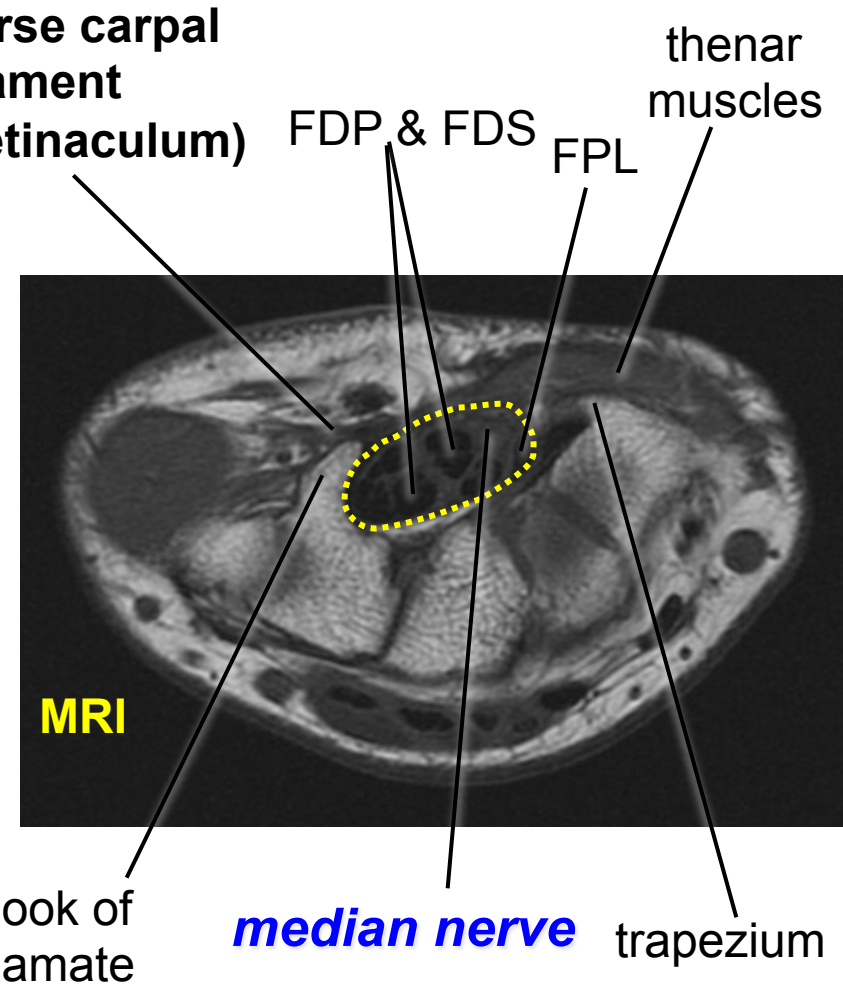
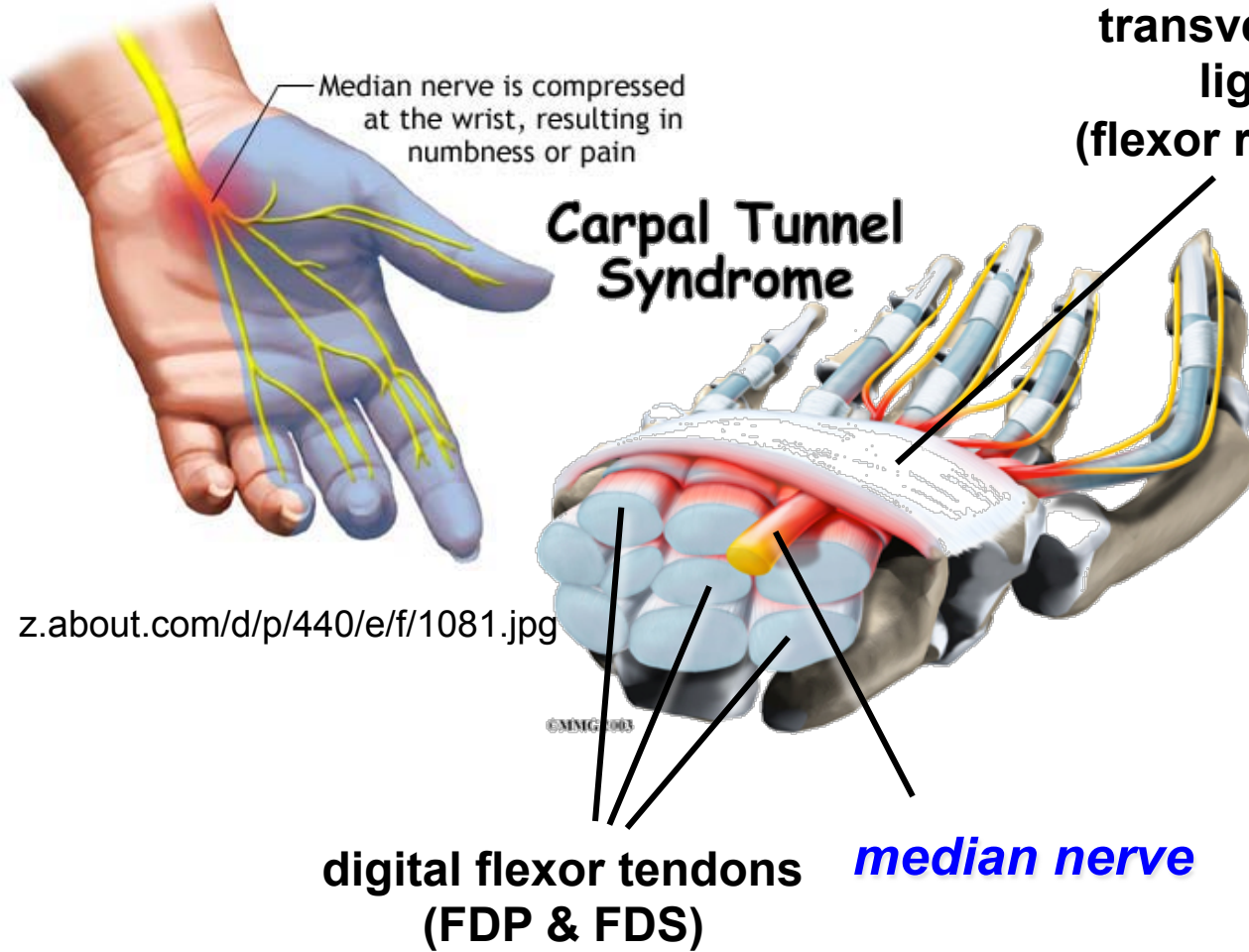


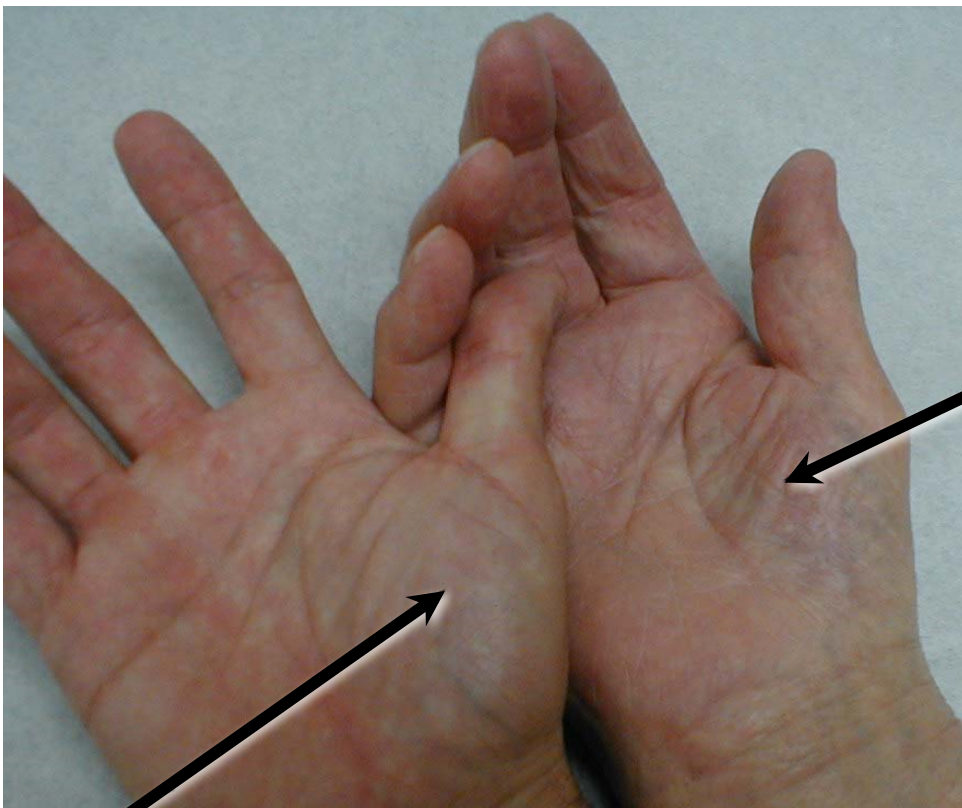
Carpal Tunnel Syndrome



eorthopod.com/images/ContentImages/hand/hand_carpal_tunnel/hand_carpal_tunnel_intro01.jpg

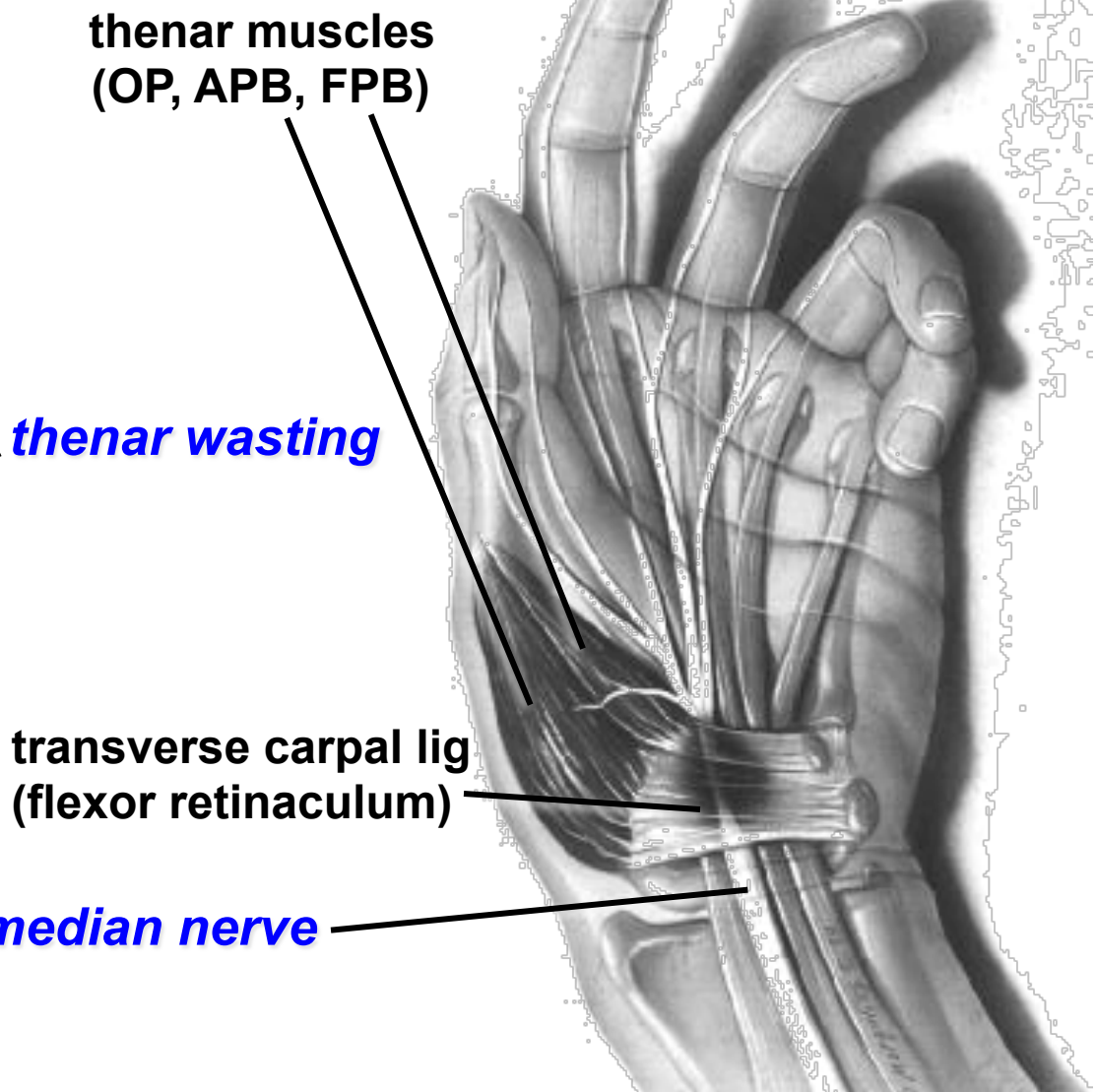
dartmouth.edu/~anatomy/Figures/Upper%20Extremity%20images/Wrist/Axial%20MRI/3/wrist3unlabeled.jpg

Carpal Tunnel Syndrome



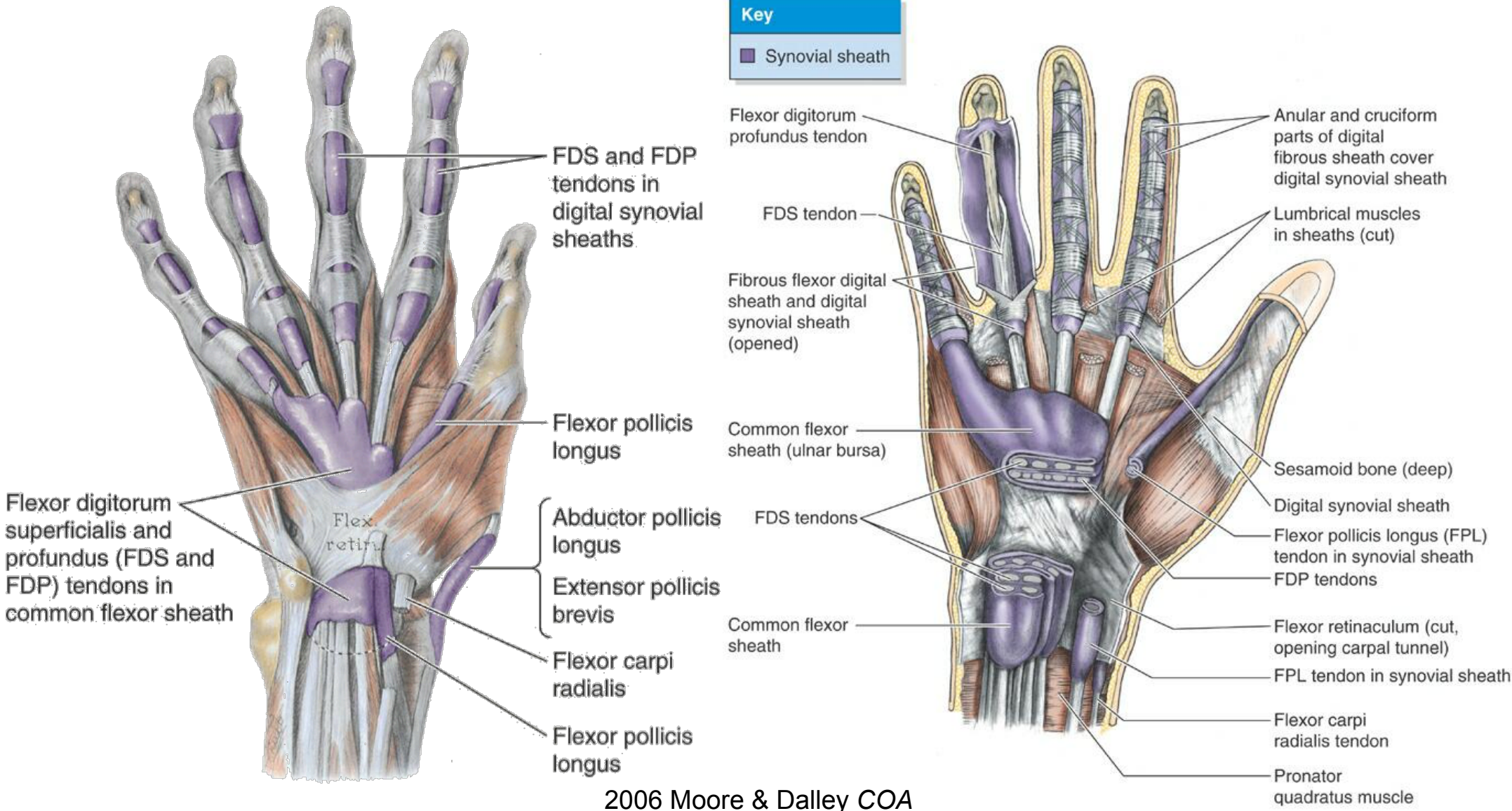
normal thenar eminence

medicine.ucsd.edu/clinicalimg/Upper-CTS.jpg



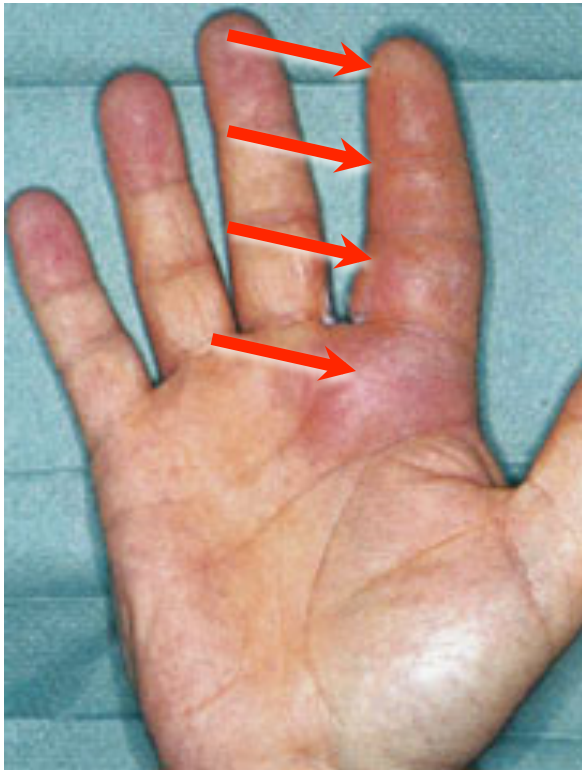www.faqs.org/health/images/uchr_06_img0627.jpg

Tenosynovitis



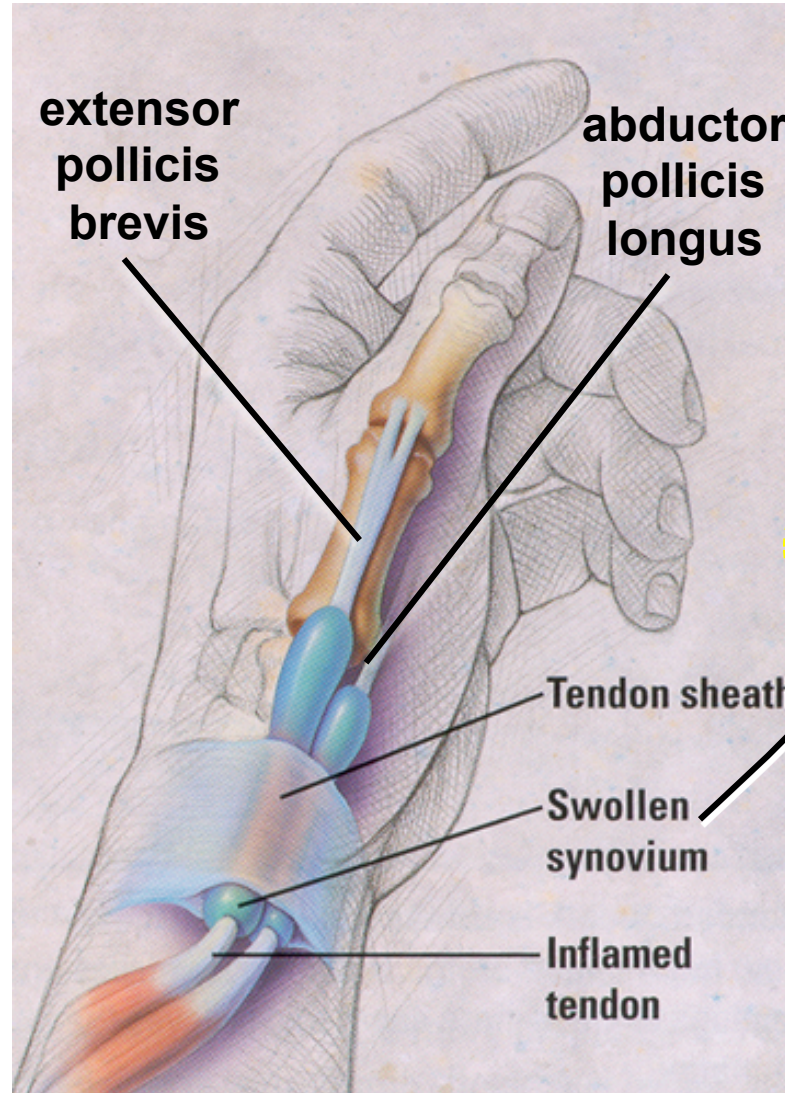
Tenosynovitis

Tenosynovitis of index finger

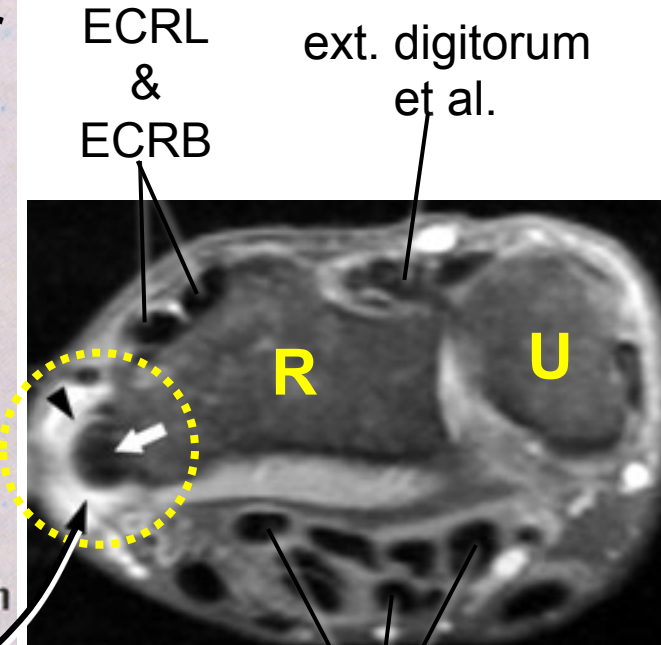


aafp.org/afp/20031201/2167_f8.jpg

De Quervain's Tenosynovitis (tenosynovitis of APL & EPB)



theqi.com/cmed/misc/images/teno.jpg



digital flexor tendons (FDP & FDS)

www.radsourc.us/rf/RADS/images/09-2004-Findings-A.jpg