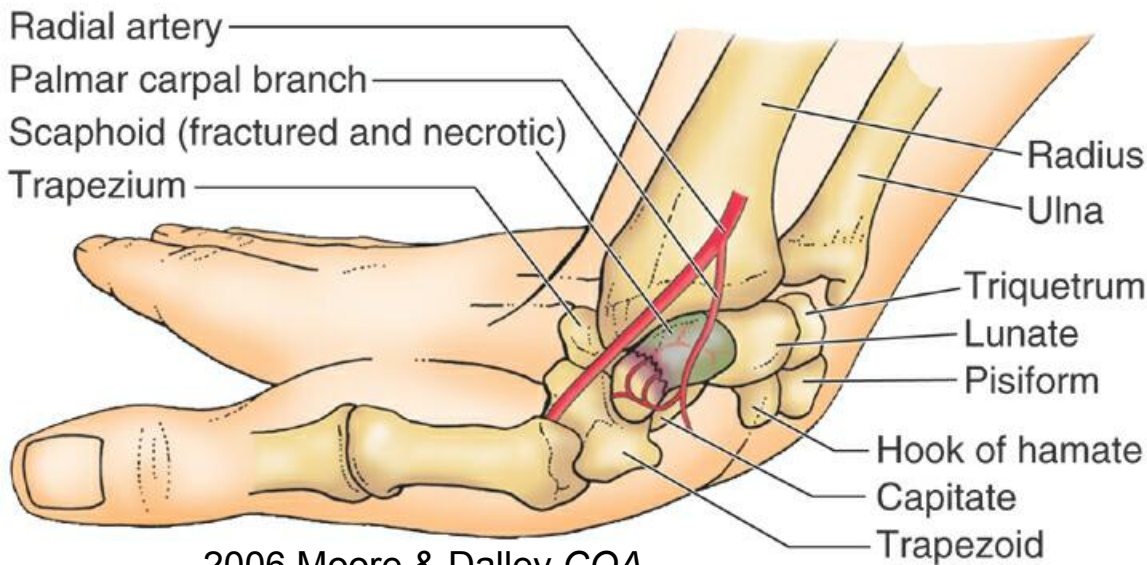
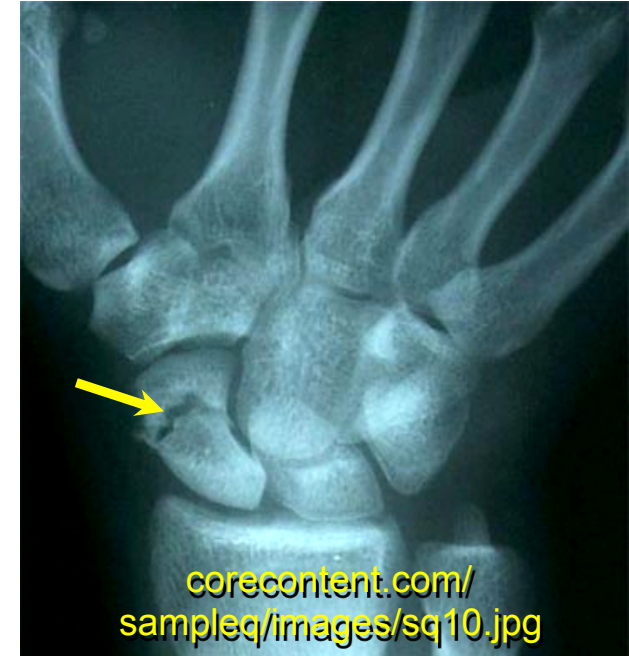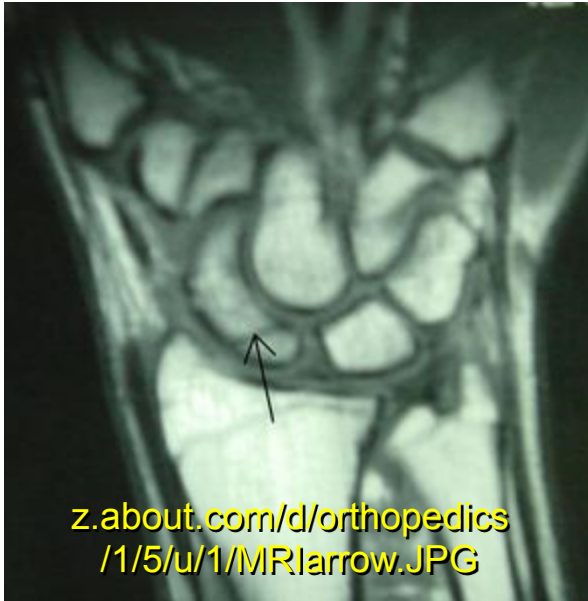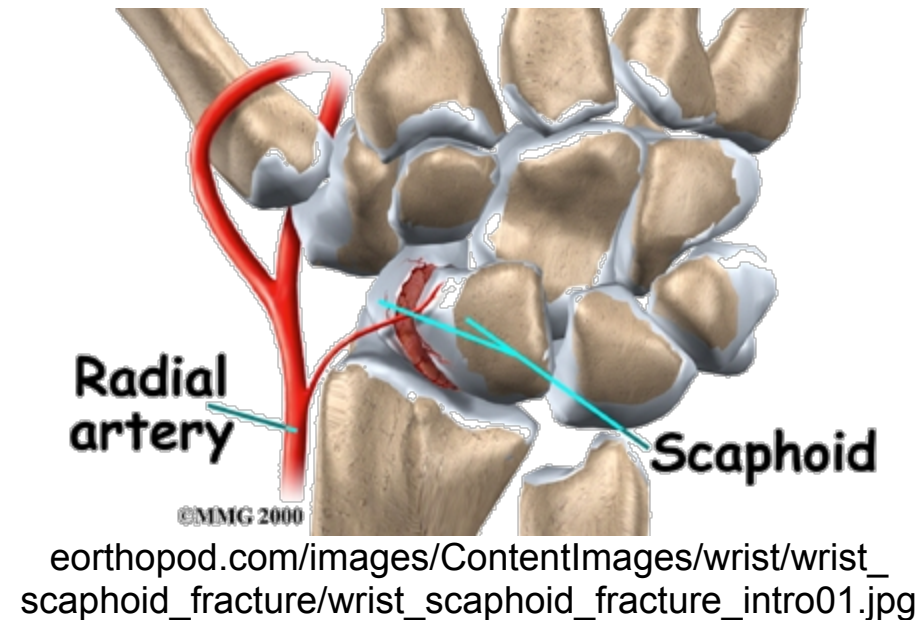


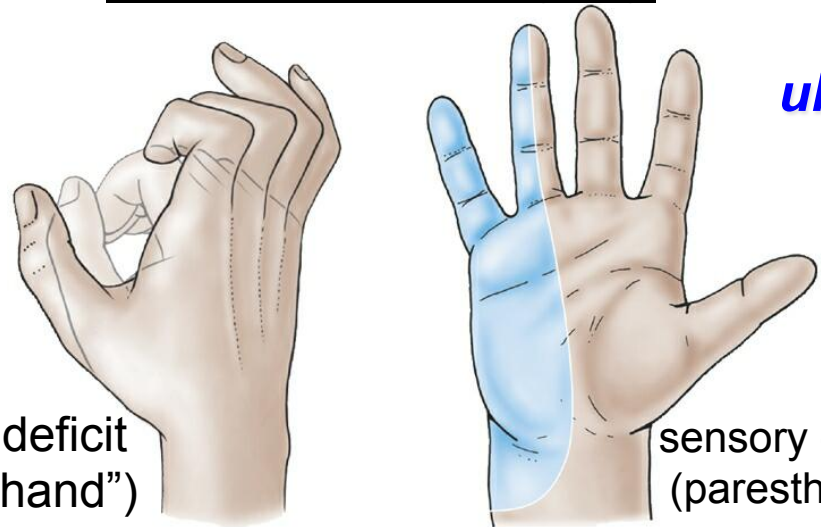
Scaphoid Fracture & Avascular Necrosis



2006 Moore & Dalley COA



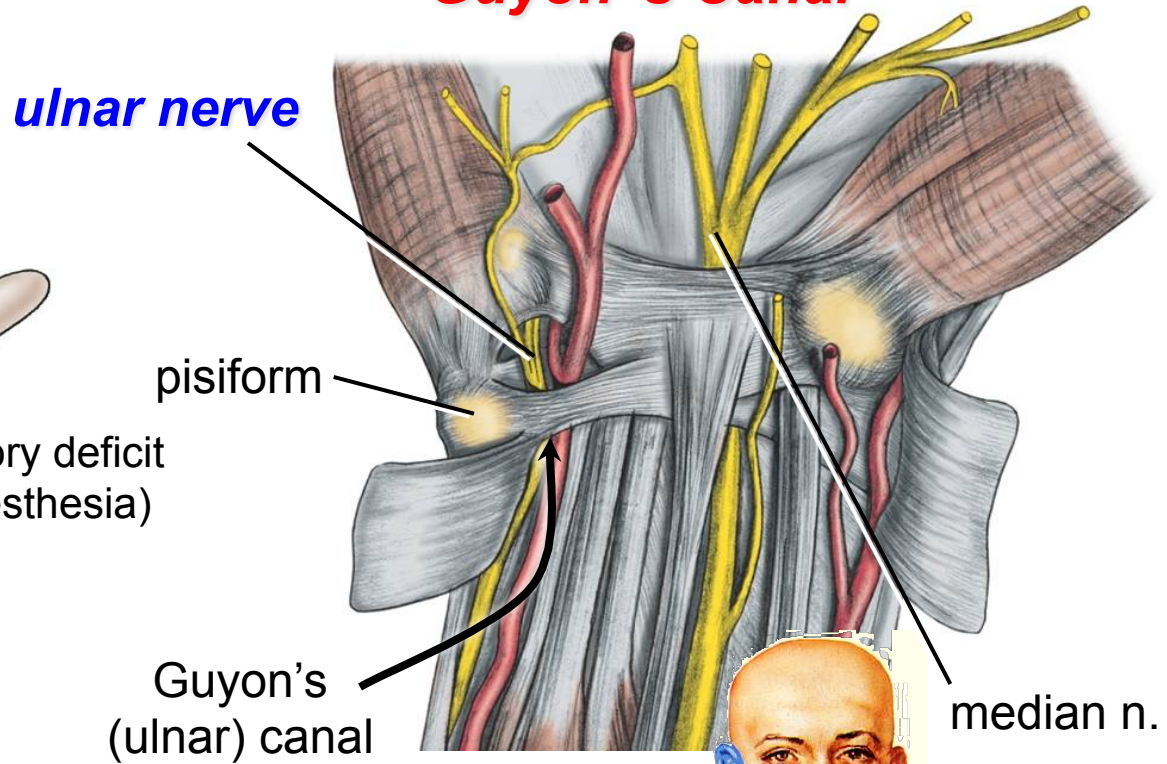
Ulnar Nerve Injury



motor deficit
("claw hand")

sensory deficit
(paresthesia)

Guyon's Canal



ulnar nerve

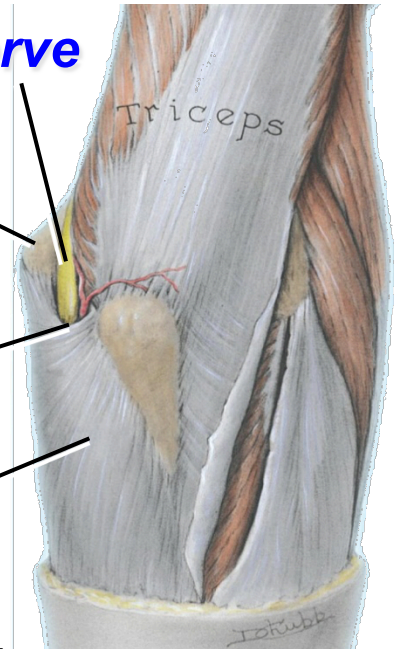
pisiform

Guyon's
(ulnar) canal

median n.

Cubital Tunnel

ulnar nerve

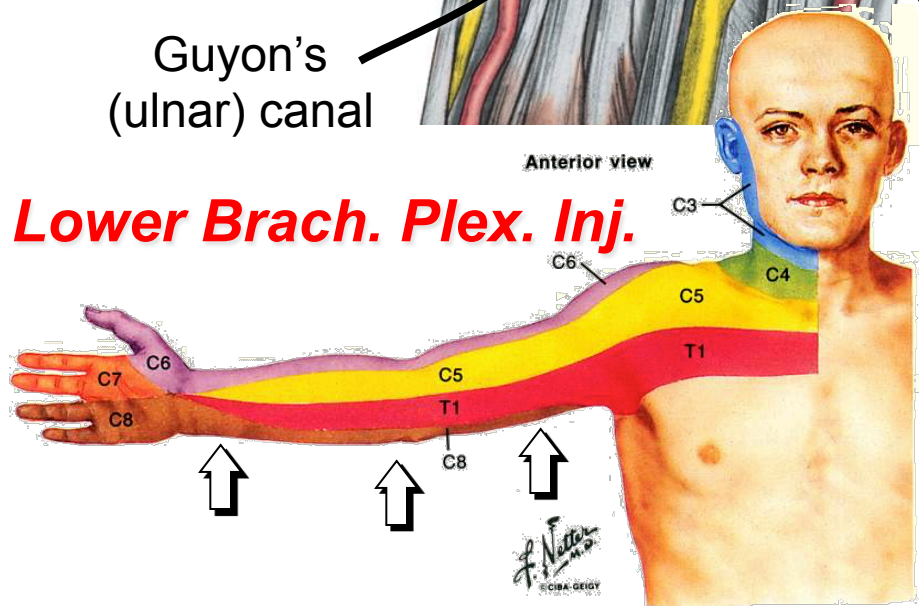


medial epicondyle

FCU arcade
(Osborne's lig.)

flexor carpi ulnaris (FCU)

Lower Brach. Plex. Inj.



Anterior view

C3

C4

C5

T1

C6

C7

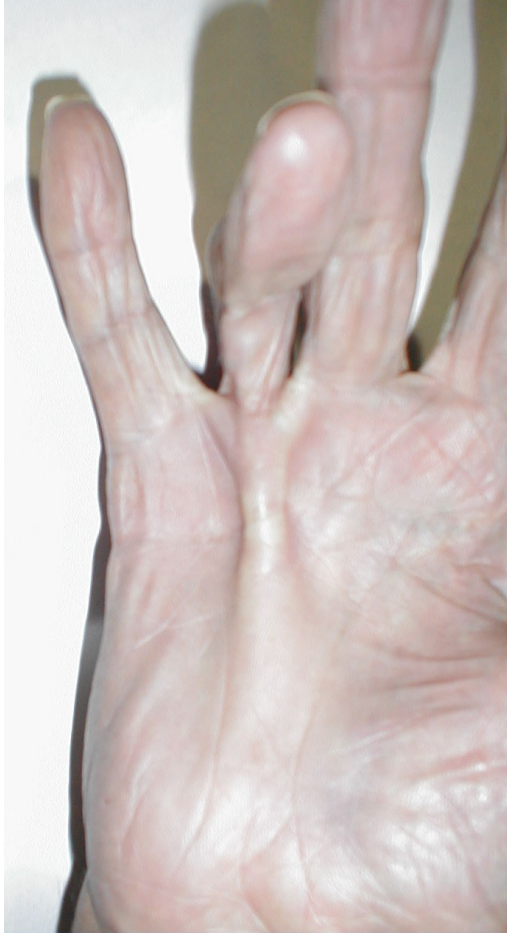C8

C5

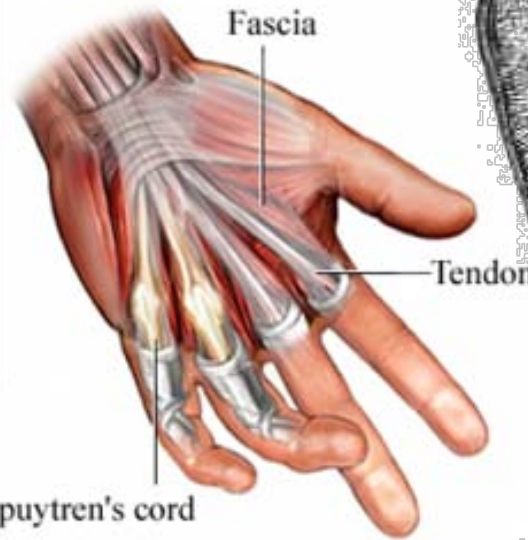
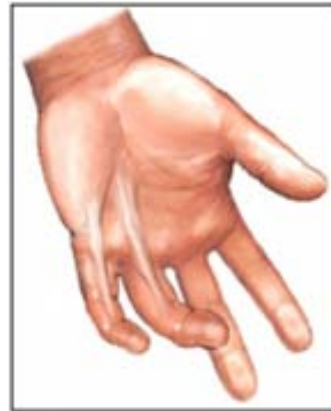T1

C8

Dupuytren's Contracture

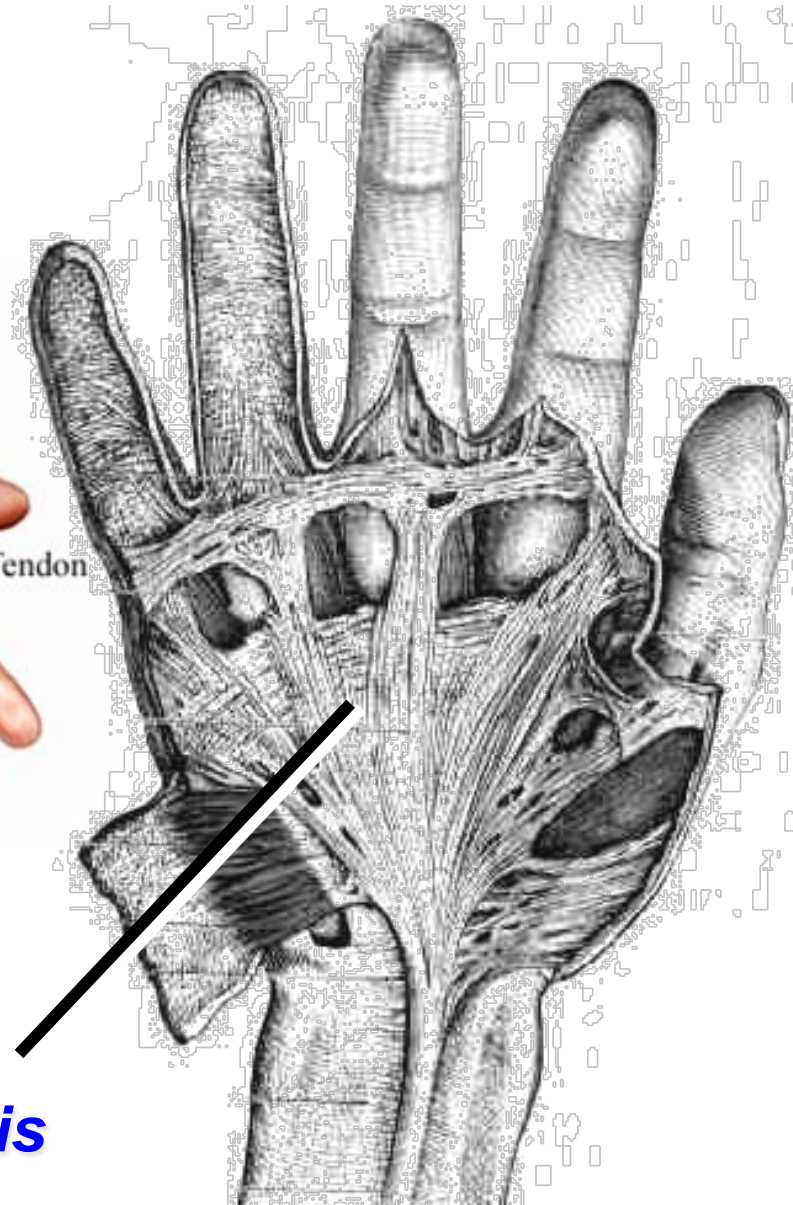


[medicine.ucsd.edu/clinicalimg/
Extremities-Dupuytren's.jpg](http://medicine.ucsd.edu/clinicalimg/Extremities-Dupuytren's.jpg)



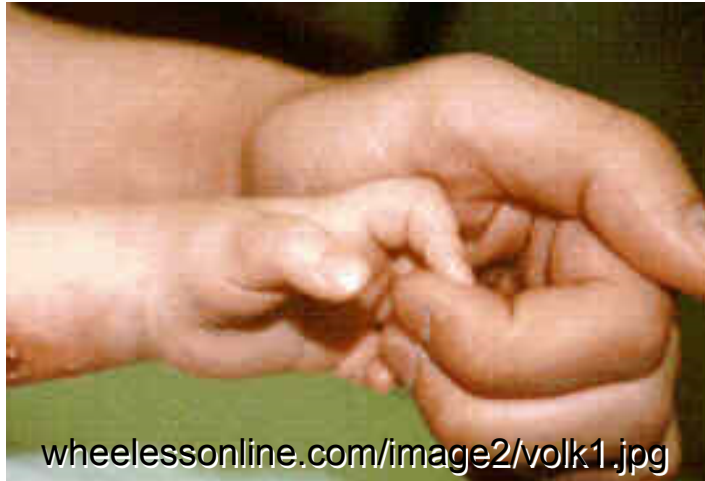[healthgate.partners.org/images
/si55551480_ma.jpg](http://healthgate.partners.org/images/si55551480_ma.jpg)

**palmar
aponeurosis**

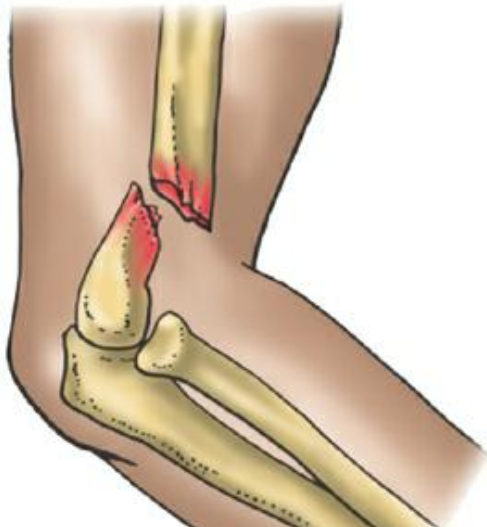

whelessonline.com/image4/hand5.jpg

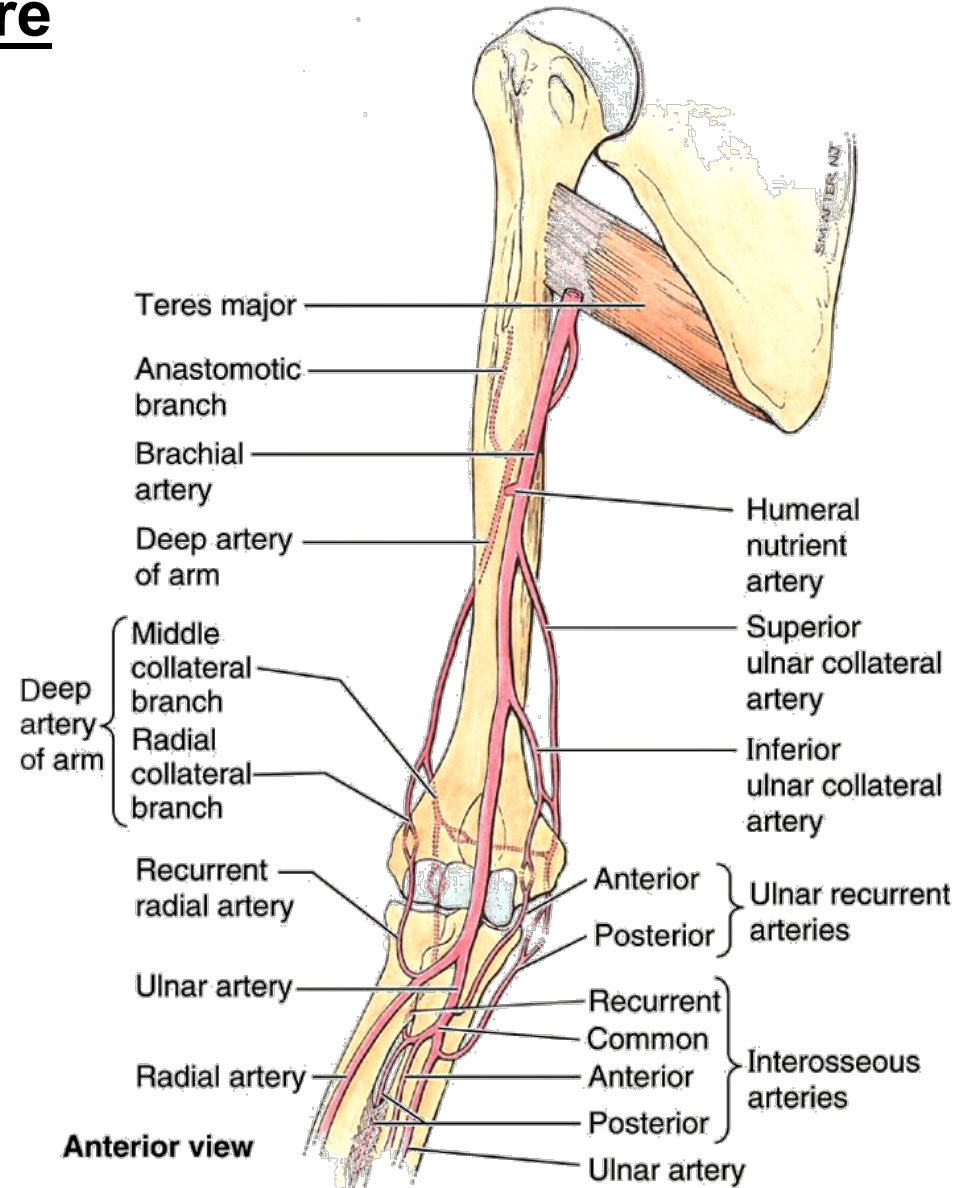
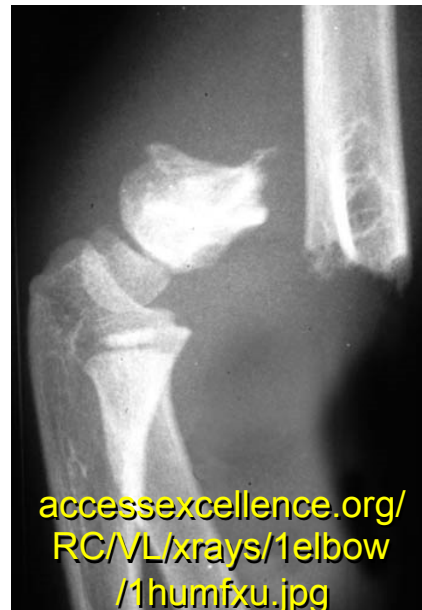Volkmann's Ischemic Contracture



supracondylar humeral fracture



2006 Moore & Dalley COA



2006 Moore & Dalley COA