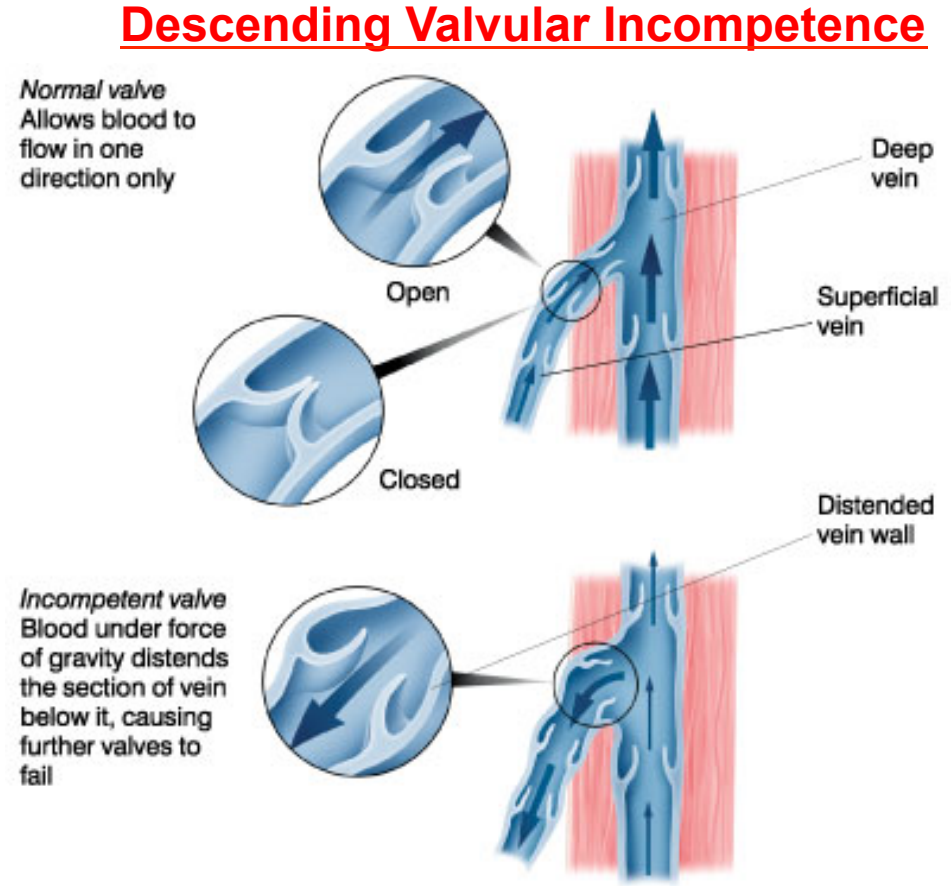
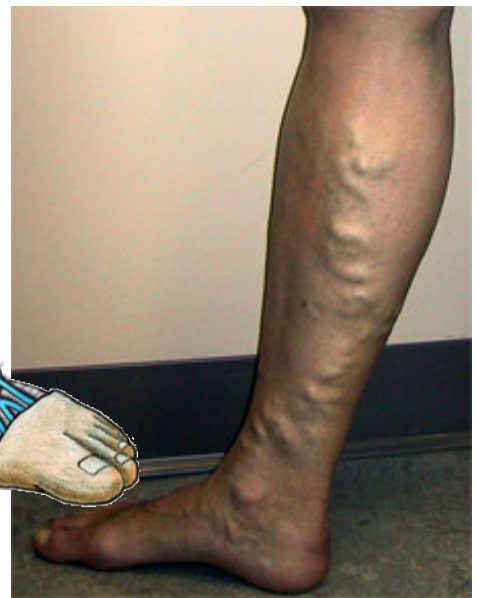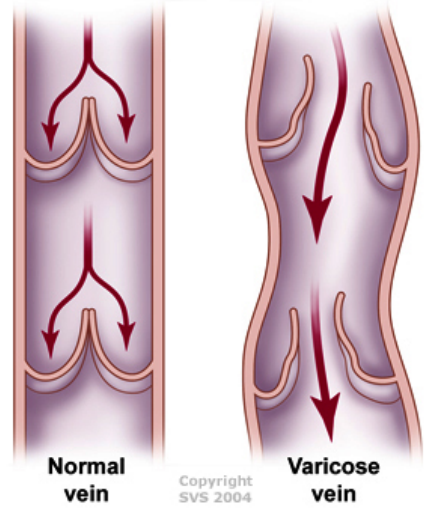
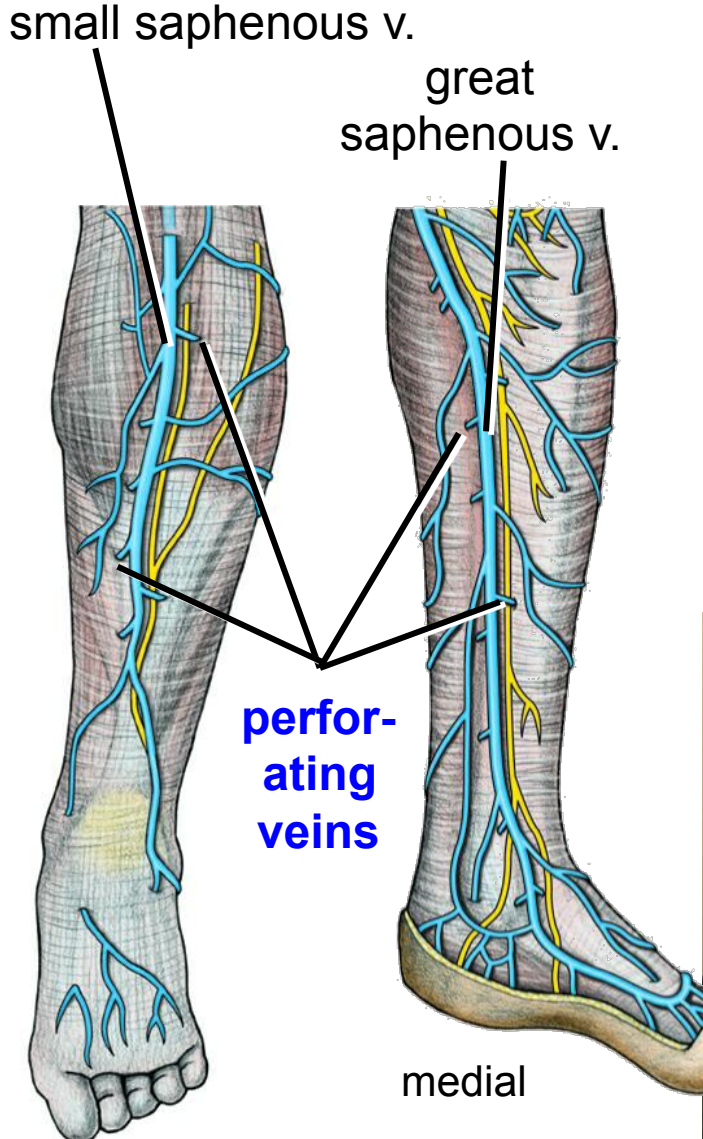


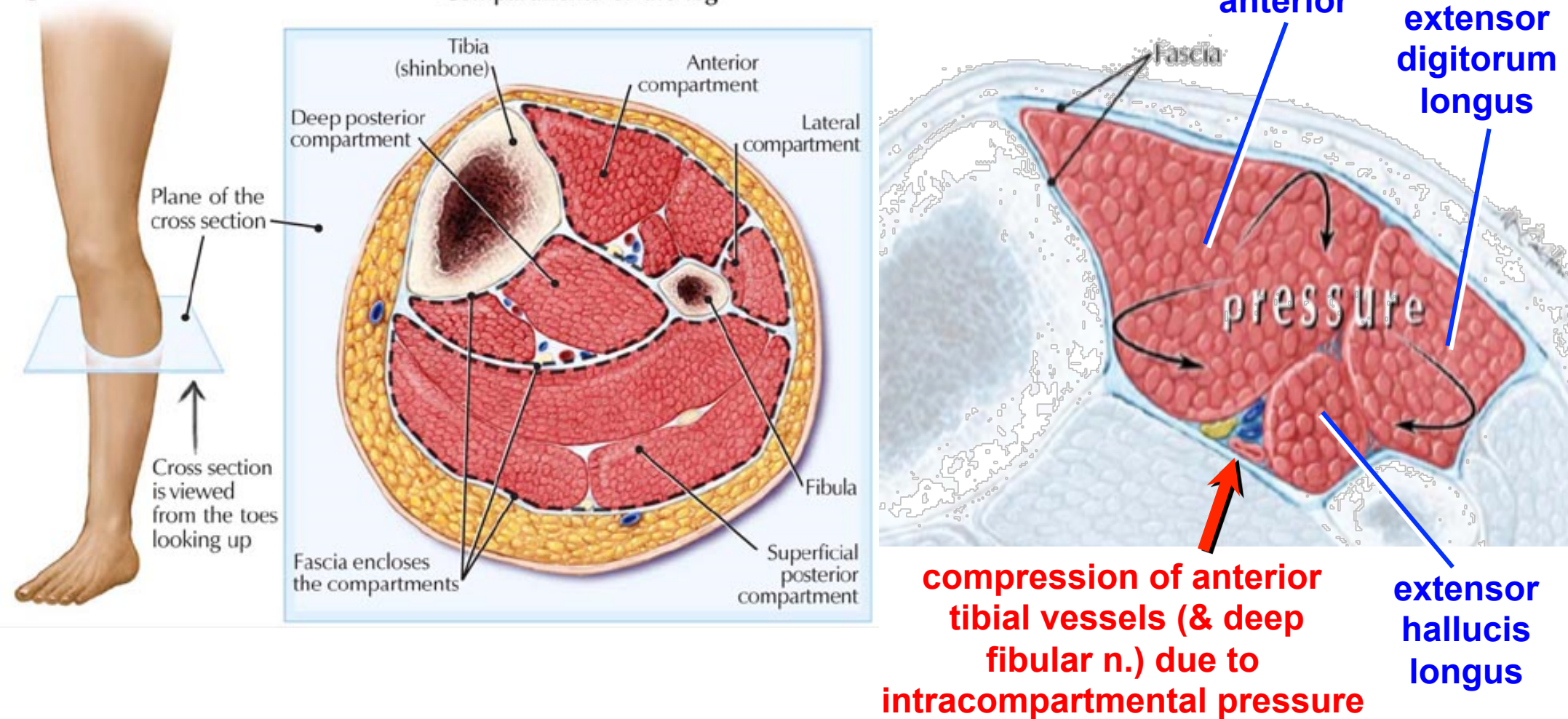
Varicose Veins



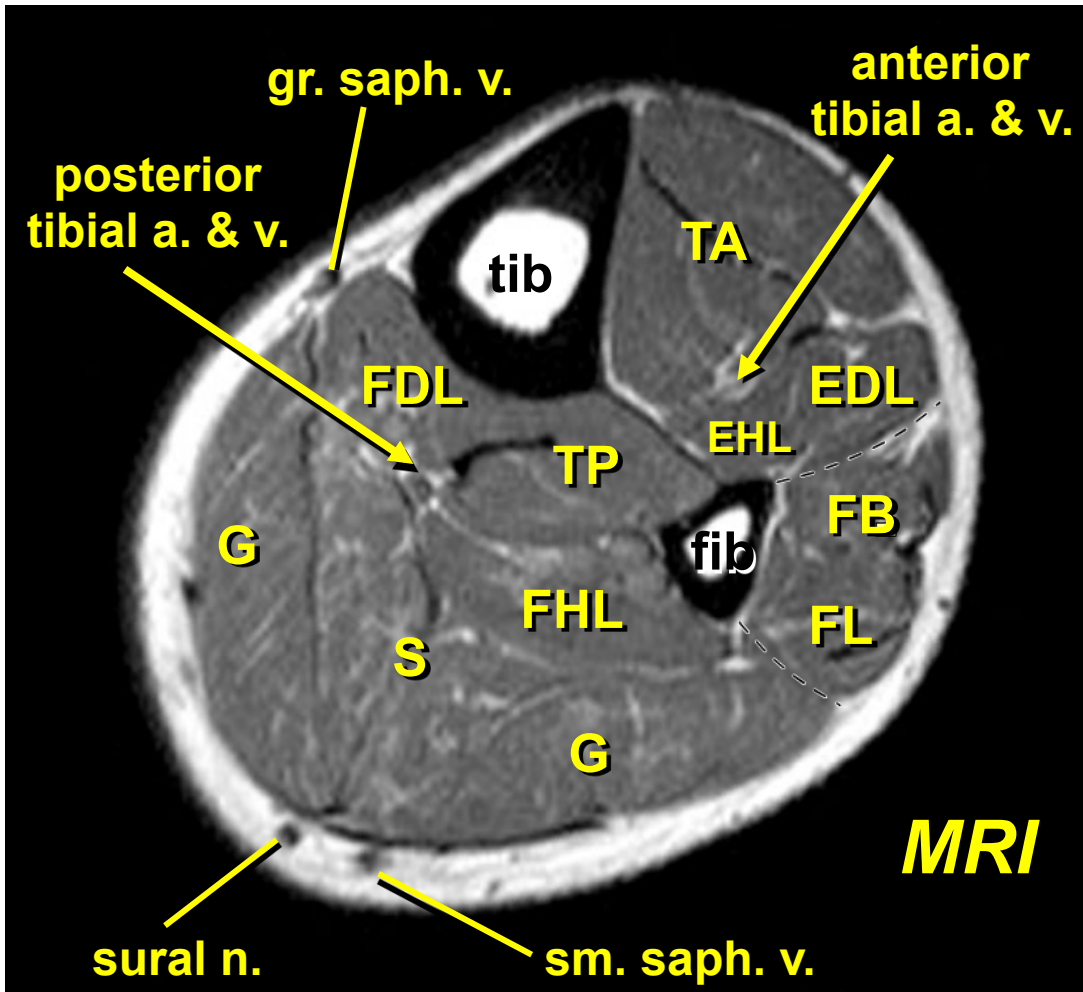
www.familydoctor.co.uk/htdocs/varicose/varicose_specimen.html

Anterior (Tibial) Compartment Syndrome

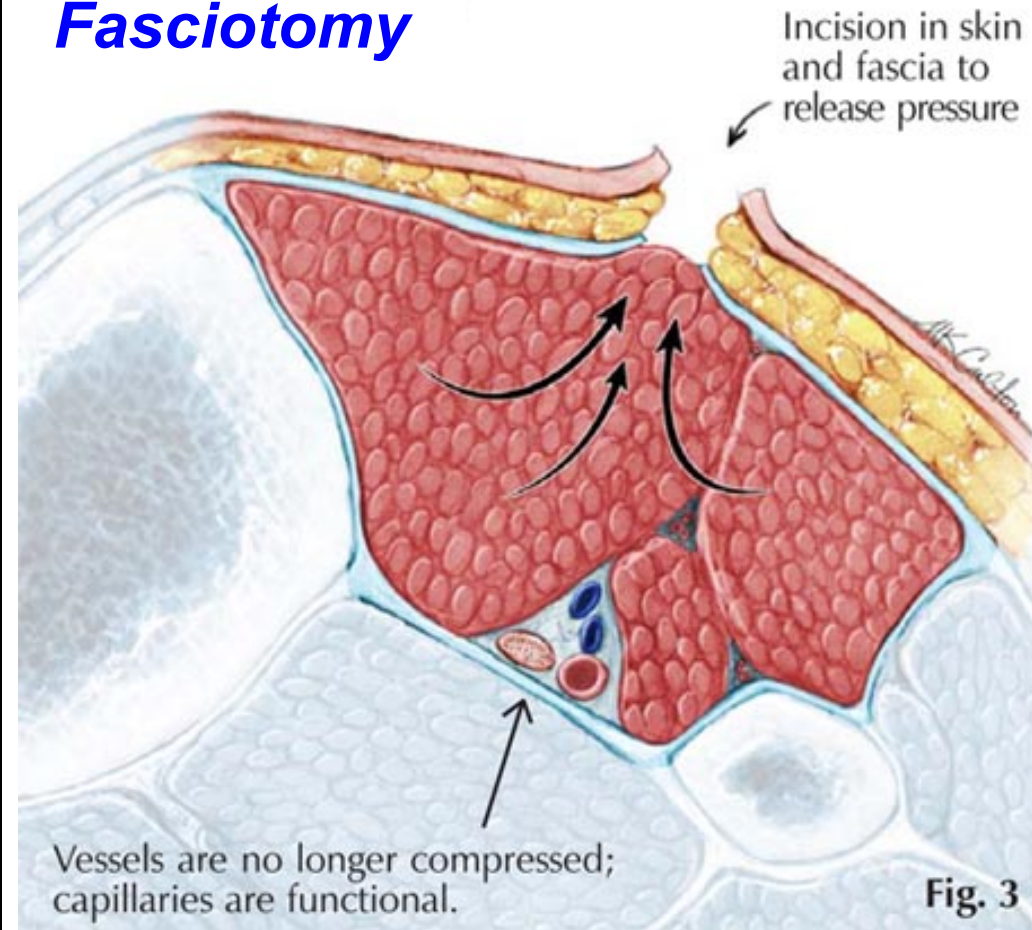
Fig. 1



Anterior (Tibial) Compartment Syndrome



Fasciotomy

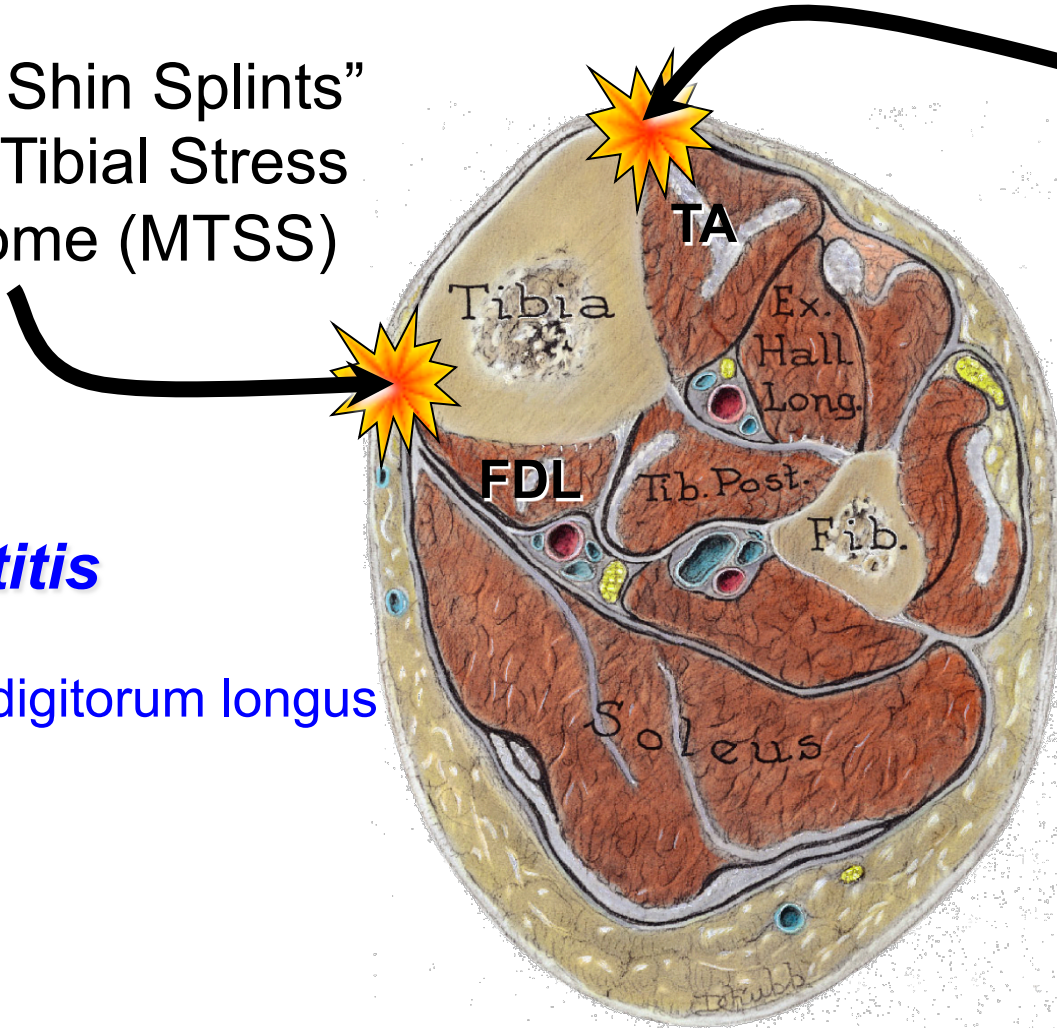


“Shin Splints”: MTSS vs. Tibialis Anterior Strain

“Medial Shin Splints”
Medial Tibial Stress
Syndrome (MTSS)

Periostitis

- Soleus
- Flexor digitorum longus



“Anterior Shin Splints”

- somewhat outdated use of “shin splints”
- probably should be regarded as a variant of anterior compartment syndrome

Lower Limb Pulses

