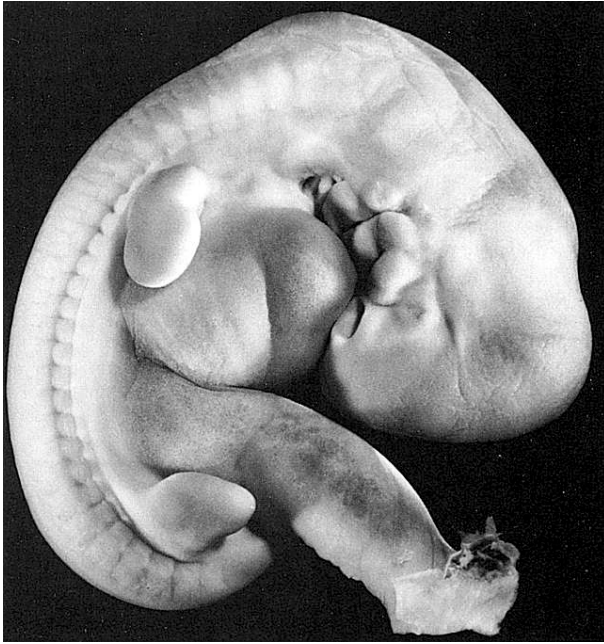

Anatomical Basis of Craniofacial Birth Defects

Handout download:

<http://www.oucom.ohiou.edu/dbms-witmer/peds-rpac.htm>

Lawrence M. Witmer, PhD

Department of Biomedical Sciences

College of Osteopathic Medicine

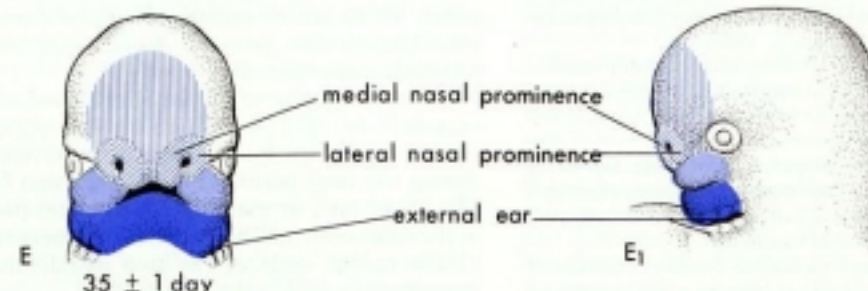
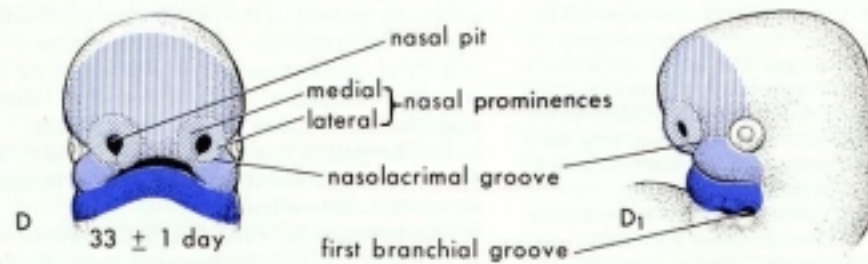
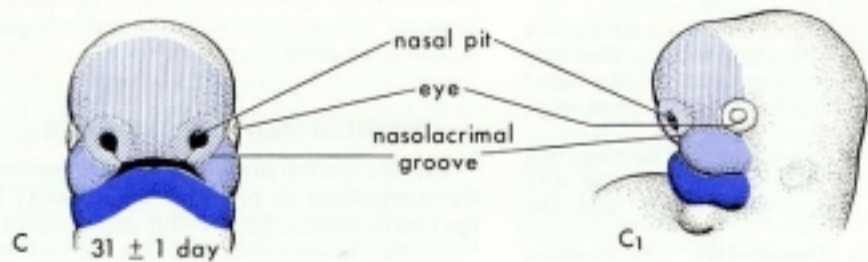
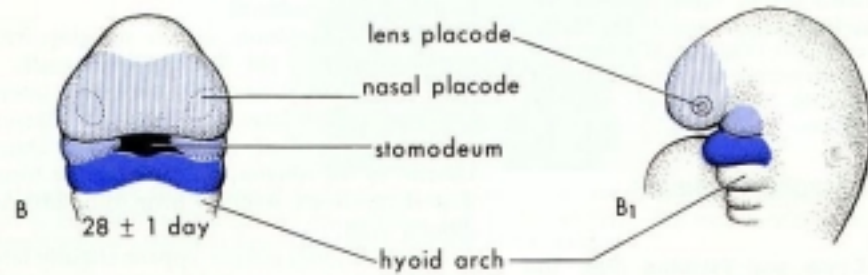

Ohio University

Athens, Ohio 45701

witmer@exchange.oucom.ohiou.edu

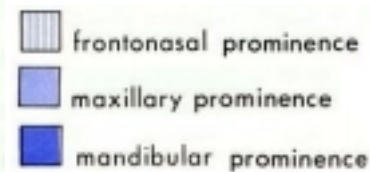


18 October 2000



Development of the Face I

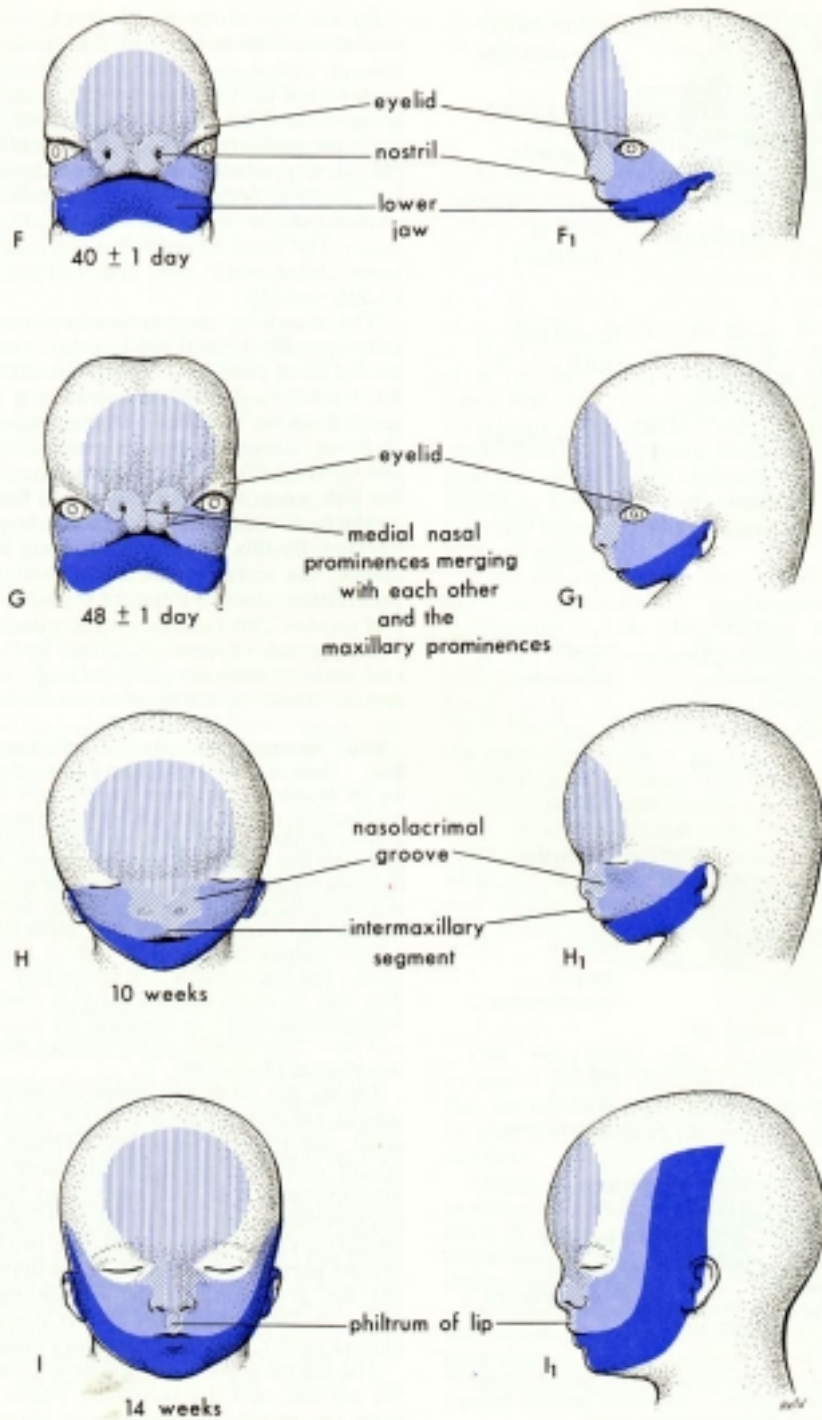
- 5 facial primordia
 - Frontonasal prominence
 - Paired maxillary prominences
 - Paired mandibular prominences
- Surround primordial mouth (stomodeum)
- Neural crest: source for almost all connective tissues in the face
- Frontonasal prominence forms forehead and nose and a short margin of mouth
- Lower jaw and lip form first
- Nasal placodes (and pit): surrounded by medial & lateral nasal prominences
- Nasal pit remains connected to mouth
- Maxillary prominences grow toward each other, pushing nasal prominences medially



From Moore 1982

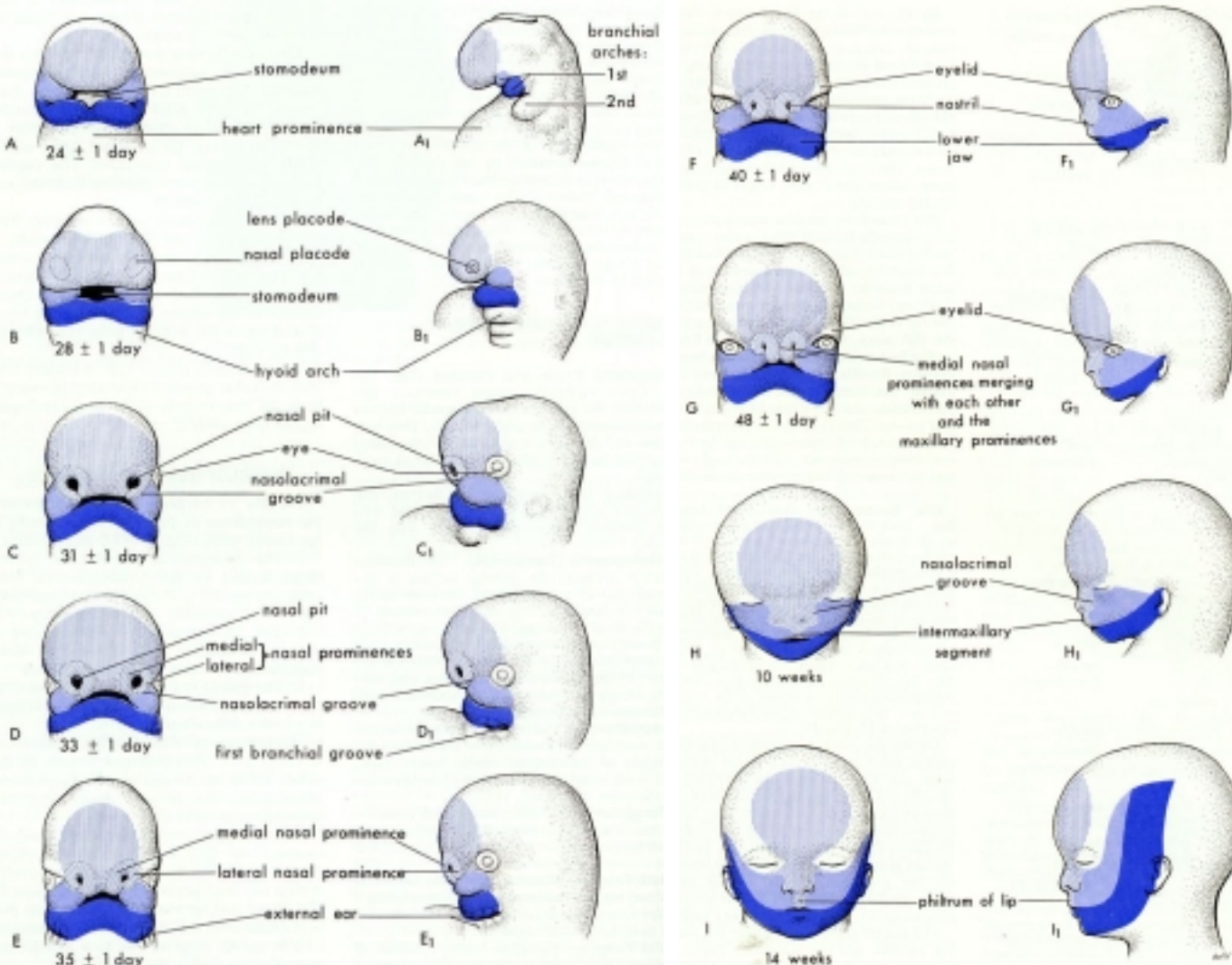
Development of the Face II

- Medial nasal prominences merge with each other and with lateral nasal & maxillary prominences
- Nasolacrimal groove: between lateral nasal and maxillary prominences
 - Becomes nasolacrimal duct
 - Duct forms as solid epithelial cord that later canalizes
- Nasolacrimal duct atresia
 - Failure to completely canalize
 - 6% of newborns
- Intermaxillary segment
 - Merger of medial nasal prominences
 - Gives rise to philtrum, premaxillary bones, primary palate



From Moore 1982

Summary of Facial Development



From Moore 1982

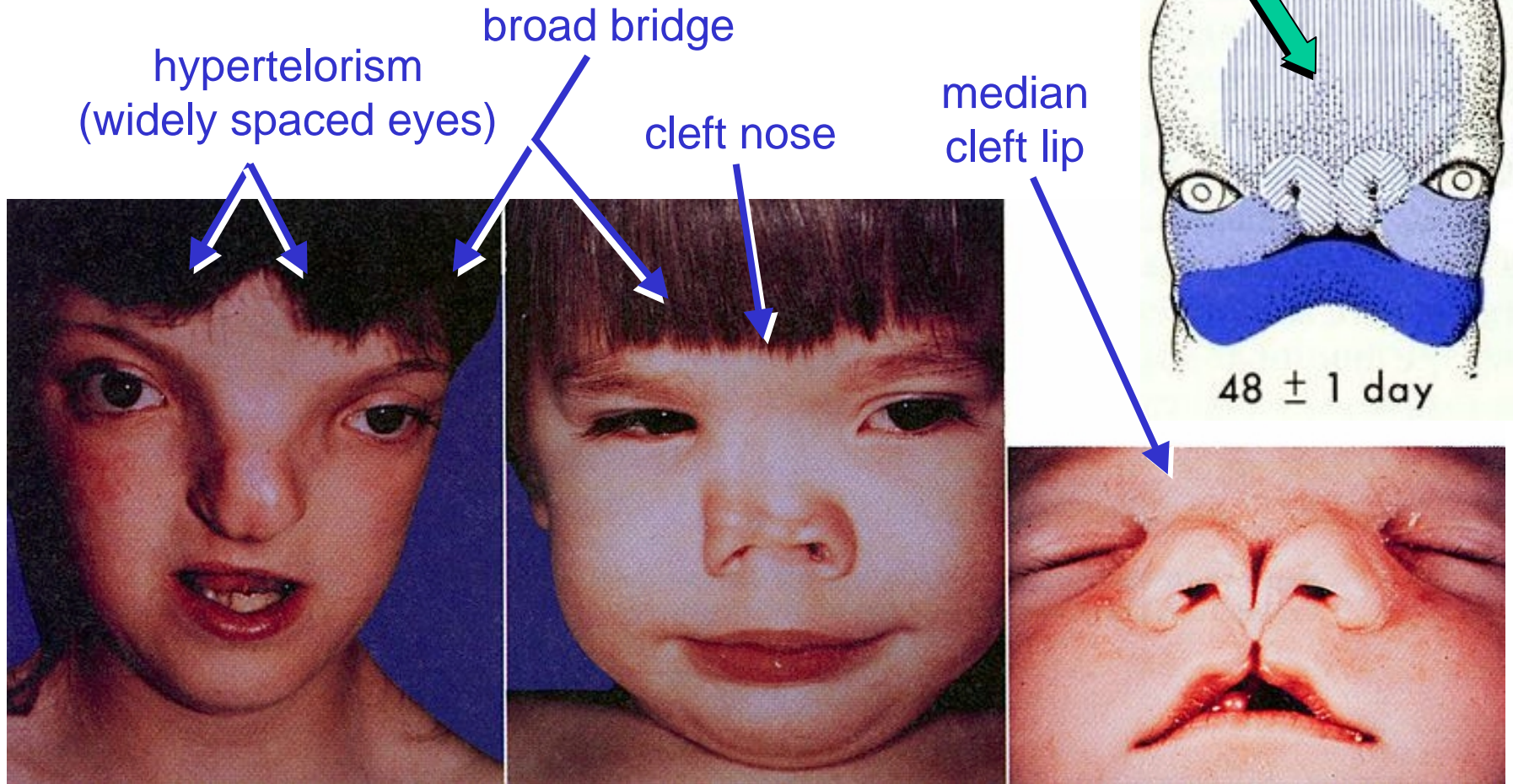
Disruptions in the formation of these prominences leads to facial clefting and other defects.

1. Frontonasal prominence: dorsum & apex of nose
2. Lateral nasal prominence: sides of nose
3. Medial nasal prominence: nasal septum, philtrum, premaxilla, primary palate
4. Maxillary prominence: upper cheek, most of upper jaw and lip
5. Mandibular prominence: lower jaw, chin, lower lip, lower cheek

Defects of the Frontonasal Prominence I

Excess tissue in frontonasal prominence: Frontonasal Dysplasia

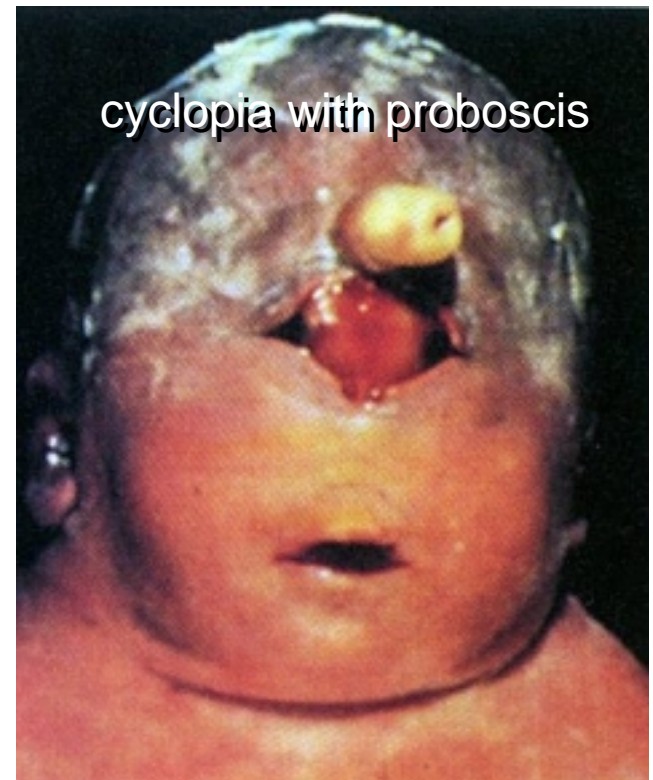
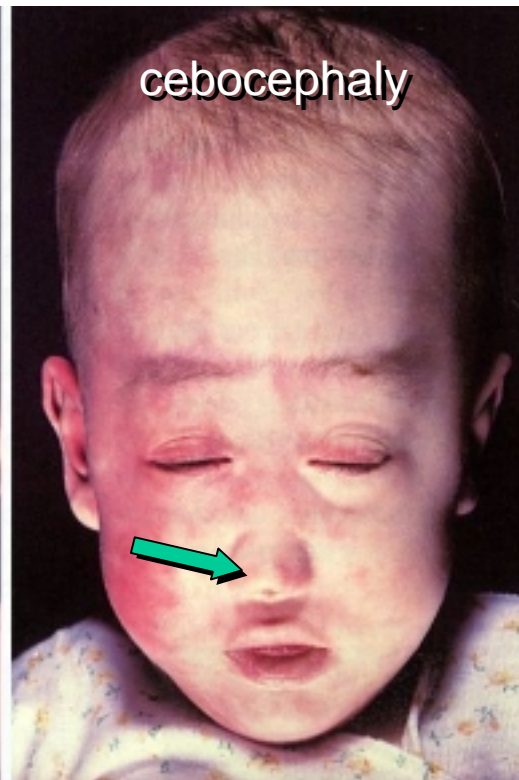
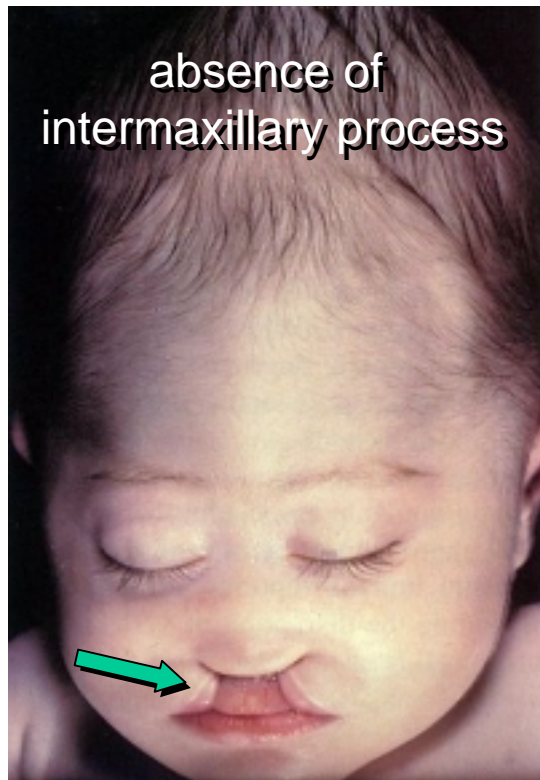
- Broad nasal bridge, hypertelorism, cleft nose, median cleft lip
- Can be associated with other defects (e.g. tetralogy of Fallot in Heart)



Defects of the Frontonasal Prominence II

Deficient tissue in frontonasal prominence: Holoprosencephaly

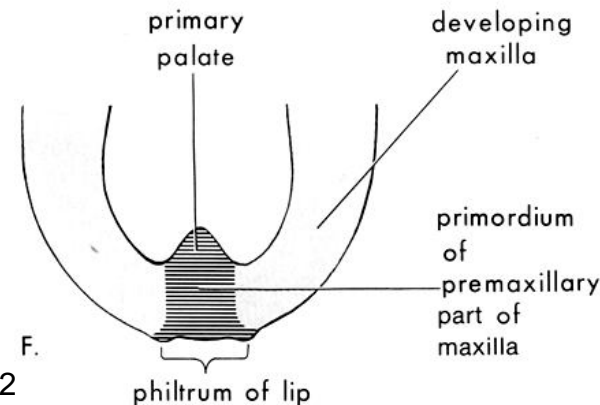
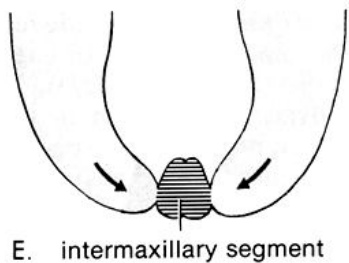
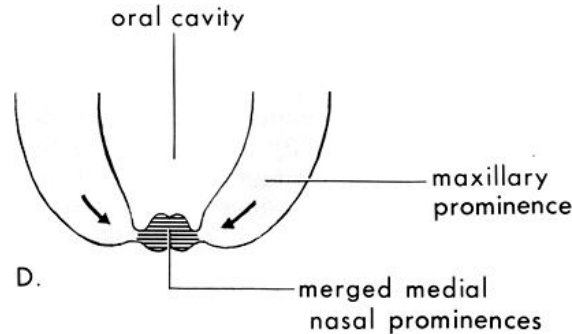
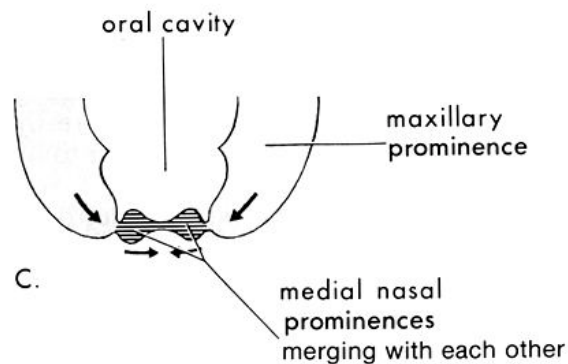
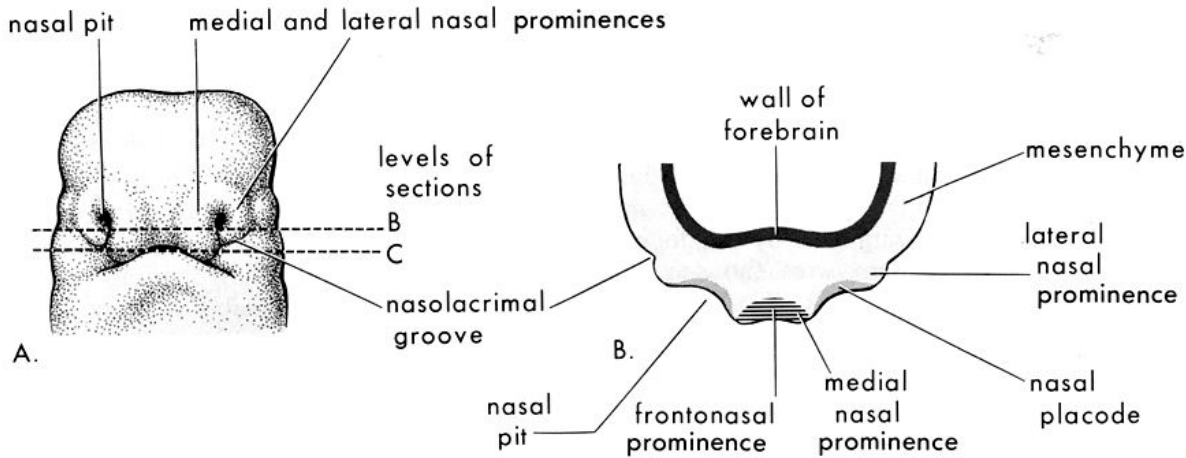
- Defective formation of forebrain (prosencephalon) manifests as midfacial defects
- Caused by: excessive alcohol, genes (sonic hedgehog), excessive retinoic acid
- Wide range of facial defects
 - Mild: short, upturned nose; deficient philtrum; arched palate; microcephaly
 - Extreme: medial nasal prominences, intermaxillary process fail to form; absence of nasal septum & ethmoid bone; single nostril (cebocephaly); hypotelorism or even cyclopia with proboscis



From Larsen 1998

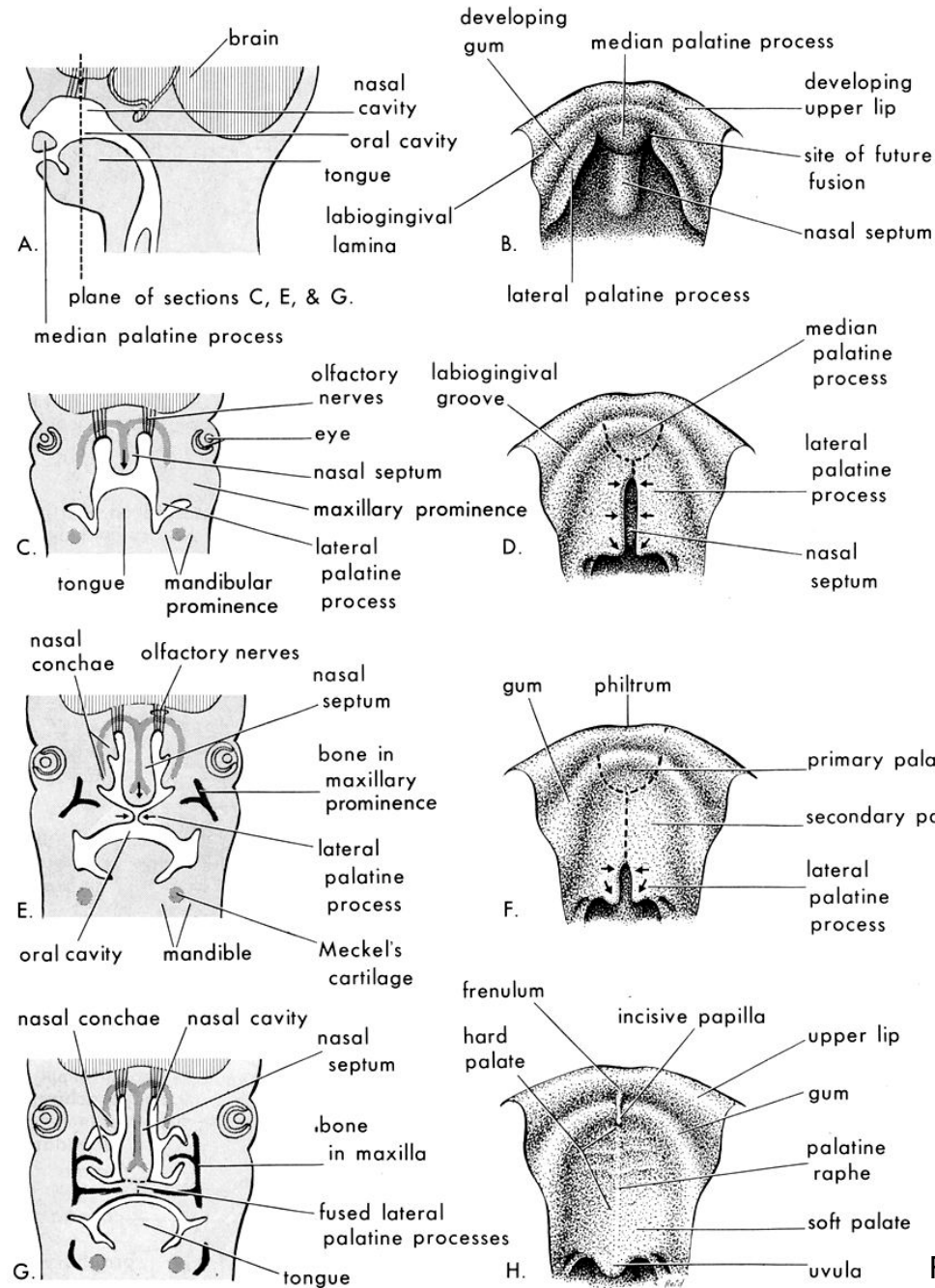
From Moore & Persaud 1998

Development of the Palate: 1. Primary Palate

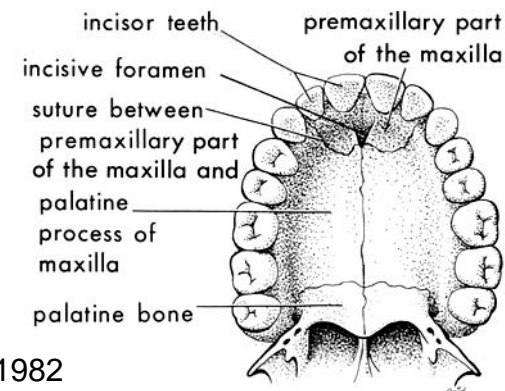


- Palatal development begins in week 5, but weeks 6-9 are most critical
- Formation of intermaxillary segment from merged medial nasal prominences
- Primary palate forms from median palatine process
- Ossifies as the premaxillary portion of the maxilla

Development of the Palate: 2. Secondary Palate



- Lateral palatine processes
 - Ingrowths from maxillary prominences
 - Eventually project horizontally above the tongue
 - Fuse with each other, primary palate, and nasal septum
- Nasal septum
 - Downgrowth of med. nas. promin.
 - Fusion with lateral palatine processes starts anteriorly, then moves back
- Hard palate
 - Primary palate: premaxilla
 - Lateral palatine processes: maxilla
- Soft palate: unossified portion of lateral palatine processes

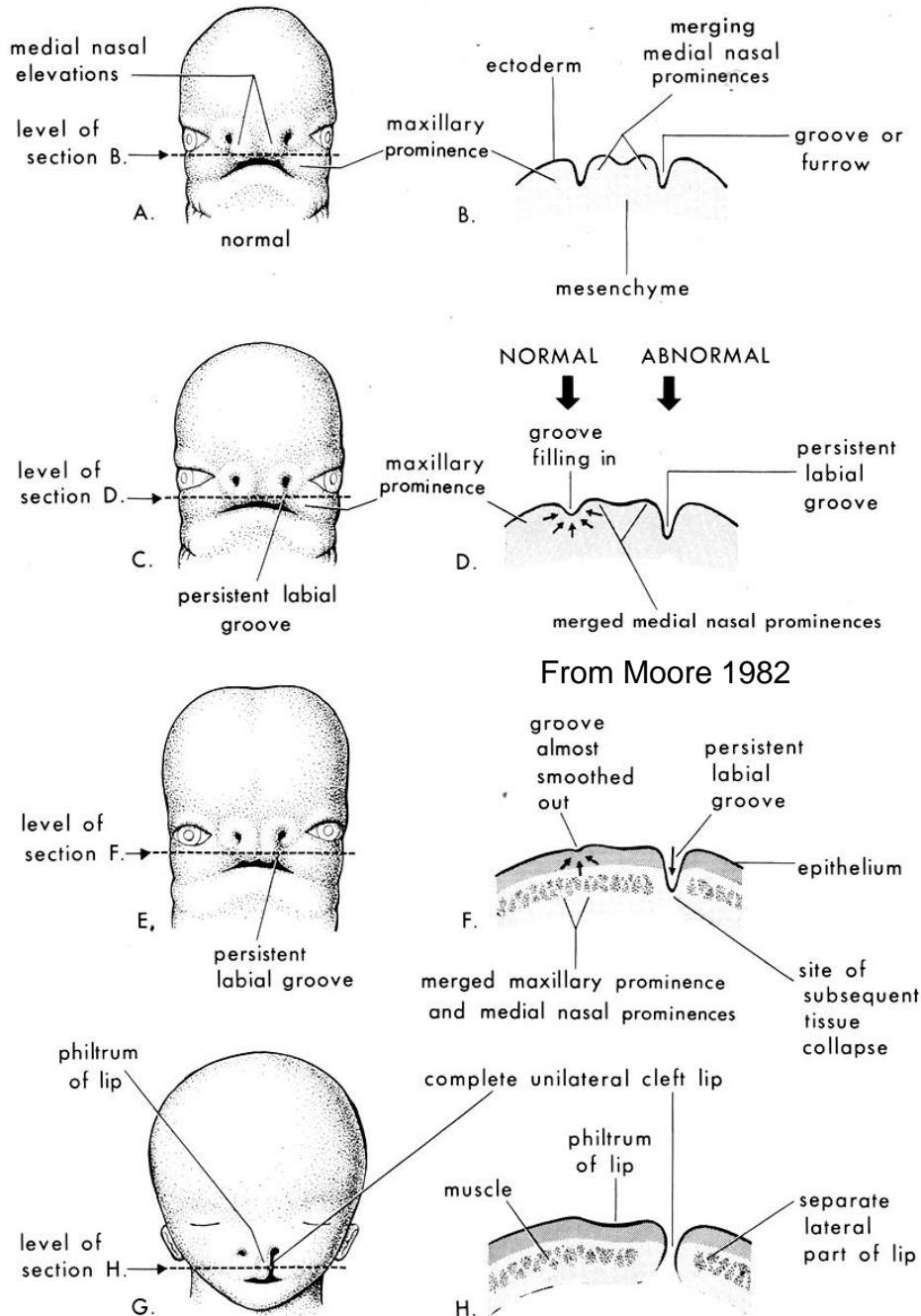


Cleft Lip & Palate I: Unilateral Cleft Lip

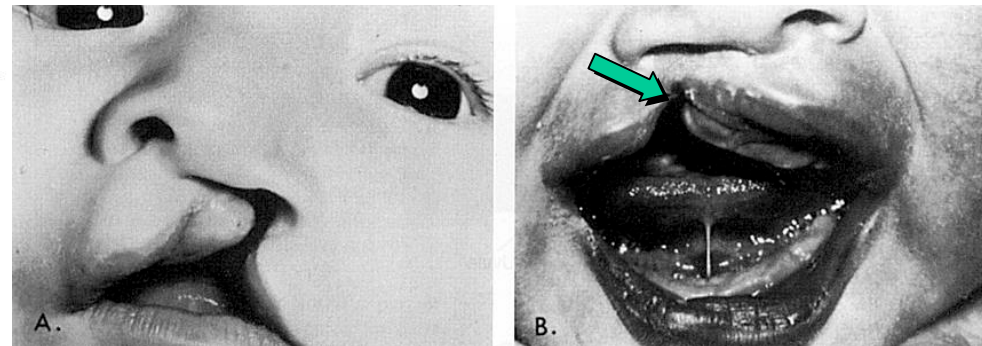
- Cleft lip and cleft palate are related embryologically but are distinct entities
- Cleft lip: 1 in 750; Cleft palate: 1 in 2500
- Effects on appearance, speech, feeding

Unilateral Cleft Lip

- Forms as a persistent labial groove
- Labial groove should disappear as the maxillary prom. fuse with merged medial nasal prominences
- Stretching of epithelium causes tissue breakdown and cleft formation
- Simonart band: bridge of tissue spanning the cleft (arrow below)



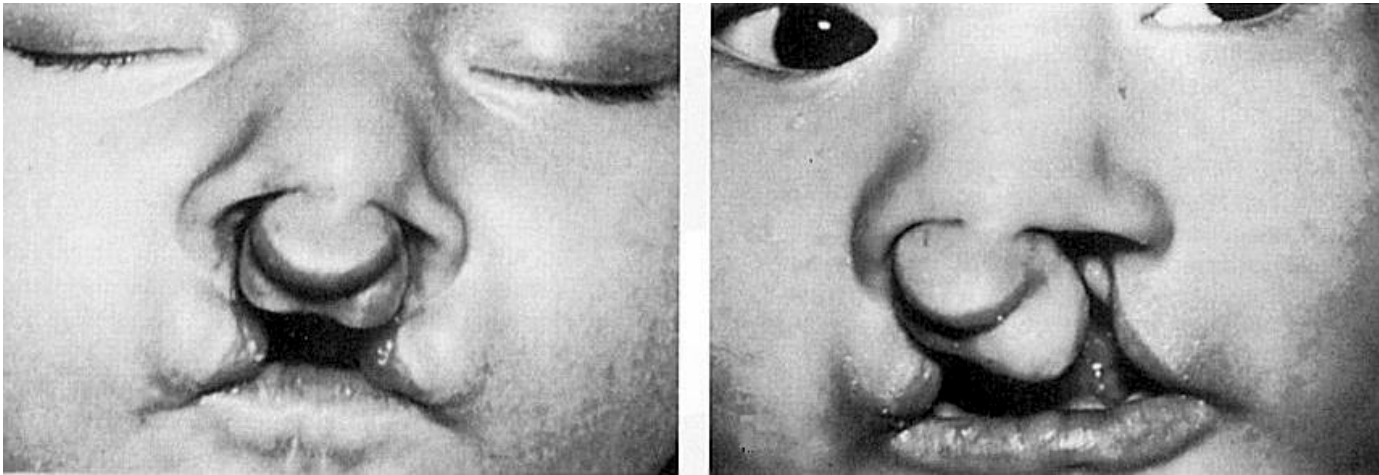
From Moore 1982



From Moore & Persaud 1998

Cleft Lip & Palate II: Bilateral Cleft Lip

- Similar to unilateral cleft lip
- Central soft-tissue mass that moves freely

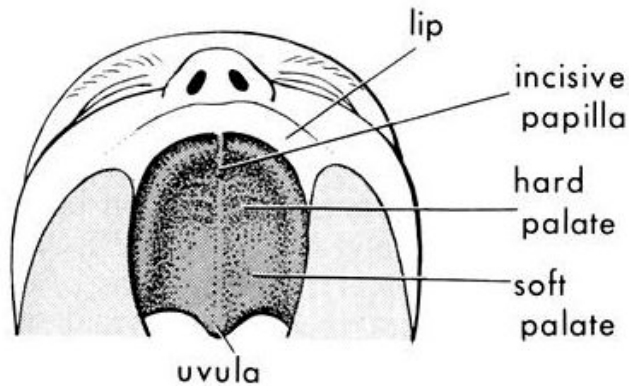


From Moore & Persaud 1998

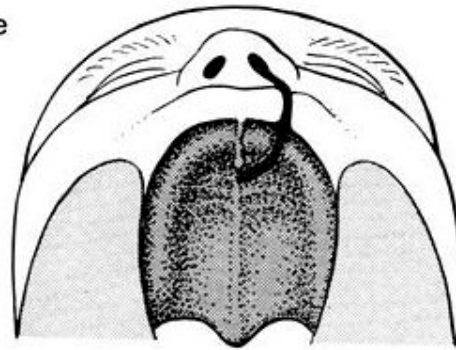
Cleft Lip & Palate III: Anterior Cleft Anomalies

- Clefting of alveolar process of maxilla as well as lip
- Complete cleft extends to incisive foramen
- Complete bilateral anterior cleft isolates the anterior and posterior parts of the palate
- Result from failure of lateral palatine processes to fuse to primary palate

normal



From Moore 1982



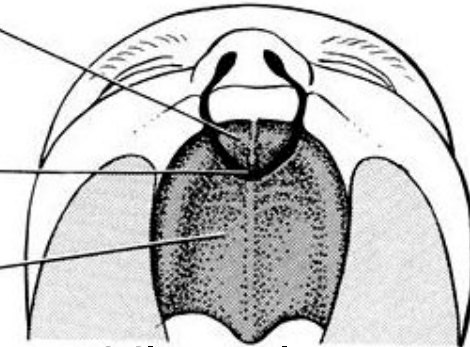
unilateral

primary palate

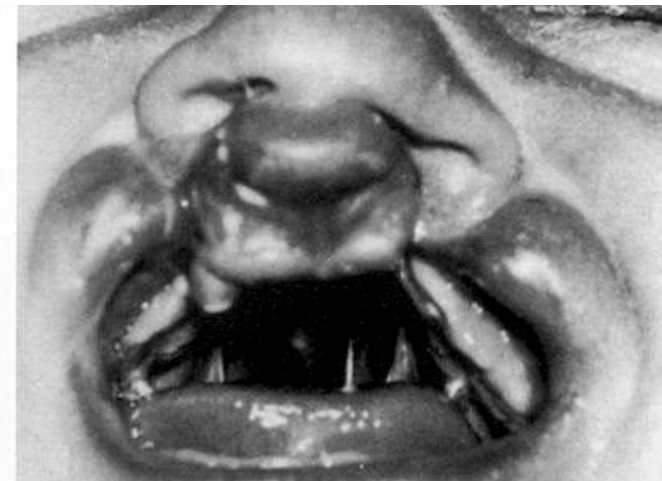
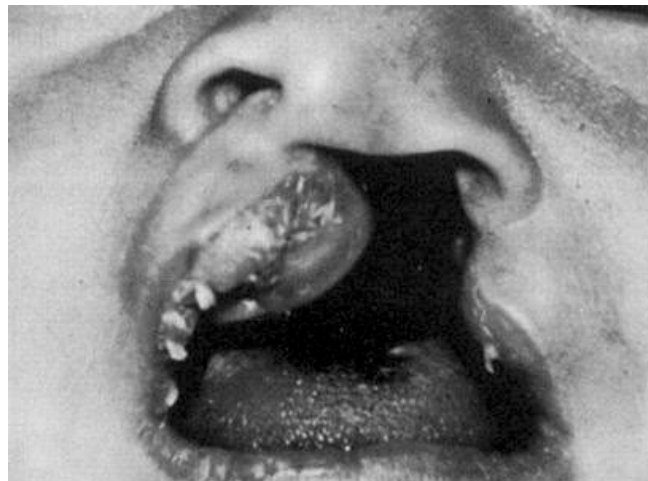site of incisive foramen

secondary palate

F.



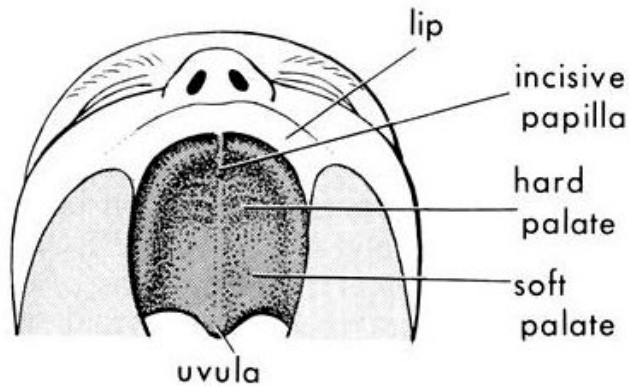
bilateral



From Moore & Persaud 1998


Cleft Lip & Palate IV: Posterior Cleft Anomalies

normal

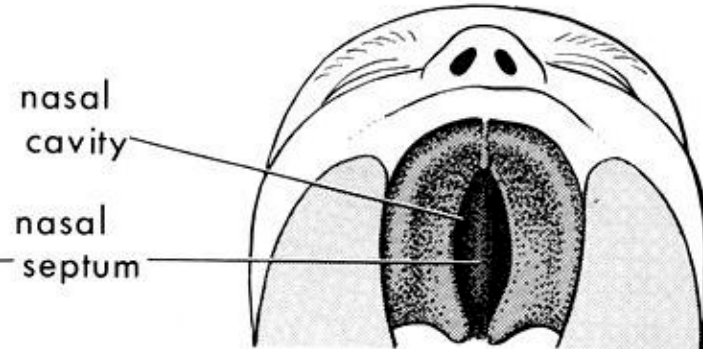


From Moore 1982

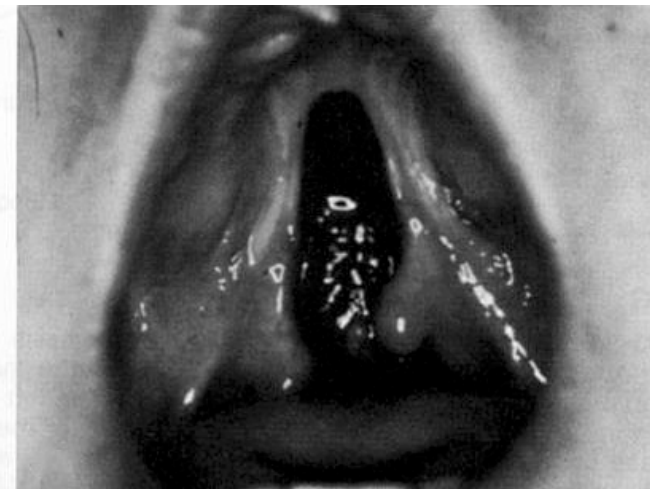
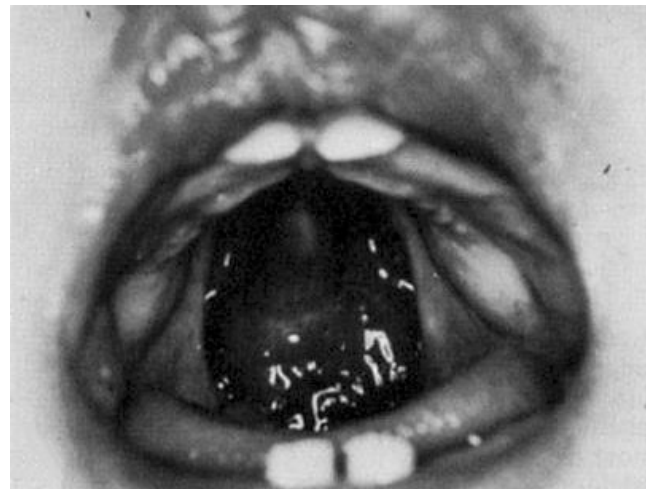
- Clefts extending through both soft and hard (bony) palate to the incisive fossa
- Isolates anterior and posterior parts of palate
- Result from failure of lateral palatine processes to grow medially and fuse to each other



unilateral

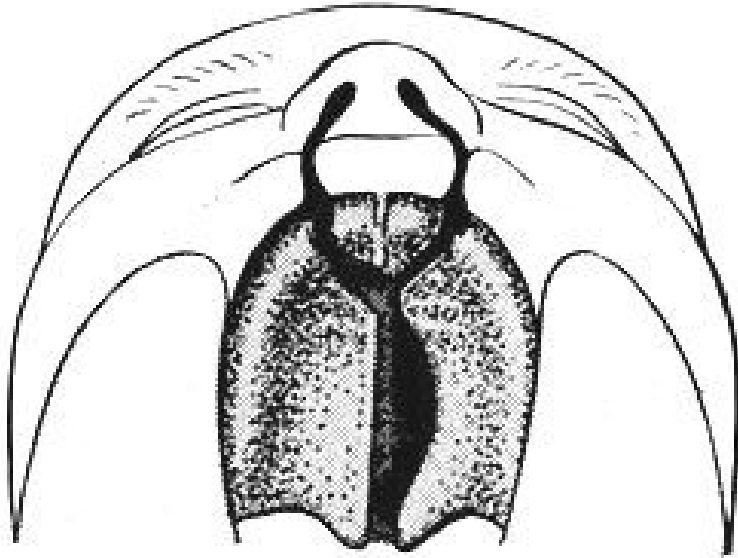


bilateral

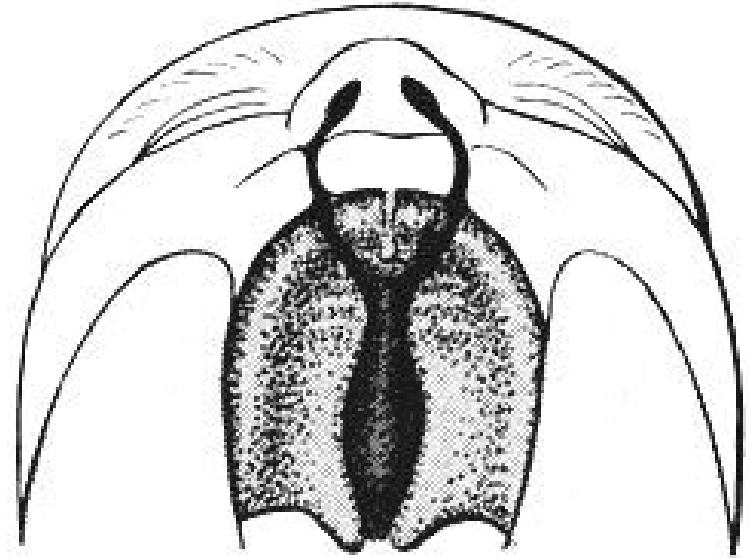


From Moore & Persaud 1998

Cleft Lip & Palate V: Complete Cleft Palate



From Moore 1982



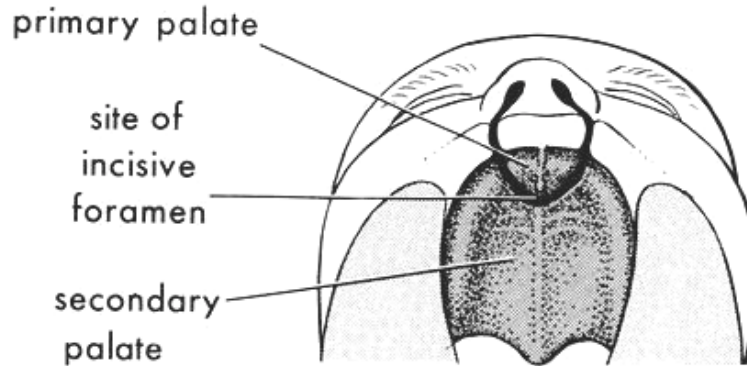
Complete bilateral cleft of the lip and alveolar process of the maxillae with bilateral cleft of the anterior palate and unilateral cleft of the posterior palate

Complete bilateral cleft of the lip and alveolar process of the maxillae with complete bilateral cleft of the anterior and posterior palate

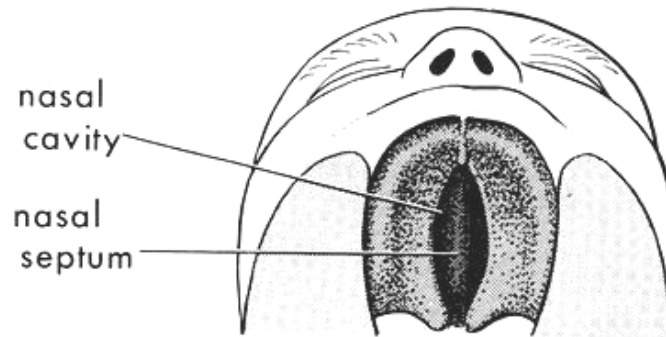
Cleft Lip & Palate VI: Summary I

Type

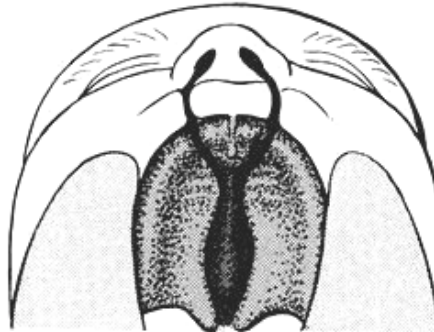
Anterior
Cleft Palate



Posterior
Cleft Palate



Complete
Cleft Palate
(Anterior &
Posterior)



Embryol. Basis

- Lateral palatine processes fail to fuse with primary palate

- Lateral palatine processes fail to fuse with each other and with nasal septum

- Lateral palatine processes fail to fuse with (1) each other, (2) with nasal septum, and (3) with primary palate

Cleft Lip & Palate VII: Summary II

	<u>Mechanism</u>	<u>Underlying Cause</u>
Cleft Lip	<ul style="list-style-type: none">• Hypoplasia in maxillary prom. leading to inadequate contact with medial nasal prom. & intermaxillary segment• Due to (1) inadequate migration of neural crest cells; (2) excessive cell death	<ul style="list-style-type: none">• Multifactorial (genetics, teratogens)• Teratogenic drugs<ul style="list-style-type: none">• Anticonvulsants (dilatant)• Vitamin A• Vitamin analogs: oral anti-acne drug Accutane
Cleft Palate	<ul style="list-style-type: none">• Failure of lateral palatine processes to fuse• Due to: (1) inadequate growth; (2) failure to elevate above tongue; (3) excessively wide head; (4) failure to fuse; (5) secondary rupture after fusing	<ul style="list-style-type: none">• Multifactorial (genetics, teratogens)• Genetics: trisomy 13• Teratogenic drugs: anticonvulsants

- Higher incidence of cleft palate in females: may be due to lateral palatine processes fusing about a week later—prolongs sensitive period

Craniosynostosis

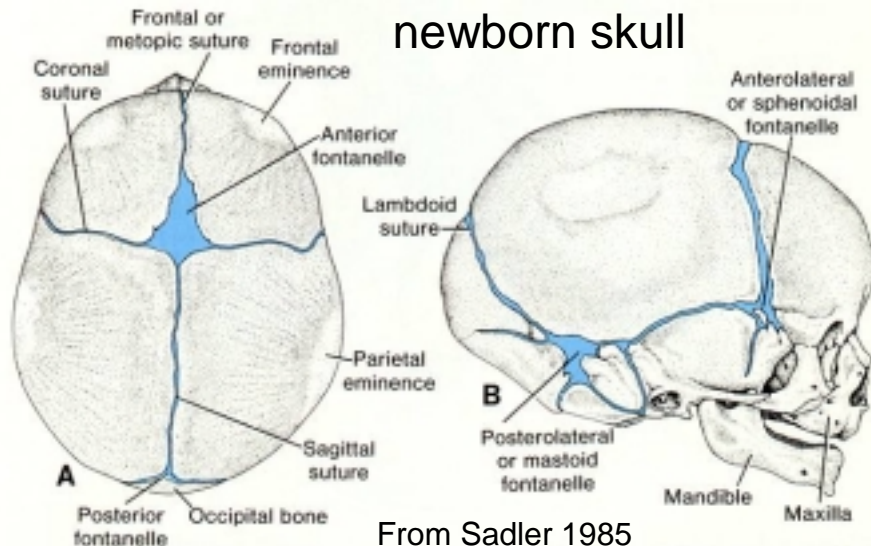
Definition: premature closure of cranial suture

- Primary craniosynostosis: due to abnormalities of skull development
- Secondary craniosynostosis: due to failure of brain growth and expansion—produces microcephaly

For most workers: “craniosynostosis” = “primary craniosynostosis”

Incidence: 1 in 2000-3000; much more common in males

Mechanism: unknown, perhaps cranial base abnormalities cause dural forces that disrupt normal suture development

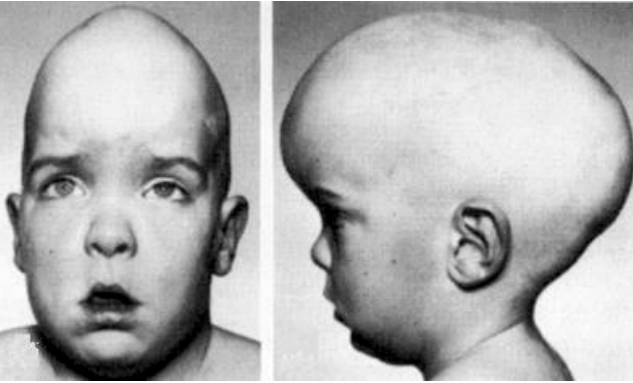


Classified on sutures closed

- sagittal
- coronal
- lambdoid

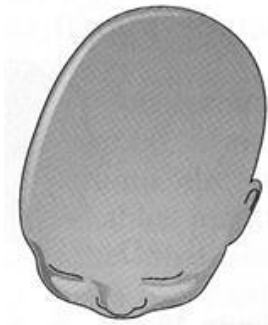
Craniosynostosis

From Moore & Persaud 1998



Scaphocephaly

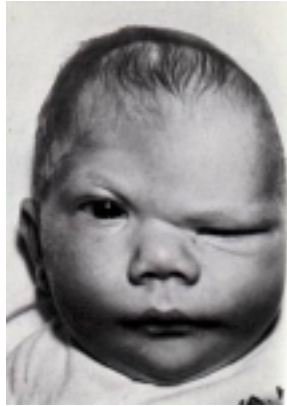- Most common form; more common in males
- Premature closure of sagittal suture



Occipital Plagiocephaly

- More common in immobile children
- Premature closure of lambdoid suture on one side

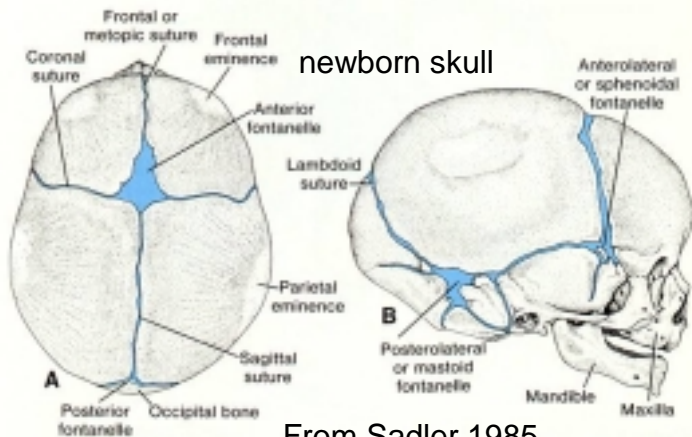
From Sadler 1985



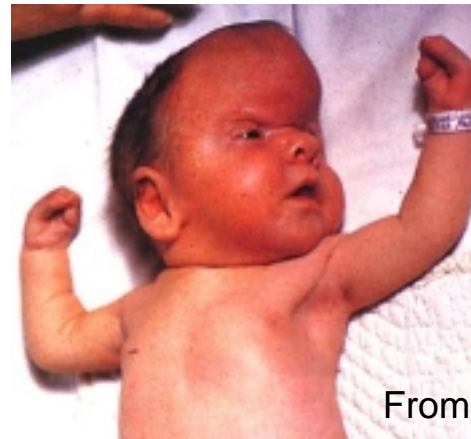Frontal Plagiocephaly

- Next most common; more common in females
- Premature closure of coronal suture on one side

Trigonocephaly: premature closure of metopic suture



From Sadler 1985



Turricephaly

- Premature closure of coronal suture

From Larsen 1998

References

- Carlson, B. M. 1999. *Human Embryology & Developmental Biology, 2nd Ed.* Mosby, New York.
- Larsen, W. J. 1998. *Essentials of Human Embryology.* Churchill Livingstone, New York.
- Moore, K. L. 1982. *The Developing Human, 3rd Ed.* Saunders, Philadelphia.
- Moore, K. L. and T. V. N. Persaud. 1998. *The Developing Human, 6th Ed.* Saunders, Philadelphia.
- Sadler, T. W. 1985. *Langman's Medical Embryology, 5th Ed.* Williams and Wilkins, Baltimore.